



# Staging of Laryngeal Cancer : Clinicoradiological versus Histopathological Findings using Modified Laryngeal Sectioning

<https://doi.org/10.47210/bjohns.2023.v31i2.767>

Shriyash Sinha,<sup>1</sup> Sarmila Sen,<sup>2</sup> Somnath Saha<sup>3</sup>

## ABSTRACT

### Introduction

Laryngeal cancer is commonly encountered in India. Post operative whole organ sectioning of the larynx, although informative, can often be tedious and cumbersome. This study aims to define a modified method of laryngeal sectioning and to assess its level of agreement with pre-operative clinicoradiological findings with regard to T-stage of laryngeal cancer.

### Materials and Methods

Prospective study was conducted on 15 patients diagnosed with laryngeal carcinoma, who underwent total laryngectomy with neck dissection. The pre-operative clinicoradiological T-stage, was compared to the post-operative pathological T-stage, obtained after histopathological examination of sections taken from relevant areas of the total laryngectomy specimen using modified laryngeal sectioning.

### Results

When compared to the pathological staging obtained after modified laryngeal sectioning, clinical T-staging over-staged the tumour in 3 cases and under-staged the tumour in 2 cases, and was similar in the remaining 10 cases. The level of agreement in determining the T-stage was 'fair'.

### Conclusion

The T-stages determined by pre-operative clinicoradiological findings and post-operative histopathological findings after modified laryngeal sectioning, were similar in two-third cases. While whole organ laryngeal sectioning remains the gold standard, it is often a costly and cumbersome process. We propose the use of representative tissue samples from the areas of interest for histopathological examination, obtained by sectioning the larynx at relevant points only, as it saves time and is less resource intensive.

### Keywords

Laryngeal Cancer; Clinical Staging; Radiological Staging; Pathological Staging; T-stage; Modified Laryngeal Sectioning; Whole Organ Section

1 - Department of ENT, Calcutta National Medical College, Kolkata

2 - Department of Pathology, Calcutta National Medical College, Kolkata

3 - Department of Otorhinolaryngology, Calcutta National Medical College, Kolkata

### Corresponding author:

Dr Shriyash Sinha

email : shriyash.sinha@gmail.com

The larynx is one of the most important organs in the upper aerodigestive tract. It performs crucial functions of airway protection and respiration, serves as the voice box, and assists with swallowing. Cancer of the larynx is a commonly encountered entity in India. Laryngeal carcinoma is the seventh and ninth most common cause of cancer in males in India and Asia respectively.<sup>1</sup>

A good preoperative assessment and proper

clinoradiological staging, helps in formulating the relevant management plan. Staging also reflects on the eventual outcome of laryngeal carcinoma. Imprecise tumour staging from pretreatment imaging could possibly preclude organ preservation in many patients. Further, penetration of the laryngeal cartilage and/or extralaryngeal tumour spread is associated with a lower response rate to radiation therapy and a higher risk of tumour recurrence.<sup>2,3</sup> These facts illustrate the importance of accurate preoperative evaluation in patients of laryngeal carcinoma.

Whole organ sections of the larynx have been used since several years to increase our knowledge of the histopathological and biological behaviour of laryngeal carcinoma. It is especially useful to understand the spread of laryngeal carcinoma through tissue planes. The first serial laryngeal sections were done by LeRoux-Robert in 1936 and were used to examine laryngeal carcinoma after autopsy.<sup>4</sup> Kirchner published an article highlighting the contributions of whole organ sections of the larynx to the treatment of laryngeal cancer. He concluded that whole organ serial sections of larynx have provided graphic evidence of the patterns of cancer spreads from one part of the larynx and hypopharynx to the other, and have demonstrated the fibroelastic ligaments and membranes which form the boundaries of intralaryngeal compartments within which cancer is confined in its early stages, and thereby added support to the concept of partial laryngectomy for selected lesions.<sup>5</sup>

Whole organ sections of laryngectomy specimens have undoubtedly facilitated better interpretation of preoperative imaging, while providing additional help with staging of laryngeal cancers. However, the process of whole organ sectioning of the human larynx is a cumbersome one, involving serial sections which are 1-2 mm thick, either in the coronal or the axial plane. These sections have to traverse through varying levels of tissue density, ranging from soft tissue, ligaments, muscles to relatively harder cartilage and bone. Further, problems with grossing and tissue processing of whole organ sections make it difficult to quickly analyse them. We therefore suggest a modification, where tissue specimen is collected by sectioning at the relevant points of interest,

with respect to the staging of laryngeal cancer. These points of interest are accessed by laryngeal sectioning done at specific levels, instead of taking 1-2 mm cuts of the whole organ laryngeal specimen. The T-stage determined by the histopathological examination of specimen obtained after modified laryngeal sectioning was compared to the T-stage determined pre-operatively by clinoradiological examination.

The aim of this study was to define a modified method of laryngeal sectioning and to assess its level of agreement with pre-operative clinoradiological findings with regard to T-stage of laryngeal cancer. The reasons for incompatibility between the two were listed.

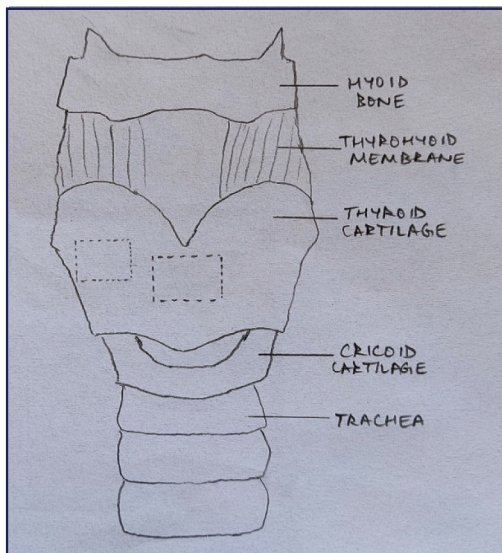
### Materials and Methods

This prospective observational study was conducted at the Departments of Otorhinolaryngology and Pathology, at a tertiary care hospital in West Bengal, between February 2020 to July 2021. 15 biopsy proven laryngeal cancer patients, with advanced and extensive disease (T3 and T4), previously unoperated, and now warranting and consenting for total laryngectomy, were included. Patients with T1 or T2 laryngeal cancer, who did not have a need for total laryngectomy, and for whom radiation and/or chemotherapy, or other less radical surgery would suffice, were excluded. Patients who had been operated previously or had received radiation in the past were also excluded.

Patients coming to OPD with laryngeal carcinoma were assessed clinically. The patients underwent detailed clinical examination, fiberoptic laryngoscopy (FOL), contrast enhanced CT base of skull to clavicle with special emphasis on the larynx and neck nodes. After the relevant work-up, clinical staging was done by amalgamating the clinical findings with the radiological reports.

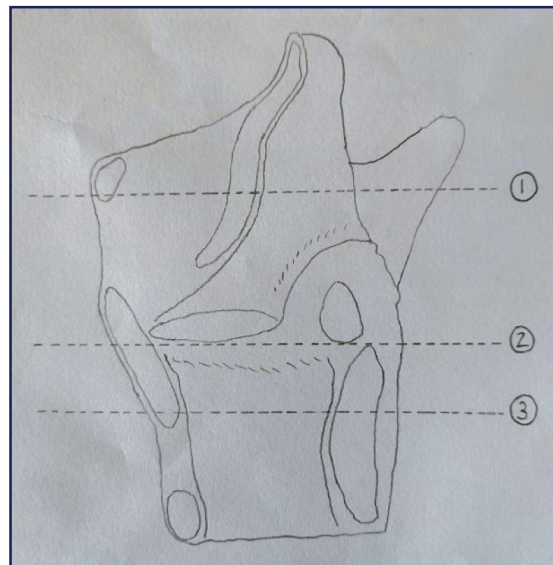
The patients with T3 and T4a stage, and qualifying the inclusion criteria, underwent total laryngectomy and neck dissection. The total laryngectomy specimen was stored in formalin and transported to the Pathology Department. The laryngectomy specimen was sliced open from its posterior aspect from top to bottom to be able to visualize the inner structures.

Two windows were made in the thyroid cartilage as shown in Fig.1. The first window was created in the midline and another window was created laterally on the same side as the lesion, as observed grossly and on corroboration with radiological imaging. The specimen spanning the entire thyroid lamina was thus collected and then sectioned in a coronal plane so to get clear sections from the both the inner and outer cortex of the thyroid cartilage. The exact site of these windows can vary from case to case. The anterior midline window can be created at the level of the cancerous growth, once it has been properly visualized and the lateral window can be created ipsilateral to the side of involvement of the larynx. Making a window in the midline of the thyroid cartilage is especially important, since the weak spot of the laryngeal framework is the anterior midline, with respect to early cartilage invasion of the tumour and its exo-laryngeal spread. The creation of the two thyroid windows aid in obtaining specimens of the thyroid cartilage, which are then analysed using thin coronal sections for determining involvement of inner and outer cortex of thyroid, which have a bearing on the staging.



**Fig. 1. Two windows being created in the thyroid cartilage. First window is located in the anterior midline grossly corresponding to the level of the cancerous lesion, and the second window is created laterally on the involved side of the larynx.**

Instead of serial whole organ sectioning of the larynx at 1-2 mm thickness, representative tissue specimens were collected from the relevant sites which impact the staging of laryngeal cancer, after accessing them with the aid of the three planes through which transverse whole organ sectioning was done as showed in Fig.2.

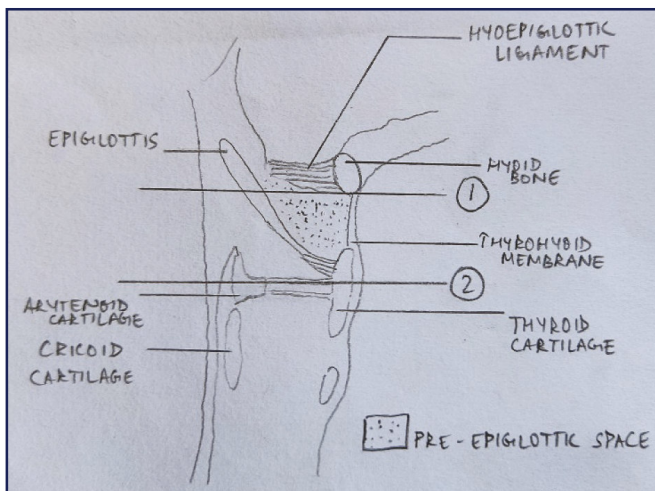


**Fig. 2. Three planes through which transverse whole organ sections are made.**

The first whole organ section was made at the horizontal plane passing just inferior to the hyoid bone and intersecting the epiglottis. The second whole organ section was made in a transverse plane at the level of the anterior commissure, inferior to the thyro-epiglottic ligament, and the third whole organ section was done at the horizontal plane passing 2 mm inferior to the glottis, ie, 12 mm below the inferior surface of true vocal cord. The whole organ sectioning allowed us access to the areas of interest, thereby enabling better tissue sectioning from these areas. Further sections were taken from the relevant areas as per need of the specific case.

After taking the first and second whole organ sections, the entire pre-epiglottic space was exposed as shown in Fig. 3. Adequate tissue sectioning was then done from the pre-epiglottic space, with the aid of 2 mm axial sections spanning from the first whole organ section and extending upto the second whole organ section. This

allowed us to obtain representative tissue specimen from the entire pre-epiglottic space.



**Fig. 3. Pre-epiglottic space exposed after giving first and second transverse whole organ sections.**

The second section allowed us to access to the paraglottic space at the level of the glottis. The third whole organ section also allowed access to the paraglottic space, in addition to the post-cricoid area and cricoid cartilage. After having sliced open the whole organ laryngeal specimen from top to bottom in its posterior aspect, and with the aid of aforementioned three transverse whole organ sections, we obtain easy access to the paraglottic space on both sides. The paraglottic space is laterally bounded by the thyroid cartilage, through which representative specimens were already collected. Serial 2 mm thick sectioning is done between the second and third transverse whole organ sections in between the two thyroid laminae, which enables histopathological evaluation of the paraglottic space, post-cricoid area and the cricoid cartilage. Involvement of all these structures have repercussions on the T-stage.

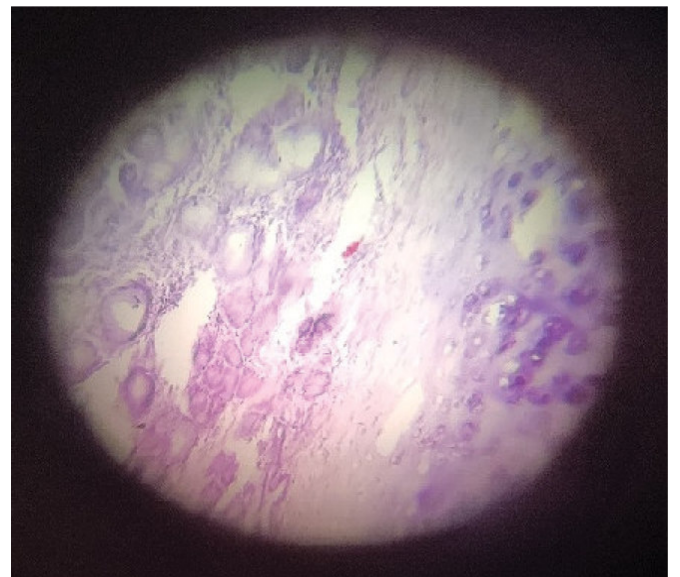
Slicing open the whole organ laryngeal specimen posteriorly, and the subsequent transverse whole organ sections, enabled easy access to the areas of interest that have relevance in determination of T-stage. Further, 2 mm thick sections made between the transverse whole organ sections need not span the entire transverse length of the organ and can be made separately for the right

and left side. This helps in obtaining postage-stamp sized tissue specimens which are easy to handle and study, in stark contrast with the much larger whole organ transverse sections.

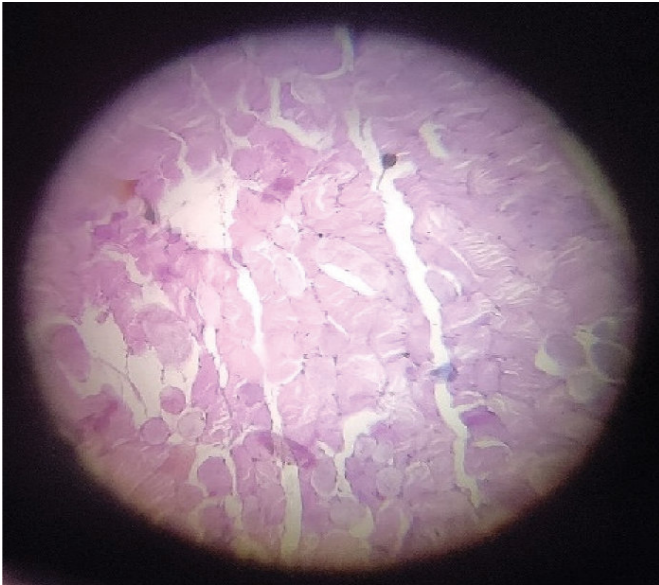
Sections were then collected from the thyroid gland, and inferiorly from the trachea. Adequate tissue sectioning was done from the growth proper, after measuring and mapping out its extension. Level 2-4 lymph nodes were analysed histopathologically.

Sections were thus collected from the following sites- pre-epiglottic space, paraglottic space, postcricoid area, inner and outer cortex of thyroid, cricoid cartilage, supraglottis, glottis, subglottis, the growth proper, trachea, cervical soft tissue, strap muscles, thyroid and lymph nodes.

The grossing was done, and the specimens were properly labeled and stored in tissue cassettes, before being processed. The histopathological examination was done by a single senior pathologist. The clinical staging was compared with the pathological staging and discordance, if any, was noted.



**Fig. 4. Histopathological section through the outer cortex of the thyroid cartilage. The section shows hyaline cartilage and benign mucous glands. The cartilage is found to be free from carcinoma. (H&E, 100X)**



**Fig. 5. Histopathological section showing striated muscle fibres of the strap muscles, which are free from the carcinoma. (H&E, 100X)**

## Results

Patients aged from 52 to 69 years (mean, 61 years). There were fourteen (93.3%) male patients and one (6.7%) female patient. The site of primary malignancy was the glottis in 10 out of 15 patients. 4 patients had a supraglottic carcinoma while 1 patient had a subglottic malignancy. All fifteen patients had squamous cell carcinoma larynx, with varying differentiation.

Compared to the pathological T-stage, clinical T-staging over-staged the tumour in 3 cases and under-staged the tumour in 2 cases, and was found to be similar in the remaining 10 cases. Kappa weighted statistic was used to find out the agreement between the clinical and pathological T-stage, and it showed 'fair agreement' between the two.

## Discussion

Between 1964 and 1979, the clinical staging was found to be inaccurate in 40 % of the laryngeal specimens studied by whole organ section.<sup>6</sup> The inaccuracy was nearly always in the form of underestimation, commonly

due to invasion of the laryngeal framework or because of undetected spread of the cancer into the pre-epiglottic space. Since then, the whole organ sectioning has come a long way and in its current state, is being extensively used for staging and understanding tumour biology and patterns of spread. Kiminori Sato in his chapter on whole organ serial sections of the adult human larynx has graphically depicted the various sites through schematic diagrams and histopathological slides.<sup>7</sup> It provides a great understanding of the anatomical relations and possible routes of cancer spread.

The whole organ sectioning of larynx, albeit useful for studying the laryngeal cancer spread, can be a tedious and cumbersome process. Even though the value of serial sectioning of the larynx is generally recognized, the process remains laborious and resource intensive, and requires a financial investment and time commitment. In the present study, we have taken tissue specimens from the anatomical sites and areas where the laryngeal cancer is likely to spread, and which have a bearing on the staging of laryngeal carcinoma. These tissues have been accessed through three transverse whole organ sections done at the horizontal levels passing through the plane inferior to hyoid bone, through the anterior commissure and through a horizontal plane passing 2 mm below the glottis. These sections make the areas of interest more accessible, thereby enabling direct tissue sectioning from there. The whole organ sections through the larynx are large and require special processing and larger slides to enable studying them in their entirety. Instead, we propose using representative samples from areas of interest, the access to which is enabled through the aforementioned whole organ sections. The representative tissue thus collected is from a small area of interest and can be easily mounted on a slide and is roughly the size of a postage stamp, thereby rendering it easier to handle and study under the microscope. This method circumvents the complications and tediousness of whole organ sectioning, while retaining the benefit of histopathological examination to appreciate tumour involvement across tissue planes.

In addition to the transverse whole organ sections, we propose making square windows in the thyroid

**Table I: Comparison of clinicoradiological and histopathological T-stage**

		CLINICORADIOLOGICAL STAGING : T				TOTAL	KAPPA WEIGHTED STATISTIC	INTER- PRETATION
		T1	T2	T3	T4A		Ê W	
HISTOPATHOLOGICAL STAGING AFTER MODIFIED LARYNGEAL SECTIONING : T	T1	0(0)	0(0)	0(0)	0(0)	0(0)	0.400	Fair agreement
	T2	0(0)	0(0)	2(18.18)	0(0)	2(13.33)		
	T3	0(0)	0(0)	7(63.64)	1(25)	8(53.33)		
	T4a	0(0)	0(0)	2(18.18)	3(75)	5(33.34)		
Total		0(0)	0(0)	11(100)	4(100)	15(100)		

**Table II: Discordance in T-Stage: Reasons for overstaging and understaging**

PRIMARY SITE	cT	pT	REASON FOR OVERSTAGING
Glottic	T3	T2	Paraglottic space was thought to be involved on radiology, but was found not to be involved on histopathology
Supraglottic	T3	T2	Pre-epiglottic tissue was involved on radiology, but spared on histopathology
Glottic	T4a	T3	Outer cortex of thyroid cartilage invaded by tumour on radiology, but found to be spared on pathological analysis

PRIMARY SITE	cT	pT	REASON FOR UNDERSTAGING
Supraglottic	T3	T4a	Outer cortex of thyroid cartilage spared by the tumour on radiology, but found to be involved on pathology
Glottic	T3	T4a	

cartilage. The first window is made in the midline, grossly corresponding to the level of the cancerous growth. The second window is made laterally, ipsilateral to the site of the cancerous involvement. The thyroid cartilage removed through these windows can then be used for coronal sectioning so as to enable us to pathologically assess the involvement of both inner and outer cortices of thyroid cartilage. The midline window is extremely important. It is known that the weakest point of the laryngeal structure is the midline because of the absence of perichondrial tissue at this site, thereby rendering it susceptible to invasion of cartilage by the cancer.<sup>8</sup>

We have compared the T-stage obtained by histopathological examination following modified laryngeal sectioning to the clinicoradiological T-stage and found the T-stage to be similar in 66.67% cases. While whole organ laryngeal sectioning remains the gold standard, with the advent of better imaging techniques, the accuracy of clinicoradiological staging and its ability to ascertain pathways of tumour spread has been on the rise. The accuracy of pre-operative T-staging of laryngeal cancers, as ascertained by various studies by comparing it with histopathological examination following conventional whole organ sectioning is given in Table III.

**Table III : Comparison of accuracy of pre-operative T-staging –  
Clinicoradiological vs Histopathological examination following conventional whole organ sectioning**

STUDY	YEAR	NUMBER OF CASES	ACCURACY OF CT SCAN IN PREDICTING T-STAGE
Agada et al <sup>9</sup>	2004	38	45%
Wolny et al <sup>10</sup>	2006	100	62%
Allegra et al <sup>11</sup>	2014	20	70%
Ryu et al <sup>12</sup>	2014	94	78%
Atlanođlu et al <sup>13</sup>	2016	28	82.1%
Èelakovský et al <sup>14</sup>	2017	124	87.9%
Jaipuria et al <sup>15</sup>	2018	23	82.6%
El-Sharkawy et al <sup>16</sup>	2019	30	76.6%
Contrera et al <sup>17</sup>	2020	265	82%

In our study, of the 5 cases where there was an inaccuracy in the T-stage, 3 (60%) cases were due to incorrect prediction of cartilage involvement. Similar inaccuracies in evaluating cartilage involvement by tumours have been reported from other studies. The role of computed tomography in detection of cartilage involvement in early glottic tumours was studied by Hartl et al.<sup>18</sup> The authors concluded that CT imaging was

unable to evaluate focally invaded lesions in the inner cortex of the thyroid cartilage. In a study by Jaipuria et al<sup>15</sup> aimed at assessing the accuracy of computed tomography to predict T-stage in laryngeal cancer, CT imaging identified 13 (76.5%) of 17 cases of histopathologically confirmed thyroid cartilage destruction. The most common cause of over staging identified by Agada et al<sup>9</sup> was arytenoid cartilage sclerosis,

while the causes of under staging included failure to detect thyroid cartilage invasion in one case, which was similar as in our study.

Destruction of the cartilage can often be identified through CT findings such as erosion, lysis, and transmural exo-laryngeal spread. However, irregular ossification of the thyroid cartilage along with the cartilage reaction occurring due to both, invasion by the tumour, as well as proximity to the tumour, perhaps explains the reason as to why CT is often unable to correctly predict cartilage involvement by the tumour.

In our study, we found the pre-epiglottic space to be involved in a third of the cases, while the paraglottic space was involved in 80% cases. Among the cartilages, the involvement of arytenoid, inner and outer cortex of thyroid was 73.34%, 53.34% and 33.34% respectively.

Interestingly, we found the thyroid gland to be histopathologically uninvolved in all the cases in the present study. This leads us to question whether ipsilateral hemithyroidectomy or total thyroidectomy is indeed required in all cases of patients with laryngeal cancer undergoing total laryngectomy. Thyroidectomy exposes the patient to a risk of hypothyroidism and hypoparathyroidism and may not always be indicated in patients with laryngeal cancer. Baghel et al studied the need for thyroid excision along with laryngectomy in carcinoma larynx, and concluded that the invasion of thyroid gland by laryngeal cancer is uncommon, and hence advocated total thyroidectomy to be done along with total laryngectomy in cases which had gross clinical, radiological or intraoperative thyroid gland involvement, subglottic extension and thyroid cartilage invasion.<sup>19</sup> Ceylan et al.<sup>20</sup> in their study also concluded that there may not be a need to perform thyroidectomy in all total laryngectomy cases and recommended thyroidectomy to be done in laryngeal carcinoma cases with subglottic extension and advanced hypopharyngeal tumours. There is, however, no doubt that lesions involving the glottic larynx with significant subglottic extension mandate an ipsilateral thyroid lobectomy be done, to facilitate ipsilateral tracheo-oesophageal lymph node clearance.

While whole organ sections have been the

conventionally accepted gold standard for histopathological analysis and have contributed extensively to understanding pathways of tumour spread, they are laborious, costly and yield unwieldy tissue samples which require bigger slides and more time to analyse and interpret. Hence, we propose a modified method of laryngeal sectioning which involves opening up the laryngeal specimen posteriorly, making two windows through the thyroid cartilage at designated spots, and three transverse whole organ sections at specific locations. Subsequent 2 mm cuts can be given akin to whole organ laryngeal sectioning, but these are done for a limited anatomical areas which have a bearing on the T-stage, instead of making several sections through the entire laryngeal specimen. Further, opening up of the larynx allows separate sections to be made for the right and left sides. This facilitates the availability of tissue samples which are smaller and hence easier to handle and analyse.

## Conclusion

Conventional whole organ sectioning of the larynx can be a cumbersome and tedious task. We propose the use of modified laryngeal sectioning to obtain representative tissue samples from the areas of interest for histopathological examination, as it is less resource intensive and saves time.

In our index study comparing the T-stages obtained through clinicoradiological examination and histopathological examination using modified laryngeal sectioning, we found 'fair' agreement between the two. A third of the patients were either upstaged or downstaged after histopathological examination of samples obtained through modified laryngeal sectioning.

## References

1. Jacques Ferlay IS, Dikshit R, Eser S, Mathers C, Rebelo M, Parkin DM, Forman D, Bray F. Cancer incidence and mortality worldwide: sources, methods and major patterns in GLOBOCAN 2012. *Int J Cancer*. 2014;136:29
2. Becker M, Burkhardt K, Dulguerov P, Allal A. Imaging of



- the larynx and hypopharynx. *European journal of radiology*. 2008 Jun 1;66(3):460-79
3. Castelijns JA, Becker M, Hermans R. Impact of cartilage invasion on treatment and prognosis of laryngeal cancer. *European radiology*. 1996 Apr;6(2):156-69
  4. Leroux-Robert J. Les epitheliomas intra-larynges. *Doin*; 1936
  5. Kirchner JA. What have whole organ sections contributed to the treatment of laryngeal cancer?. *Annals of Otolaryngology, Rhinology & Laryngology*. 1989 Sep;98(9):661-7
  6. Pillsbury HR, Kirchner JA. Clinical vs histopathologic staging in laryngeal cancer. *Archives of Otolaryngology*. 1979 Mar 1;105(3):157-9
  7. Sato K. *Functional histoanatomy of the human larynx*. Springer; 2018 Jan 22
  8. Olofsson J. Specific features of laryngeal carcinoma involving the anterior commissure and the subglottic region. *Canadian journal of otolaryngology*. 1975 Jan 1;4(4):618-36
  9. Agada FO, Nix PA, Salvage D, Stafford ND. Computerised tomography vs. pathological staging of laryngeal cancer: a 6 year completed audit cycle. *International journal of clinical practice*. 2004 Jul;58(7):714-6
  10. Wolny E, Idasiak A, Wydmański J, Miszczyk L. The difference of larynx cancer stage evaluation between clinical and pathological examinations. *Otolaryngologia Polska= The Polish Otolaryngology*. 2006 Jan 1;60(1):15-20
  11. Allegra E, Ferrise P, Trapasso S, Trapuzzano O, Barca A, Tamburrini S, Garozzo A. Early glottic cancer: role of MRI in the preoperative staging. *BioMed research international*. 2014 Aug 14;2014
  12. Ryu IS, Lee JH, Roh JL, Choi SH, Nam SY, Kim SY, Cho KJ. Clinical implication of computed tomography findings in patients with locally advanced squamous cell carcinoma of the larynx and hypopharynx. *European Archives of Oto-Rhino-Laryngology*. 2015 Oct;272(10):2939-45
  13. Atlanođlu S, Kezban-Gürbüz MK, Açıkalın M, Adapınar B, Özudođru E. Laryngeal cancer: Radiological staging by multislice computed tomography and pathological correlation. *OsmangaziTıpDergisi*. 2016;38(3):25-33
  14. Celakovsky P, Kalfert D, Smatanova K, Kordac P, Laco J, Chrobok V. Discordance between clinical and pathological TNM classification: influence on results of treatment and prognosis in patients with laryngeal cancer. *Neoplasma*. 2017 Jan 1;64(2):305-10
  15. Jaipuria B, Dosemane D, Kamath PM, Sreedharan SS, Shenoy VS. Staging of laryngeal and hypopharyngeal cancer: Computed tomography versus histopathology. *Iranian Journal of Otorhinolaryngology*. 2018 Jul;30(99):189
  16. El-Sharkawy L, El-Antably A, Gharib F, Hareedy A, Algarf T. Correlation between preoperative endoscopic findings and computed tomography with postoperative histopathology in the staging of laryngeal carcinoma. *The Egyptian Journal of Otolaryngology*. 2019 Jan;35(1):41-6
  17. Contrera KJ, Hair BB, Prendes B, Reddy CA, Zimmer DI, Burkey BB, Tassone P. Clinical versus pathologic laryngeal cancer staging and the impact of stage change on outcomes. *The Laryngoscope*. 2021 Mar;131(3):559-65
  18. Hartl DM, Landry G, Bidault F, Hans S, Julieron M, Mabelle G, Janot F, Brasnu DF. CT-scan prediction of thyroid cartilage invasion for early laryngeal squamous cell carcinoma. *European Archives of Oto-Rhino-Laryngology*. 2013 Jan;270(1):287-91
  19. Baghel SS, Singhal P, Verma N, Sehra R, Yadav R, Agarwal S, Sharma MP, Gupta DP. Is thyroid excision mandatory with laryngectomy in carcinoma larynx?. *BMC cancer*. 2020 Dec;20(1):1-6
  20. Ceylan A, Köybađiođlu A, Yilmaz M, Uslu S, Asal K, Ýnal E. Thyroid gland invasion in advanced laryngeal and hypopharyngeal carcinoma. *Kulak BurunBogazIhtisas Dergisi: KBB= Journal of Ear, Nose, and Throat*. 2004 Jul 1;13(1-2):9-14.