

A Case Report on Kimura Disease

<https://doi.org/10.47210/bjohns.2023.v31i2.932>

Biswajit Adhikari,¹ Sarmila Sen,¹ Somnath Saha¹

ABSTRACT

Introduction

Kimura disease is a rare chronic inflammatory disease that, if occurs in the head and neck region, presents with a swelling.

Case Report

A 14-year-old male presented to our ENT OPD with a painless left cheek swelling. The swelling was first noticed by the patient about 3.5 years back. The swelling was gradually progressive in size. It was mobile in all directions, cystic in consistency and non-tender.

Discussion

Kimura Disease is a rare chronic inflammatory disorder described as a "eosinophilic hyperplastic lymphogranuloma" in Chinese literature. This disease is endemic in middle-aged Asian males and is seen sporadically in the non-Asian population. There is no standardized treatment protocol present for Kimura Disease. Treatment modalities include surgical resection, cytotoxic and radiation therapy, as well as regional or systemic steroid therapy. The role of surgery is primarily for diagnostic and cosmetic purposes. Relapses are common and recurrence rate is high. The overall outcome is good as there is no association with malignancy.

Keywords

Kimura Disease; Chronic Inflammatory Disorder; Head and Neck; Steroid

Kimura disease (KD) is a rare chronic inflammatory disorder that usually presents as a subcutaneous swelling in the head and neck region, associated with lymphadenopathy. It may also involve the salivary glands. It is a benign disorder, first reported by Kimm and Szeto in 1937 in China.¹ In 1948, a Japanese doctor named Kimura described the details of the disease and coined the term 'Kimura Disease'.² KD is rare in India and only 200 cases have been reported worldwide as its diagnosis is mainly based on the histopathological features.³ It is generally seen in young Asian adults,⁴ with the maximum prevalence being in the 20-40 year age group. Males are affected more than women.^{5,6} The disease apart from being endemic in Asian countries, occurs sporadically in other places also. Patients usually present with a mass in the head and neck region with involvement of subcutaneous soft tissue, salivary glands, and occasional regional lymphadenopathy.^{7,8} Peripheral blood smear shows persistent eosinophilia and increased serum IgE levels. These two features appear to be

consistent with KD. The disease is self-limiting, although recurrences can occur over a period of years. The disease may be commonly associated with renal disease.⁹ The diagnosis is often difficult, and biopsy or excision of the involved mass for a pathological study is necessary. Here we report a rare case of a 14 year old male with a left cheek mass.

Case Report

A 14 year old male presented to our ENT OPD with a painless left cheek swelling which was about 4*5 cm in dimension. The swelling was first noticed by the patient about 3.5 years back. The swelling had slowly increased in size since then. The patient visited multiple doctors

1 - Department of ENT and Head Neck Surgery, Calcutta National Medical College and Hospital, Kolkata

Corresponding author:

Dr Biswajit Adhikari

email: biswajitadhikari50@gmail.com

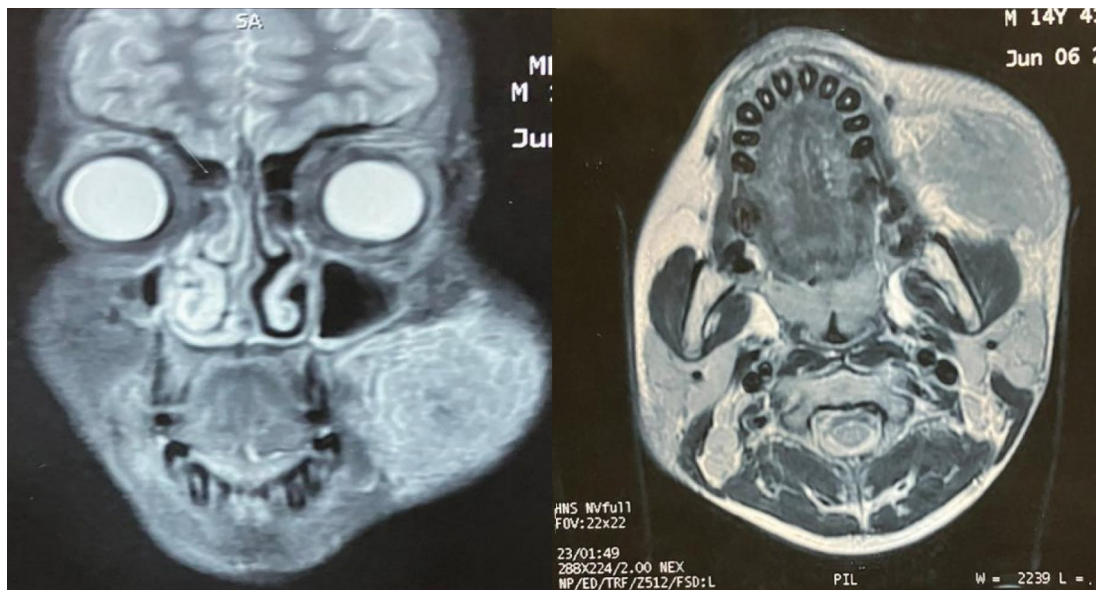


Fig. 1. (Left) Coronal cut and (Right) Axial cut of MRI of face reveals a moderately well-defined SOL in the left buccal space. It is hypo-intense in T1 and T2WI. The left parotid duct is likely infiltrated and compressed by the SOL. The SOL is deep to the deep fascia of face, lying anterior and superficial to the left masseter. Left parotid gland is mildly atrophic.

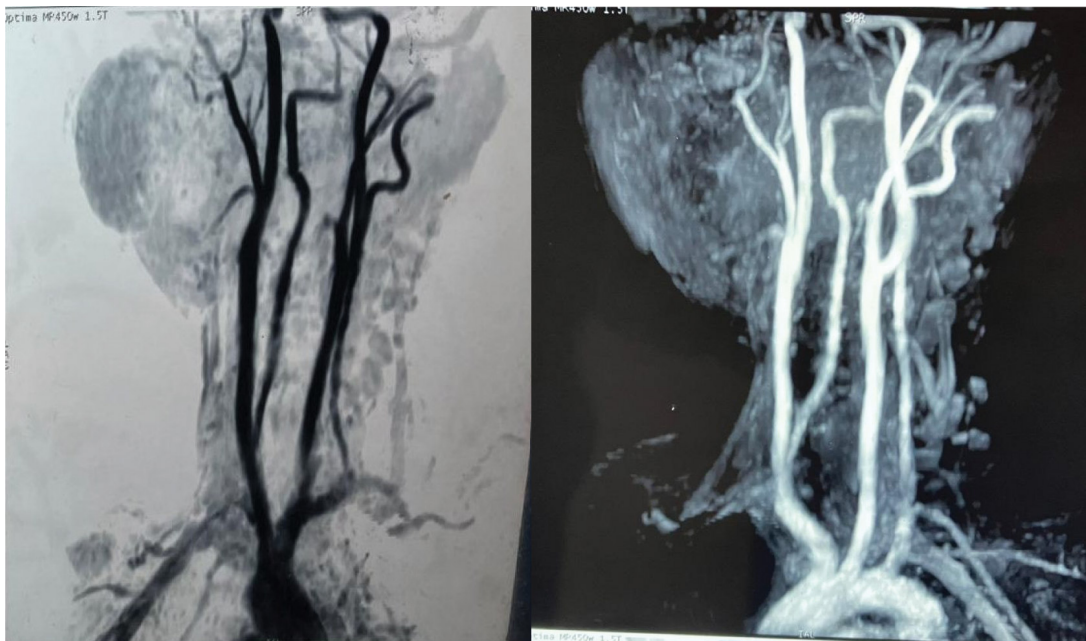

Fig. 2. (Left and Right) Angiography of Neck and Face arteries shows a left sided facial SOL, supplied by a branch of the left facial artery.

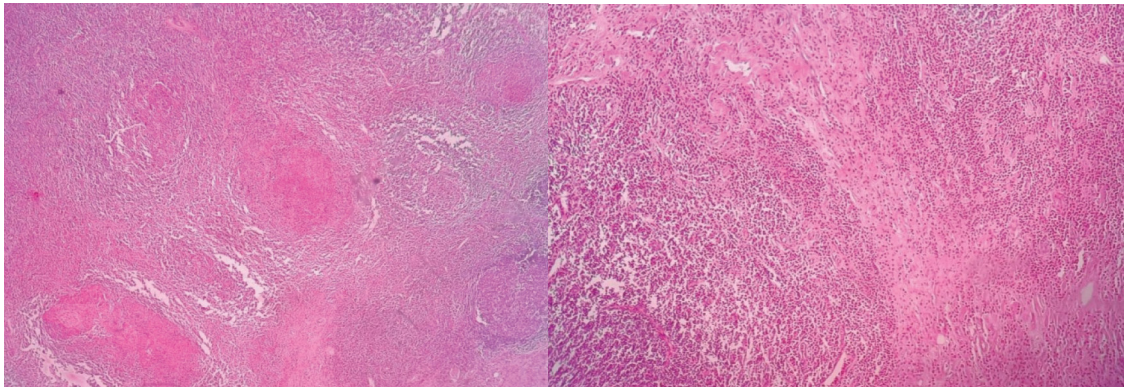


Fig 3: (Left) 40x magnification(H&E stain) and (Right)100x magnification (H&E stain). Images show multiple lymphoid follicles with prominent germinal centres, along with multiple proliferating blood vessels. In between the lymphoid follicles a large number of eosinophils are present.

and health facilities but did not get any symptomatic relief even after various treatments. On examination, the swelling was mobile in all directions, cystic in consistency and non-tender. Skin above the swelling appeared normal. Oral cavity examination revealed a grade 3 tonsillar hypertrophy but other findings were normal.

There was also a 2 cm swelling present in the left pre auricular region which was mobile, non-tender and firm in consistency. There was no history of low-grade fever, cough or any chronic symptoms. Few level 2 lymph nodes on the left side of neck were palpable. No other regional lymphadenopathy was seen or felt. Systemic examination was normal.

His blood examination revealed white blood cell count to be 12100/microlitre. The percentage of eosinophil was about 19.5%, normal being in the 2-4% range.

Ultra sound examination showed a 34*25 mm echoic cystic swelling with stippled calcification along with increased internal vascularity.

Ultra sound of the kidney-ureter-bladder region was normal.

MRI neck suggested a well-defined altered intensity heterogeneous soft tissue mass lesion in the left buccal fat pad. Mild atrophy of the left parotid gland, possibly due to infiltration of the duct, was noted. Bilateral level 2 lymph nodes and left sided level 1b lymph nodes were enlarged. (Fig. 1)

Angiogram of neck arteries suggested that the lesion was being fed by a branch of the facial artery. (Fig. 2)

After obtaining fitness for surgery, the left cheek mass was excised via lateral rhinotomy approach. The specimen was sent for Histopathological examination. Suture removal was done on post operative day 7. Post operative period was uneventful.

Excisional biopsy from left cheek lesion revealed a polymorphous population of lymphoid cells comprising predominantly of mature lymphocytes mixed with germinal centre cells, plasma cells, histiocytes and a few tangible body macrophages (Fig. 3).

After histopathological study suggested that it was KD, we started him on oral prednisolone. After the local swelling of the cheek was excised, the post auricular swelling reduced rapidly. There was a decrease in size of the faucial tonsil also. After a few days of observation in the ward, we discharged him with oral corticosteroids.

Discussion

KD is a rare chronic inflammatory disorder. In 1937, Kim and Szeto first described the disease as “eosinophilic hyperplastic lymphogranuloma”.¹⁰ The disease is known to us as KD since its detailed description can be found in a paper by Kimura et al. published in 1948.¹¹ This disease is endemic in middle-aged Asian males and seen

sporadically in the non-asian population. Chen et al. concluded in their study that KD should be included in the differential diagnosis of any lymph node demonstrating an eosinophilic infiltrate and prominent follicular hyperplasia, in a patient of any race.¹² The disease is mainly seen in males within the 2nd and 3rd decade, but can be found at any age.⁴ It presents predominantly as subcutaneous nodules in the head and neck, often unilateral, and frequently associated with lymphadenopathy. Salivary glands can also be involved in the disease. Orbit, eyelid, palate, axilla, groin, and arm and pharynx have also been reported to be involved.^{12,13} The disease is generally benign and self-limiting. Although it is a chronic inflammatory disorder with unknown etiology and pathogenesis, the presence of eosinophilia and increased serum levels of IgE, mast cells, IL-4, IL-5 and IL-13 in patients suggests either an unusual autoimmune response or an immune reaction towards an allergen.¹⁴ Clonal T-cell population contributes to the disease development and recurrence.¹⁵ Although there is no specific diagnostic feature of KD, fine needle aspiration cytology is helpful in the preoperative diagnosis.

Hui et al. classified the histopathological features of KD.⁶ In our case, the histopathological study showed an inflammatory lesion comprising of nodular aggregates of lymphoid tissue admixed with plenty of eosinophils. These nodules were separated by dense interstitial fibrosis. The lymphoid aggregates contained many reactive lymphoid follicles having prominent germinal centers. Plenty of mature eosinophils were present, both intermixed with lymphoid cells and also with zones of fibrosis. Hyalinized vessels were also present. Salivary gland duct and acini were focally present, surrounded by lymphoid cells and eosinophils. The differential diagnoses include angio-lymphoid hyperplasia with eosinophilia (ALHE), Hodgkin's disease, Kaposi sarcoma, eosinophilic granuloma, epithelioid haemangioma, Castleman's disease, tuberculosis, dermatopathic lymphadenopathy, lymphadenopathy of drug reactions, parasitic lymphadenitis, eosinophilic granuloma and epithelioid haemangioma.¹²

There is no standardized treatment protocol present for KD. Treatment modalities include surgical resection, cytotoxic and radiation therapy, as well as regional or systemic steroid therapy.¹⁴ The role of surgery is mainly for diagnostic and cosmetic purposes. Systemic corticosteroids can be used with or without other treatment modalities. Relapses are common and the recurrence rate is as high as 40%, despite early initiation of treatment of patients.¹⁶ Though there is no consensus for the treatment of recurrence, the overall outcome is good as there is no association with malignancy.

Conclusion

Although KD is a rare entity, it should be included in the differential diagnosis for all head & neck swellings. The patient should be assured that although the disease has a high recurrence rate, treatment options are available and the disease is not fatal.

References

1. Kim HT. Eosinophilic hyperplastic lymphogranuloma, comparison with Mikulicz's disease. *Chin. Med. J.* 1937;23:699-70
2. Kimura TJ. On the unusual granulations combined with hyperplastic changes of lymphatic tissue. *Trans Soc Pathol Jpn.* 1948;37:179-80
3. Rajesh A, Prasanth T, Sirisha VN, Azmi MD. Kimura's disease: A case presentation of postauricular swelling. *Nigerian Journal of Clinical Practice.* 2016 Nov 7;19(6):827-30
4. Li TJ, Chen XM, Wang SZ, Fan MW, Semba I, Kitano M. Kimura's disease: a clinicopathologic study of 54 Chinese patients. *Oral Surgery, Oral Medicine, Oral Pathology, Oral Radiology, and Endodontology.* 1996 Nov 1;82(5):549-55
5. Chan JK, Hui PK, Ng CS, Yuen NW, Kung IT, Gwi E. Epithelioid haemangioma (angiolymphoid hyperplasia with eosinophilia) and Kimura's disease in Chinese. *Histopathology.* 1989 Dec;15(6):557-74
6. Hui PK, Chan JK, Ng CS, Kung IT, Gwi E. Lymphadenopathy of Kimura's disease. *The American journal of surgical pathology.* 1989 Mar 1;13(3):177-86
7. Ioachim H, Ratech H. Kimura lymphadenopathy. *Ioachim's lymph node pathology.* 3rd ed. Philadelphia: Lippincott-Raven. 2002:209-11
8. Abhange RS, Jadhav RP, Jain NK. Kimura disease: A rare case

- report. *Annals of Pathology and Laboratory Medicine*. 2018 Mar 22;5(3):C53-55
9. Fouda MA, Gheith O, Refaie A, El-Saeed M, Bakr A, Wafa E, Abdelraheem M, Sobh M. Kimura disease: a case report and review of the literature with a new management protocol. *International journal of nephrology*. 2011 Mar 7;2010
 10. Kim HT. Eosinophilic hyperplastic lymphogranuloma, comparison with Mikulicz's disease. *Chin. Med. J.* 1937;23:699-70
 11. Kimura TJ. On the unusual granulations combined with hyperplastic changes of lymphatic tissue. *Trans Soc Pathol Jpn*. 1948;37:179-80
 12. Chen H, Thompson LD, Aguilera NS, Abbondanzo SL. Kimura disease: a clinicopathologic study of 21 cases. *The American journal of surgical pathology*. 2004 Apr 1;28(4):505-13
 13. Shetty AK, Beaty MW, McGuirt Jr WF, Woods CR, Givner LB. Kimura's disease: a diagnostic challenge. *Pediatrics*. 2002;110:e39
 14. Meningaud JP, Pitak-Arnnop P, Fouret P, Bertrand JC. Kimura's disease of the parotid region: report of 2 cases and review of the literature. *Journal of oral and maxillofacial surgery*. 2007 Jan 1;65(1):134-40
 15. Chong WS, Thomas A, Goh CL. Kimura's disease and angiolymphoid hyperplasia with eosinophilia: two disease entities in the same patient. Case report and review of the literature. *International journal of dermatology*. 2006 Feb;45(2):139-45
 16. Göçmen H, Oguz H, Astarci M, Samim E. Kimura's disease: case report and brief review of the literature. *The Journal of otolaryngology*. 2006 Oct;35(5):358-60.