

Choanal Atresia: Clinical Features and Factors Affecting Its Surgical Outcomes

<https://doi.org/10.47210/bjohns.2023.v31i3.83>

Abhilasha Somashekhar,¹ Prem Kumar,¹ Sandhya Poothatta Manolikandy,¹ Syed Mohammed Shoib¹

ABSTRACT

Introduction

One of a rare congenital anomaly seen in the development of nose is choanal atresia, whose occurrence is 1 in 5000-8000 live births. This study highlights our experiences in the management of choanal atresia.

Materials and Methods

It is a retrospective study, which includes the systematic analysis of case files of patients who underwent surgical treatment for choanal atresia from the year 2015 to 2022.

Results

Total of 11 cases (15 operated sides) which has 9 female (53%) and 8 male (47%). Majority of them were bony atretic plate (10) followed by mixed variety (5) and none purely membranous. Age at 1st surgery in bilateral cases ranged from 6th day of life to 18th day of life. For unilateral cases the age at 1st surgery ranged from 26th day of life to as late as 10 years old.

Conclusion

Management of choanal atresia involves multi-disciplinary approach and preventing restenosis is a challenge. Factors effecting the outcome of surgery are age and weight of the child, as bigger the child in size, wider the choanal arches can be opened with less post-operative scarring and restenosis. Usage of nasopharyngeal airway as a stent in primary repair during early post-operative period is essential to stabilize the nasal airway.

Keywords

Choanal Atresia; Management; CHARGE Syndrome; Nasal Stenting; Transnasal Endoscopic Repair

One of a rare congenital anomaly seen in the development of nose is choanal atresia, whose occurrence is 1 in 5000-8000 live births.^{1,2} Roederer in 1755 was first to describe this term.³ The atretic plate is the anomalous structure which is bounded medially by vomer, laterally by palatal bone and medial pterygoid plate, superiorly by the sphenoid and inferiorly by the horizontal portion on palate. During the development, the widening of vomer and medialization of the pterygoid plate constricts the posterior choana.³⁻⁵

Choana atresia can either present as unilateral or bilateral with more preponderance for the latter.^{2,3} Since the neonates are obligate nose breathers, the bilateral obstruction presents as an emergency. Whereas unilateral choanal atresia may go unnoticed until later stages or been discovered coincidentally during the examination or when presents with symptoms like unilateral nasal obstruction, nasal mucoid discharge, and noisy breathing.⁶⁻⁸

Bilateral choanal atresia demands immediate attention causing respiratory distress which could result in death due to asphyxia if neglected.³ It usually presents itself in the form of cycle of respiratory distress causing cyanosis and apnoea leading to crying which in turn relieves the symptoms due to oral respiration.^{3,7,9} The immediate measure is to secure the oral airway and establish feeding through orogastric tube.⁶

In most of the cases choanal atresia occurs as an isolated deformity, with 40 to 70% non-syndromic associations. Exceedingly small portion of it has syndromic association.^{2,4,5,7} This was 1st described by Hall in 1979 and Pagon et al gave the acronym CHARGE association.

1 - Indira Gandhi Institute of Child Health, Bangalore

Corresponding author:

Dr Abhilasha Somashekhar
email: dr.s.abhilasha@gmail.com

(Coloboma of the eye, heart defects, choanal atresia, retarded growth and development and associated ear anomalies).⁸

The main aim of surgical procedure is to remove the atretic plate safely to restore the normal patency of the nose. In 1851, Carl Emmert attempted a 1st successful repair in a 7 year old boy by blindly puncturing the atretic plate with progressive dilation. However, such blind approaches had life threatening complications. Later Uffenorder in 1908, resected part of septum along with atretic plate to create a uni-neochoana. This forms the basis for the currently practiced surgical strategy. Since in 1900s the good visibility was a problem, another method emerged to address the issue i.e., trans palatal approach. However, this method has its shares of complications too. With the introduction of Storz Hopkins rod telescopes with light sources, there has been a great revolution in the field of nasal surgeries. Since then, transnasal endoscopic repair has become popular.¹⁰

One of the biggest challenges' surgeon faces after the repair is occurrence of restenosis which ranges from 0-85%.^{7,11} Various methods to bypass this has been tried such as use of Mitomycin and placement of nasal stents for considerable period.^{2,9,11-12}

We present this retrospective study by highlighting our experiences in the management of choanal atresia.

Materials and Methods

It is a retrospective study, which includes the systematic analysis of case files of patients who underwent surgical treatment for choanal atresia from the year 2015 to 2022. Cases with inadequate data were excluded and we considered all the cases that were operated under a single surgeon to reduce the confounding factor.

All the demographic data of patient, presenting complaints, birth history, associated anomalies, association of CHARGE syndrome, side of involvement, type of atretic plate, age and weight of the child at the 1st surgery, number of surgeries, use of nasal stent and mitomycin

were meticulously documented along with their follow up findings.

In case of bilateral involvement, the primary aim is to secure the airway by placing an oral intubation or McGovern's nipple. In all cases computed tomography of nose and paranasal sinuses was taken to know the type of atresia and anatomy (Fig 1).

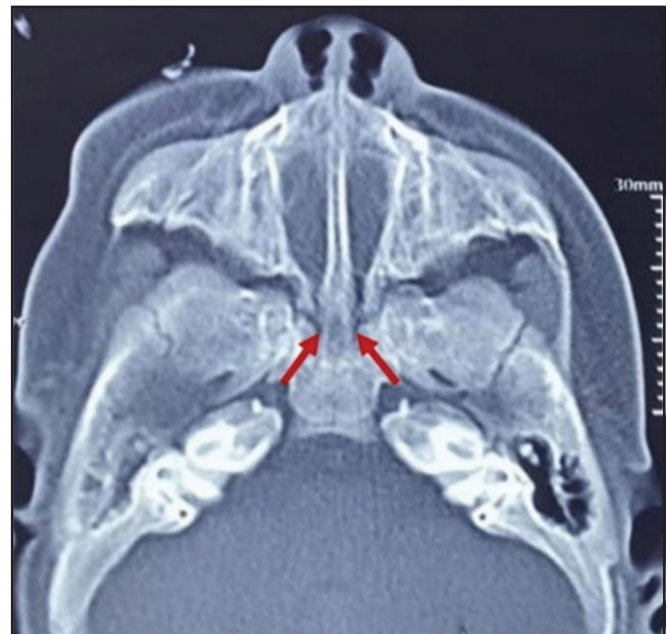


Fig. 1. Non-Contrast Computed tomography picture showing axial view of nose and paranasal sinus. Note the bony narrowing of posterior nasal choanal on both the sides (red arrows) causing obstruction of airway passage.

In case of unilateral involvement child is allowed to thrive well before intervening. Meanwhile the child was evaluated for presence of other anomalies and association with CHARGE syndrome.

All the children were managed under general anaesthesia with oral intubation and endoscopic transnasal approach. They were positioned supine, with their head slightly elevated in anti-Trendelenburg position. Under vision suctioning of nasal discharge was done, followed by application of saline with local decongestants using cotton pledgets. Diagnostic nasal endoscopy was done in

most of the cases with a 4 mm rigid telescope. In some cases, due to narrowing of nasal cavity 2.7 mm telescope was used for better instrumentation. Once the type and side of atresia was confirmed, using nasal ball point the atretic plate was opened inferiomedially. Later atretic plate was widened using microdebrider blades / burrs (precision cutters 3.5mm diameter and 8cm length) and sometimes kerrison punch (Fig 2). Next important step was to create uni neochoana by performing posterior septectomy (Fig.3). Post operatively before placement of stents , 0.4mg/ml of mitomycin c by diluting 2mg in 5ml of sterile water was used in all the cases. The cotton pledgets were soaked into the diluted solution of Mitomycin and placed insitu for 2 minutes.

Later to maintain nasal patency, soft nasopharyngeal airway of appropriate size was used as a stent. It was secured over the nose by a plaster for 14 days under the coverage of antibiotics. Regular usage of saline nasal drops was advised to avoid crusting. During the discharge, the care takers were briefed about warning signs like nasal discharge, difficulty breathing or noisy breathing and to visit hospitals immediately if anything was noticed. They had instructed to take adequate care for child to avoid upper respiratory tract infections and seek treatment promptly if contracted.

For follow up the child was reviewed every week for 1st 15 days until the removal of stent in case of primary

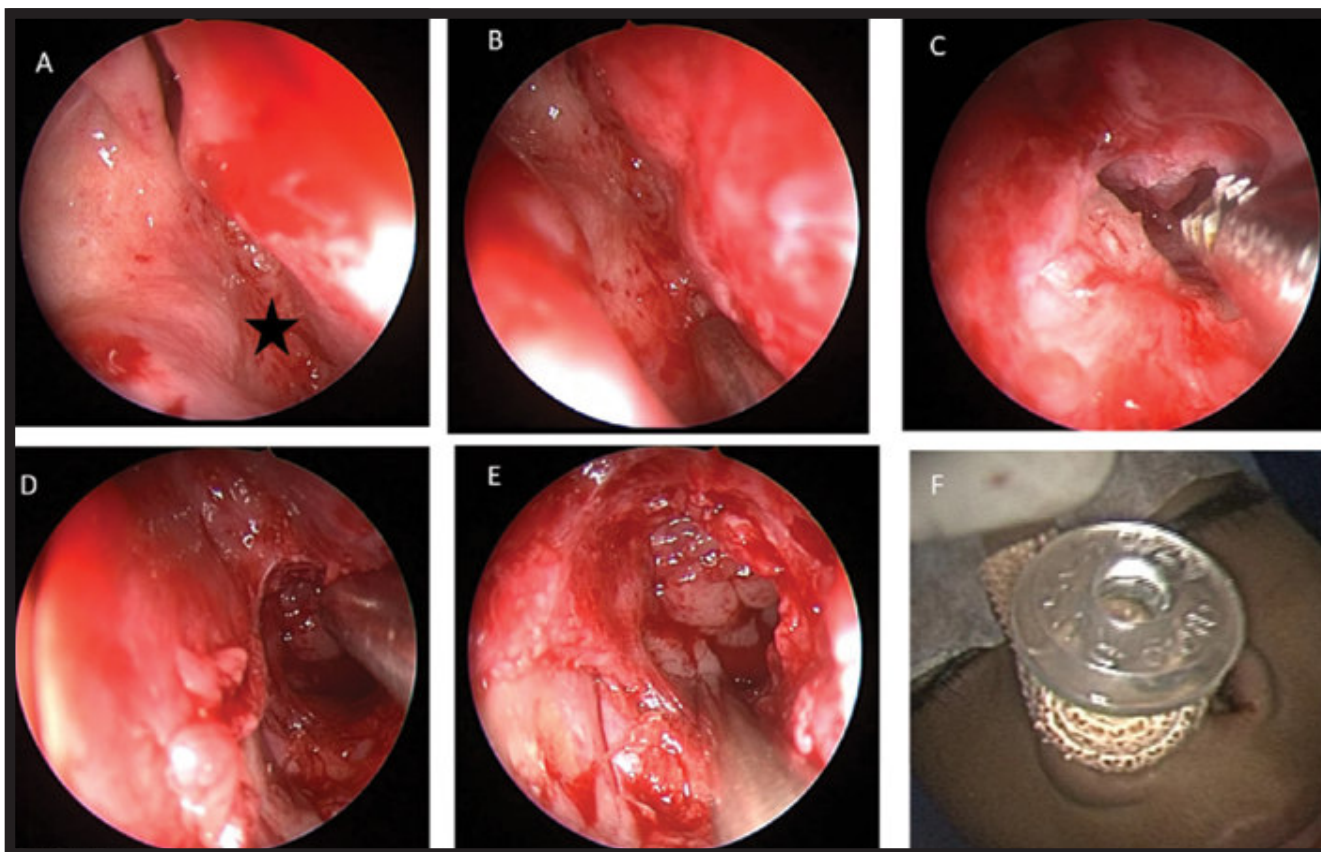


Fig. 2. Intra operative images of 10day old child who weighed 2kgs during the surgery (A) Right sided choanal atresia. Note the atretic plate (star). (B) The suction tip placed over atretic plate. (C) widening of atretic plate using microdebrider (D) Suction tip over opened atretic plate (E) opening of atretic plate into nasopharynx showing adenoid tissue (F) Post operative nasal external nasal splinting.

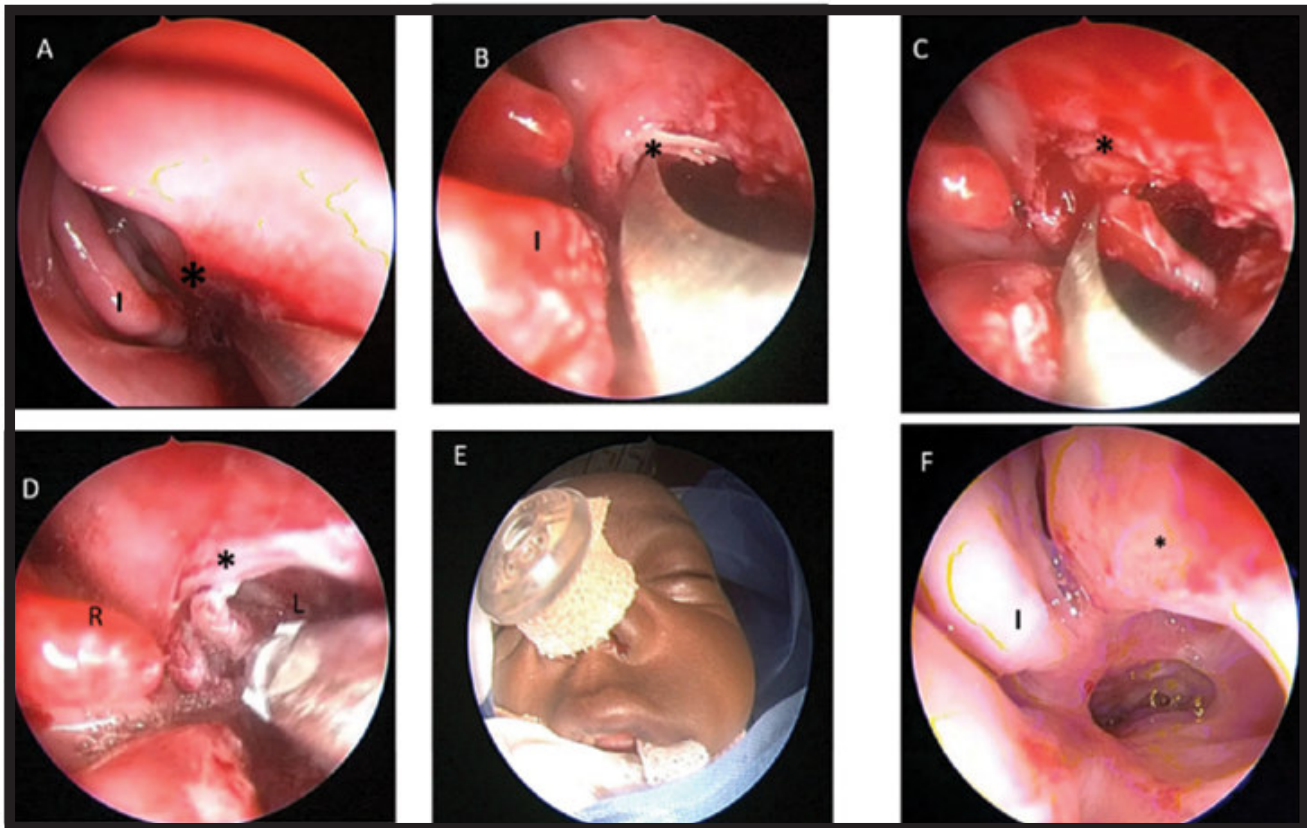


Fig. 3. (A) Right sided choanal atresia. Note the septum on left side (Asterix) and inferior turbinate (I) on right side. (B & C) Posterior septectomy being done using sickle knife, cartilage part is being removed. (D) unineochoana can be seen, note the right side inferior turbinate, asterix the removed posterior end of septum (E) Post operative nasal external nasal splinting (F) post operative DNE picture showing wide opened cavity.

surgery. Later they were planned for check DNE after 1 month to reassess the nasal cavity. However, performance of diagnostic nasal endoscopy at follow ups were not counted in the number of surgical attempts. Then regular follow ups were done once in 3 months.

Final outcomes of surgery were considered as normal patency if more than 50% of airway was open, partial restenosis if less than 50% of airway was open and complete restenosis where there was no passage. Repair was considered successful if the patient had clinically or endoscopically confirmed patent posterior choanae at last follow up (Fig. 3). The same surgical method was used for revision procedure. In case of revision surgeries, there was no placement of nasal stents.

All the collected data was entered into Microsoft excel and required results were noted.

Results

Total of 11 cases (15 operated sides) were included in our study. Four children had bilateral involvement thus giving 15 operated sides. This study had 9 female (53%) and 8 male (47%) patients (Fig. 4).

Involvement of right side was 9 and left side was 8 (Fig. 5).

Majority of them were bony atretic plate (10) followed by mixed variety (5) and none purely membranous (Fig.6).

Among 7 unilateral cases, 4 cases presented with

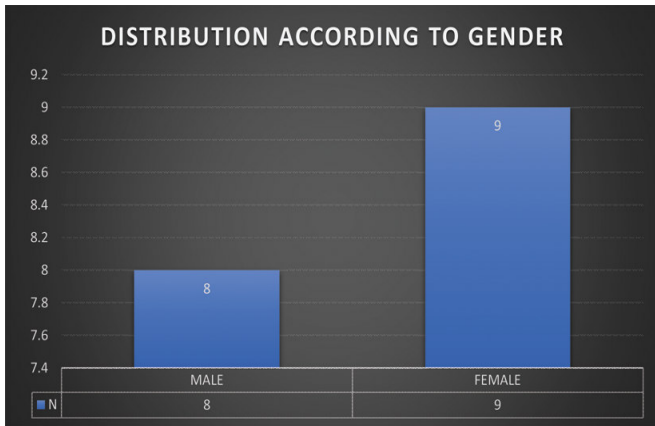


Fig. 4. Distribution according to gender

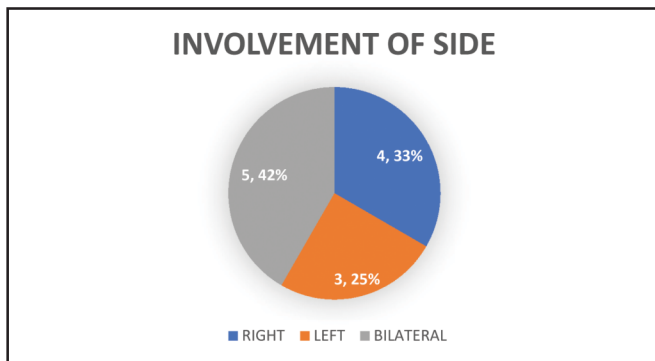


Fig. 5. Involvement of side

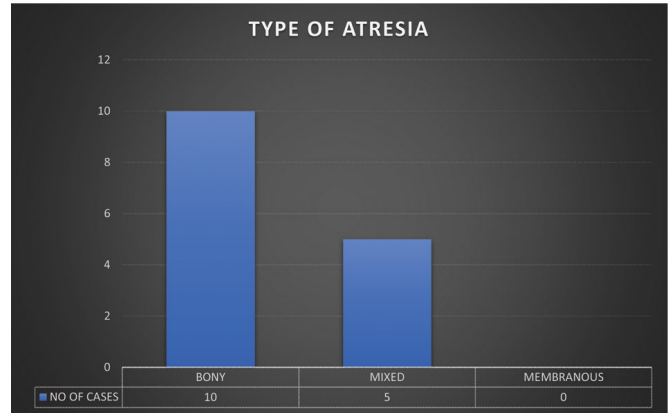


Fig. 6. Distribution according to type of atresia

unilateral nasal obstruction since birth with persistent nasal discharge. Rest 3 cases, 2 had difficulty feeding and hence failure to thrive whereas one case had severe distress because of which the child had to be intubated to maintain airway. All these 3 cases had associated anomalies and 2 were positive for CHARGE syndrome. One of the unilateral cases 2 presented to us at age of 10 years. Among 4 bilateral cases, 3 had to be intubated in view of respiratory distress. 1 bilateral case was managed just with McGovern’s nipple. In all 4 cases there was feeding difficulties and inability to pass nasogastric tube bilaterally (Table 1).

Table I: Clinical features and associated anomalies

CASE NO	BIRTH HISTORY	CLINICAL FEATURES	ASSOCIATED ANOMALIES	AGE AT 1ST SURGERY	WEIGHT DURING 1ST SURGERY (KGS)
1	Term	Unilateral nasal obstruction with persistent nasal discharge	Nil	2yr 7m	7
2	Late Preterm/ IUGR	Failure to thrive, difficulty feeding, moderate dehydration repeated anaemia	Solitary kidney with dysplastic changes	1 month 8 Days	1.72
3	Term	Child did not cry immediately after birth and had to be resuscitated, intubated and mechanically ventilated for a week. Child was Referred to us on day 16 in view of persistent respiratory distress.	Tracheomalacia with ASD and tricuspid atresia CHARGE syndrome	26 d	3.6

Table I (Contd.)

Table I (Contd.) : Clinical features and associated anomalies

CASE NO	BIRTH HISTORY	CLINICAL FEATURES	ASSOCIATED ANOMALIES	AGE AT 1ST SURGERY	WEIGHT DURING 1 ST SURGERY (KGS)
4	Preterm/IUGR	Referred to us on D6 with refusal of feeds, child had sepsis	Microcephaly with symmetrical IUGR with dysmorphism with right DNS CHARGE syndrome	1.5 m	2.1
5	Term	Unilateral nasal obstruction with persistent nasal discharge	Nil	6 m	5.5
6	Term	Unilateral nasal obstruction with discharge since birth, disturbed sleep, snoring.	Nil	5 m	5.2
7	Term	Unilateral nasal obstruction with persistent nasal discharge	Nil	10 y	20
8	Term	Child did not cry immediately after birth resuscitation done. Difficulty feeding, inability to pass nasogastric tube bilaterally and was referred to us on Day 1	Nil	8 d	2.6
9	Term	Had respiratory distress since Day 1 of life maintaining with oxygen support. On D4 had to be intubated in view of worsening of distress and referred here. Inability to pass nasogastric tube bilaterally	CHARGE syndrome	18 d	3
10	Late Preterm/AGA	Child had severe respiratory distress and had to be intubated and mechanically ventilated and referred here on D6.	Retinopathy with microcephaly. Charge syndrome	10 d	2
11	Term	Child developed respiratory distress and inability to initiate feed 2hr after birth and inability to pass nasogastric tube bilaterally and was referred here. Maintained with oral McGroven Nipple	Right DNS with hypertrophic inferior turbinate	6 d	3

Age at 1st surgery in bilateral cases ranged from 6th day of life to 18th day of life. For unilateral cases the age at 1st surgery ranged from 26th day of life to as late as 10 years old. All cases underwent choanal atresia repair under

GA. Post procedure local application of Mitomycin was done in all cases before placement of nasal stent with mean period of 14 days. Outcomes of surgeries were systematically analyzed and recorded. Most of the cases

required only one stage of intervention, maximum 3 interventions were done to achieve full patency (Table II).

One of the unilateral case who underwent total of 3 surgeries had associated adenoid hypertrophy and hence

underwent adenoidectomy also. Two unilateral involvement cases associated with CHARGE syndrome required just one intervention whereas for bilateral involvement cases required one revision surgery.

Table II : Outcomes of surgery

CASE NO	SIDE	AGE AT 1 ST SURGERY	WT DURING 1 ST SURGERY (KGS)	OUTCOME OF 1 ST SURGERY	2 ND SURGERY AGE	OUTCOME OF 2 ND SURGERY	AGE AT 3 RD SURGERY	OUTCOME OF 3 RD SURGERY	STENTING DURATION IN PRIMARY REPAIR	MITO-MYCININ PRIMARY REPAIR
1	RIGHT	2 Y 7M	7	COMPLETE RESTENOSIS	3Y	PARTIALLY RESTENOSIS	4Y	NORMAL PATENCY	2 WKS	YES
2	RIGHT	6D	1.72	NORMAL PATENCY	-	-	-	-	2 WKS	YES
3	RIGHT	26D	3.6	NORMAL PATENCY	-	-	-	-	2WKS	YES
4	LEFT	1.5M	2.1	NORMAL PATENCY	-	-	-	-	2WKS	YES
5	LEFT	6M	5.5	NORMAL PATENCY	-	-	-	-	2WKS	YES
6	RIGHT	5M	5.2	PARTIAL RESTENOSIS	7M	PARTIAL RESTENOSIS	9M	NORMAL PATENCY	2 WKS	YES
7	RIGHT	10Y	20	NORMAL PATENCY	-	-	-	-	2WKS	YES
8	RIGHT	8D	2.6	PARTIAL RESTENOSIS	2M	NORMAL PATENCY	-	-	2 WKS	YES
	LEFT	8D	2.6	PARTIAL RESTENOSIS	2M	NORMAL PATENCY	-	-	2 WKS	YES
9	RIGHT	18D	3	PARTIAL RESTENOSIS	6M	PARTIAL RESTENOSIS	7M	NORMAL PATENCY	2 WKS	YES
	LEFT	18D	3	NORMAL PATENCY	-	-	-	-	2 WKS	YES
10	RIGHT	10D	2	NORMAL PATENCY	-	-	-	-	3 WKS	YES
	LEFT	10D	2	PARTIAL RESTENOSIS	1.5M	NORMAL PATENCY	-	-	3WKS	YES
11	RIGHT	6D	3	PARTIAL RESTENOSIS	2M	NORMAL PATENCY	-	-	2 WKS	YES
	LEFT	6D	3	PARTIAL RESTENOSIS	2M	NORMAL PATENCY	-	-	2 WKS	YES

Discussion

One of a rare congenital anomaly seen in the development of nose is choanal atresia, whose occurrence is 1 in 5000-8000 live births.^{1,2} Choanal atresia is said to have interesting ratio of 2:1 with respect to occurrences in female to male, right side to left side and unilateral to bilateral presentation.³ In our study, female was more than male; right side was more involved than left side and majority of them were unilateral.

According to initial understanding the atretic plate was either bony or membranous. However, with advancement in investigations, using CT scan new anatomical classification was done quoting the atretic plate to be either bony or mixture of bony with membranous but never just membranous.^{3,12} Similar findings were noted in our study too reinforcing the theory of Ramseden JD et al implying that choanal atresia is a medialization of the pterygoid processes and the whole lateral nasal wall but not just a persistent buconasal membrane.¹⁴ All the unilateral cases showed only the bony component explaining the possibility of delayed surgical intervention which led the bone to become denser unlike in bilateral cases where it was addressed earlier and found to have mixed variety.⁸

During the evaluation of child overall assessment to rule out other anomalies and associated syndromes is especially important.^{2,4,5,7} Along with CT scan of nose and paranasal sinuses, 2D echo, renal scan, ophthalmology, and audiological evaluation was done to rule out CHARGE syndrome. Burrow et al suggested that their study showed 73.6% of their cases had associated deformities.¹⁵ In our study it was found to be 54.5%.

International Pediatric Otolaryngology Group (IPOG) suggests considering at the least heart scan before surgical intervention if not other evaluations. This is mainly to rule out the possible life-threatening complications during the general anaesthesia for the surgery. It also recommends delay the timing of surgery (6 months to 1 year) in case of unilateral involvement. However, emergence of symptoms may warrant an earlier intervention.¹¹ We followed the same line of thoughts and let the child thrive well before intervention in cases of unilateral involvement with less symptoms. 57 % of unilateral cases (n=4) who

had only unilateral nasal obstruction with nasal discharge as their presenting symptoms had come to us at later stages as it was not life threatening. Case number 7 presented to us at age of 10yrs old. Rest of unilateral cases (n=3) were intervened earlier i.e., before 6 months as they had either respiratory distress or failure to thrive. We recommend considering weight of the child. This lays on similar idea mentioned by Moreddu et al who concluded in their study to wait for child to gain appropriate weight for successful outcome when possible. Bigger the child in size, wider the choanal arches can be opened with less post-operative scarring and restenosis.²

Bilateral choanal atresia demands immediate attention causing respiratory distress which could result in death due to asphyxia if neglected.³ The immediate measure is to secure the oral airway and establish feeding through orogastric tube.⁶ Our study had 4 bilateral cases, since the primary aim is to secure the airway, 3 cases had to be intubated in view of respiratory distress. One unusual bilateral case presented at 5th day of life surprisingly without much respiratory distress and managed just with McGovern's nipple. Once the airway was secured, the child was evaluated and then planned for surgical intervention which ranged between 6- 18 day of life.

The main aim of surgical procedure is to remove the atretic plate safely to restore the normal patency of the nose. Various techniques have been proposed since the 1st successful repair in 1851 by Carl Emmert. With the introduction of Storz Hopkins rod telescopes with light sources, there has been a great revolution in the field of nasal surgeries. Since then, transnasal endoscopic repair has become popular.¹⁰ This is based on maximum removal of atretic plate and exposure of surrounding structures with mucosal preservation. Its advantages include excellent magnified visualization, minimally invasive procedure, less surrounding damage, less blood loss, less recovery period and high success rate.

We have used only endoscopic transnasal approach aided with microdebrider blades / burrs in all our cases. The main principle in bilateral cases was to create a uni-neochoana by performing posterior septectomy (Fig 2). Milind Navalakhe et al quote this step as one of the fundamental step in their surgery to prevent restenosis.¹⁶

Once the atresia repaired, almost every surgeon is made to face the problems of restenosis. It ranges between 0-85%.⁷ Our study showed 53.3% of restenosis after 1st surgery. Choanal atresia with larger bony component tends to have more restenosis due to increased neo-osteogenesis.¹⁷ Kim H et al indicated that the rate of restenosis was more in younger and smaller children due to their smaller nasal cavity and manipulation leading to formation of granulations or polyps easily.¹² This might be true in our study too for case number 11, who was operated at just 6D of life. Association with CHARGE syndrome tend to have effect on rate of restenosis following surgery, more so often if it has bilateral involvement and other anomalies¹⁰. In this study we could see the two unilateral involvement cases associated with CHARGE syndrome required just one intervention whereas for bilateral involvement cases required one revision surgery due to restenosis. One of the unilateral cases who underwent total of 3 surgeries had associated adenoid hypertrophy and hence underwent adenoidectomy also.

Mitomycin c, is a derivative of streptomyces bacteria which has an anti-proliferative property.¹² Its usage is controversial with few studies showing improved surgical outcomes when used whereas few fails to demonstrate it. In a study by Carter et al. concluded that there was reduction in restenosis rate with usage of topical mitomycin c.¹⁸ We used 0.4mg/ml of mitomycin c (diluting 2mg of mitomycin c in 5ml of sterile water) in all the cases. Individual benefits of mitomycin c could not be established in our study as there were no control groups.

Stenting of nasal airways is one of the various techniques used to reduce the restenosis. It is believed that during early post-operative period stenting was essential to stabilize the nasal airway. Proponents of placement of stent suggests doing so as it helps to keep the airway patent in early post operative period thus helping the child breath easily by facilitating the nasal pattern of breathing.^{1,7} Usage of soft materials gives better surgical outcome.⁷ We used nasopharyngeal airway as a stent after primary surgery for all cases. However, there are no clear-cut guidelines or consensus regarding whether to stent the airway post operatively or not. Durmaz et al in their meta-analysis study consisting of 238 cases from 20

studies failed to show any significance of using nasal stent.¹⁷ Eladl et al suggests reserving stenting for some selected cases with narrow choana after drilling, difficult follow up situations and patients with associated congenital anomalies. Placement of stent might cause more injury by irritating the mucosa, might act as nidus for infection, exert pressure to surrounding and some studies have suggested omission of stenting can reduce restenosis by 3 times.^{1,2,7,8} Keeping this in mind we avoided using nasal stent for revision cases. The improvement in techniques to operate using more precise instruments like microdebrider blades / burrs reduces restenosis and helps in better outcome of surgeries.

Samadi et al showed in their retrospective study that on an average 2.7 surgeries were needed for unilateral cases and around 4.9 surgeries for bilateral involvement to achieve complete nasal patency.⁷ In our study we required on an average 1.4 surgeries for unilateral cases and around 1.8 surgeries for bilateral cases to achieve full patency.

Conclusion

Choanal atresia is a rare congenital anomaly with female preponderance, affecting unilaterally more common than bilateral involvement. Unilateral cases mainly present with nasal obstruction and persistent nasal discharge, whereas bilateral cases tend to have severe respiratory distress demanding immediate intervention to restore the airway. They can also present with feeding difficulties and hence failure to thrive. Management of choanal atresia involves multi-disciplinary approach and preventing restenosis is a challenge. The timing of surgery mainly depends on the presenting clinical features of the child. Factors effecting the outcome of surgery are age and weight of the child, as bigger the child in size, wider the choanal arches can be opened with less post-operative scarring and restenosis. Bilateral cases associated with CHARGE syndrome has higher rate of restenosis following surgery. Transnasal endoscopic repair of choanal atresia using powered instruments and performing good posterior septectomy to create a uni neochoana prevents restenosis. Usage of nasopharyngeal airway as a stent in primary repair during

early post-operative period is essential to stabilize the nasal airway. Ours being a retrospective study, we recommend conducting further prospective study with more number of cases for better statistical conclusions.

References

1. Eladl HM, Khafagy YW. Endoscopic bilateral congenital choanal atresia repair of 112 cases, evolving concept and technical experience. *International journal of pediatric otorhinolaryngology*. 2016 Jun 1;85:40-5
2. Moreddu E, Rossi ME, Nicollas R, Triglia JM. Prognostic factors and management of patients with choanal atresia. *The Journal of pediatrics*. 2019 Jan 1;204:234-9
3. Kwong KM. Current updates on choanal atresia. *Frontiers in Pediatrics*. 2015 Jun 9;3:52
4. Wormald PJ, Zhao YC, Valdes CJ, Pacheco AE, Ha TN, Tewfik MA, Wabnitz D, Shaw CK. The endoscopic transseptal approach for choanal atresia repair. In *International forum of allergy & rhinology* 2016 Jun (Vol. 6, No. 6, pp. 654-660).
5. Kurosaka H. Choanal atresia and stenosis: Development and diseases of the nasal cavity. *Wiley Interdisciplinary Reviews: Developmental Biology*. 2019 Jan;8(1):e336
6. Gupta M, Kour C. Congenital bilateral choanal atresia: A rare case. *Journal of Rare Disorders: Diagnosis & Therapy*. 2017;3(2):9. DOI: 10.21767/2380-7245.100162
7. Saafan ME. Endoscopic management of congenital bilateral posterior choanal atresia: value of using stents. *European Archives of Oto-Rhino-Laryngology*. 2013 Jan;270(1):129-34. DOI 10.1007/s00405-012-1956-0
8. Ibrahim AA, Magdy EA, Hassab MH. Endoscopic choanoplasty without stenting for congenital choanal atresia repair. *International journal of pediatric otorhinolaryngology*. 2010 Feb 1;74(2):144-50
9. Newman JR, Harmon P, Shirley WP, Hill JS, Woolley AL, Wiatrak BJ. Operative management of choanal atresia: a 15-year experience. *JAMA Otolaryngology–Head & Neck Surgery*. 2013 Jan 1;139(1):71-5
10. Brihaye P, Delpierre I, De Villé A, Johansson AB, Biarent D, Mansbach AL. Comprehensive management of congenital choanal atresia. *International journal of pediatric otorhinolaryngology*. 2017 Jul 1;98:9-18
11. Moreddu E, Rizzi M, Adil E, Balakrishnan K, Chan K, Cheng A, Daniel SJ, de Alarcon A, Hart C, Hartnick C, Inglis A. International Pediatric Otolaryngology Group (IPOG) consensus recommendations: diagnosis, pre-operative, operative and post-operative pediatric choanal atresia care. *International journal of pediatric otorhinolaryngology*. 2019 Aug 1;123:151-5
12. Kim H, Park JH, Chung H, Han DH, Kim DY, Lee CH, Rhee CS. Clinical features and surgical outcomes of congenital choanal atresia: factors influencing success from 20-year review in an institute. *American journal of otolaryngology*. 2012 May 1;33(3):308-12
13. Manica D, Schweiger C, Netto CC, Kuhl G. Retrospective study of a series of choanal atresia patients. *International archives of otorhinolaryngology*. 2014;18:002-5. DOI <http://dx.doi.org/10.1055/s-0033-1358581>. ISSN 1809-9777
14. Ramsden JD, Campisi P, Forte V. Choanal atresia and choanal stenosis. *Otolaryngol Clin North Am* 2009;42(2):339–352
15. Burrow TA, Saal HM, de Alarcon A, Martin LJ, Cotton RT, Hopkin RJ. Characterization of congenital anomalies in individuals with choanal atresia. *Archives of Otolaryngology–Head & Neck Surgery*. 2009 Jun 1;135(6):543-7
16. Navalakhe M, Chhabria S, Gaikwad N, Dwivedi V. Endoscopic transnasal repair of bilateral Choanal Atresia in Neonates: our experience. *Int J Contemp Med Res*. 2019;6(11):K4-7
17. Ayari S, Abedipour D, Bossard D, Froehlich P. CT-assisted surgery in choanal atresia. *Acta oto-laryngologica*. 2004 May;124(4):502-4
18. Carter JM, Lawlor C, Guarisco JL. The efficacy of mitomycin and stenting in choanal atresia repair: a 20 year experience. *International journal of pediatric otorhinolaryngology*. 2014 Feb 1;78(2):307-11.