

Cat Scratch Disease: A Diagnostic Challenge in Cervical Lymphadenopathy

<https://doi.org/10.47210/bjohns.2023.v31i3.84>

Bipin Kishore Prasad,¹ Yamuna Ranganathan,² Gunjan Dwivedi,² Devika Gupta²

ABSTRACT

Introduction

Cat Scratch Disease typically manifests as long standing regional lymphadenopathy, though clinical features may cover a wide spectrum. Lack of definite history of cat scratch, atypical presentation, non-availability of serological tests and misleading needle cytology may often lead to delay in diagnosis.

Case Report

A 44 years old diabetic female, presented with persistent fever for 15 days followed by 4x4cm, tender tense swelling in left parotid region extending into upper neck. Her blood sugar was deranged. Polymorphonuclear leucocytosis was noted. Radiological investigation showed lymph nodal conglomeration involving level II, III and IV with non-enhancing necrotic areas within it. Mass was abutting Internal Jugular Vein, which was attenuated cranially. Aggressive antibiotics treatment and optimal glycemic control failed to resolve fever and lymphadenopathy, hence excision of neck mass was done which was reported histopathologically as Cat Scratch Disease.

Conclusion

While ruling out tuberculosis, Epstein Barr-Virus infection, acute bacterial lymphadenitis or malignant disease, Cat Scratch Disease should be included in the differential diagnosis of lymphadenopathies in head-neck region so that possibility of antibiotic abuse, an unnecessary biopsy, long term antitubercular drug therapy or even surgical treatment may be avoided.

Keywords

Cat Scratch Disease; *Bartonella henselae*; Lymphadenopathy; Serological Test

Cat Scratch Disease (CSD) is a disease characterized by self-limiting lymphadenopathy caused by *Bartonella henselae*.¹ *B. henselae* is a Gram-negative intracellular bacteria that is widely present in various mammals including cats, rodents and humans. They are transmitted mainly by direct contact such as animal scratches and bites, or by some arthropods such as sand flies, lice, fleas, biting flies, and ticks.² A typical patient of CSD is an immunocompetent individual who presents with a primary granulomatous skin lesion that develops 3–10 days after contact with an infected cat, followed by enlargement of the regional lymph nodes. Lymphadenopathy is the most common clinical manifestation of CSD occurring in more than 80% of all cases.³ Atypical presentation is seen in 5%–25% of all cases, with fever, multi-organ involvement with or without lymphadenopathy.⁴ Good clinical acumen and sound radiological back up may not overcome the diagnostic

dilemma of an Otorhinolaryngologist in cases of atypical manifestation till serology or histopathology clinches the diagnosis. One such case is reported for emphasizing its recognition in the differential diagnosis of cervical lymphadenitis.

Case report

A 44 years old female, known case of diabetes mellitus type II and hypothyroidism presented with persistent fever for 15 days followed by development of swelling in neck 3 days later.

Neck swelling was in the left parotid region extending

1 - Command Hospital (Central Command), Lucknow

2 - Command hospital (Eastern Command), Kolkata

Corresponding author:

Dr Bipin Kishore Prasad

email: bkp1405@gmail.com

into upper neck, 4x4cm in size, tender, tense and firm. She was hospitalized with the provisional diagnosis of Acute parotitis (left) and started on injectable antibiotics namely injection Amoxicillin 1000mg + Clavulanic acid 200mg 12 hourly intravenously and injection Metronidazole 500mg 8 hourly intravenously.

Her blood sugar was deranged. Polymorphonuclear leucocytosis was noted. Ultrasonography (USG) of neck showed a lymph nodal conglomeration involving level II, III and IV without cystic degeneration or hypervascularity. Contrast enhanced computed tomography (CECT) confirmed lymph nodal conglomeration of USG but also revealed non-enhancing necrotic areas within it. The mass was seen abutting and compressing Internal Jugular Vein, which was attenuated cranial to the mass. Subcentimetric mediastinal lymph nodes were also noted in CECT (Fig. 1).

Aggressive antibiotics treatment for a week and

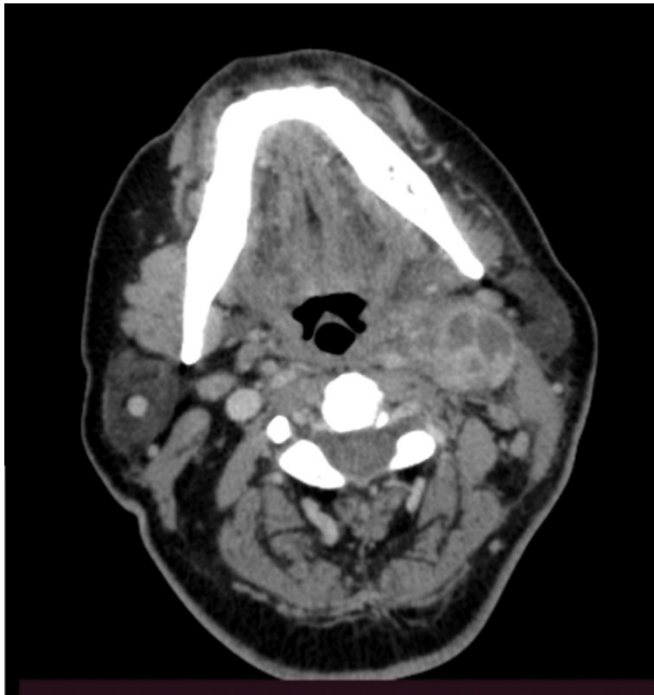

Fig.1. Non-enhancing lymph node conglomerate with areas of necrosis within abutting IJV

optimal glycemic control by insulin failed to resolve the fever and lymphadenopathy, hence excision of the glandular mass was done by carefully dissecting it out

from its adherence with Internal Jugular Vein (IJV) (Fig. 2).

Histopathology of the excised specimen was reported

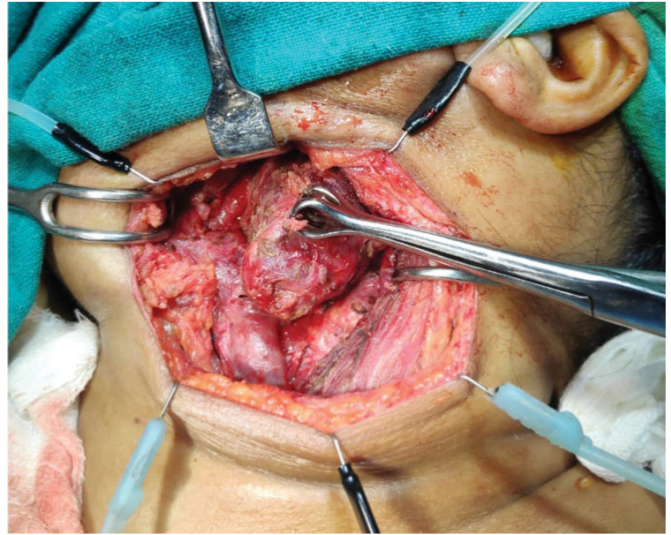


Fig. 2. The lymph node mass being excised

as Cat Scratch Disease (Fig. 3).

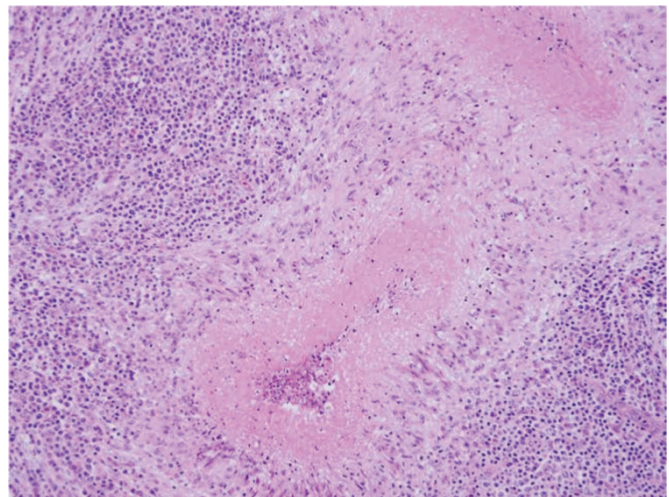


Fig. 3. H&E stain 40x Photomicrograph showing lymph node architecture distorted by multiple suppurative granulomas composed of central stellate necrotic area rimmed by palisading histiocytes

Discussion

Dr Robert Debre of Paris in 1947, found that a group of his patients had positive intradermal reaction to an antigen prepared by Dr Lee Foshay of Cincinnati, who in 1932 had already identified a sub-group of patients of suspected Tularemia whose illness followed a cat scratch⁵. Dr Debre published the first report of his cases in 1950. *Rochalimaea henselae* was identified as the etiologic pathogen in 1992.⁶ The microbe was later named *Bartonella henselae*.⁷

CSD is nowadays recognized as a global cosmopolitan disease, which is known to affect individuals without age or gender predilection. The awareness about the disease has led to its two broad clinical manifestation; typical and atypical. Typical presentation is where a small reddish papular rash develops 3-10 days after cat scratch, followed by a prolonged regional lymphadenopathy after another 14 days, with a self-limiting outcome within 2-4 months.⁸

The atypical variety of CSD has a broader clinical spectrum which includes fever, abdominal pain, multiregional lymphadenopathy and multiorgan involvement affecting the eyes, liver, spleen, central nervous system, skin and bones. CSD may also cause deep neck space infections and swelling of the parotid gland.^{9,10}

Diagnosis of CSD is made when at least two of the following three criteria are fulfilled: (1) Presence of clinical symptoms typical for CSD, (2) Serological detection of antibodies against *B. henselae* including negative serological results for other infectious diseases, (3) Detection of Bartonella DNA in extirpated lymph nodes or aspirated pus.⁸ Other diagnostic criteria are also adapted as suggested by Margileth AM¹¹ which include (a) cat contact history, (b) splenic micro-abscesses on CT scan, (c) positive IFA assay for *B. henselae* and (d) granulomatous inflammation of a lymph node. However, following the above two sets of criteria, it may be difficult to diagnose CSD in select cases where the history of contact with cat is not forthcoming, patient is immune compromised with atypical presentation of disease, serological testing is not available in the laboratory,

FNAC is inconclusive and radio-imaging fails to guide the clinician. Thus, the diagnosis of CSD in a case of cervical lymphadenopathy remains a challenge.

Case-to-case based approach is advocated where, firstly, serious illnesses such as malignancy or infectious diseases, especially Tuberculosis (TB), Epstein Bar Virus (EBV), cytomegalovirus (CMV), toxoplasma, staphylococcus and streptococcus should be actively excluded. Secondly, low density lesions in the lymph nodes, liver and spleen in USG or CT scan should be looked for and given due respect so as to perform early serology for *Bartonella henselae*. Thirdly, if serological testing is not available, one should not hesitate in excising the mass and subject the specimen to histopathological examination, microbiological test and molecular study to clinch the diagnosis.

Conclusion

While actively ruling out tuberculosis, Epstein Barr-Virus infection, acute bacterial lymphadenitis or a malignant disease, Cat Scratch Disease should be included in the differential diagnosis of lymphadenopathies in the head and neck region so that possibility of antibiotic abuse, an unnecessary biopsy, long term antitubercular drug therapy or even surgical treatment may be avoided.

References

1. Debre R. Cat scratch disease. *Mars Med.* 1950; 87:375-8
2. Deng H, Le Rhun D, Buffet JP, Cotte V, Read A, Birtles RJ, Vayssier-Taussat M. Strategies of exploitation of mammalian reservoirs by Bartonella species. *Vet Res.* 2012; 43:15. <https://doi.org/10.1186/1297-9716-43-15>
3. Carithers HA. Cat-scratch disease: an overview based on a study of 1,200 patients. *Am J Dis Child* 1985;139(11):1124-33 doi: 10.1001/archpedi.1985.02140130062031
4. Bourrillon A, Leclainche L. Cat scratch disease. Atypical forms. *Presse Medicale (Paris, France)* 1996; 25(10):503-7
5. Daniels WB, MacMurray FG. Cat scratch disease. Report of one hundred sixty cases. *JAMA* 1954; 154:1247-51
6. Regnery R, Olson J, Perkins B, Bibb W. Serological response to *Rochalimaea henselae* antigen in suspected cat-scratch disease. *Lancet* 1992;339: 1443-1445 doi: 10.1016/0140-6736(92)92032-b

7. Brenner, Don J., O'Connor, Steven P. Proposals to Unify the Genera *Bartonella* and *Rochalimae*, with descriptions of *Bartonella quintana* comb.nov., *Bartonella vinsoni* comb.nov., *Bartonella henselae* comb.nov., *Bartonella elizabethae* comb.nov. and to remove the family Bartonellaceae from the order Rickettsiales. *International Journal of Systematic Bacteriology* 1993; 43(4):777-86 doi: 10.1099/00207713-43-4-777
8. Cat-scratch disease: Otolaryngologic manifestations and management Ridder GJ, Boedeker CC, Technau-Ihling K, Sander A *Otolaryngol Head Neck Surg* 2005;132:353-8 doi: 10.1016/j.otohns.2004.09.019
9. Ridder GJ, Richter B, Disko U, Sander A. Gray-scale sonographic evaluation of cervical lymphadenopathy in cat-scratch disease. *J Clin Ultrasound* 2001; 29(3):140-5 doi: 10.1002/1097-0096(200103/04)29:3<140::aid-jcu1013>3.0.co;2-r
10. Ridder GJ, Richter B, Laszig R, Sander A. Cat-scratch disease in the parotid gland: a challenge in differential diagnosis. *Laryngorhinootologie* 2000; 79(8):471-7 doi: 10.1055/s-2000-5906
11. Margileth AM. Recent advances in diagnosis and treatment of cat scratch disease. *Curr Infect Dis Rep.* 2000; 2(2):141-6 doi: 10.1007/s11908-000-0026-8.