

# Squamous Cell Carcinoma of Nasofacial Groove

<https://doi.org/10.47210/bjohns.2023.v3i3.86>

Tamajit Sau,<sup>1</sup> Saumitra Kumar,<sup>1</sup> Ankita Atin Mukherjee,<sup>1</sup> Debalina Mazumdar<sup>1</sup>

## ABSTRACT

### Introduction

Cutaneous squamous cell carcinoma is a malignant tumour that develops in the squamous cells that make up the middle and outer layers of the skin. It often forms on parts of skin frequently exposed to sunlight. It is usually not life-threatening, though it can be aggressive causing serious complications. However, nasofacial groove is a very uncommon area for the origin of squamous cell carcinoma.

### Case Report

A 65-year-old housewife with hypertension and type 2 Diabetes Mellitus presented with painless swelling in the right nasofacial groove for last 5 months which was insidious in onset, gradually progressive to reach the present size. There were no aggravating or relieving factors. On clinical examination, oval, localized, non-tender, hard 2cm x 2cm swelling was found in right nasofacial groove. Diagnostic nasal endoscopy was within normal limit. Computed Tomography showed a well-defined heterogenous oval mass over the right maxilla extending to right nasofacial region. Aspiration cytology of lesion yielded a few round to oval epithelial cells and fibrous stroma in a haemorrhagic background. A provisional diagnosis of appendageal tumour of nasofacial groove was made. Surgical excision of the lesion was done under general anaesthesia. Gross examination of the excised lesion showed predominantly solid and grey mass. Microscopically the lesion showed features of moderately differentiated squamous cell carcinoma. Further Total Maxillectomy with Modified Radical Neck Dissection type 3 has been done.

### Discussion

Squamous cell carcinoma of the skin may mimic nasolabial cyst. Hence the diagnosis should be kept in mind while dealing with a suspicious case of nasolabial cyst.

### Keywords

Squamous Cell Carcinoma; Nasofacial Groove; Midface Swelling; Epidermal Keratinocytes

Squamous cell carcinoma is a malignant tumour of epidermal keratinocytes that invades the dermis.<sup>1</sup> This cancer usually occurs in sun-exposed areas. Local destruction may be extensive and metastases occur in advanced stages.<sup>2</sup> It comprises 90% of all Head and Neck cancers. Its incidence is 11.2 per 100,000 and its rate is significantly higher among men than women.<sup>1</sup> They appear mostly after the age of 50 years.<sup>3</sup> Surgical removal is curative.<sup>4</sup>

This paper describes a case of squamous cell carcinoma in the nasofacial groove which presented as a painless, oval swelling over the right maxilla. The lesion

was approached by lateral rhinotomy incision and was completely resected. No such case of squamous cell carcinoma in nasofacial groove has been reported till now. The case is reported for its rarity of location and its ability to masquerade other benign lesions like appendageal tumours and nasolabial cysts, as in our case.

1 - College Of Medicine & J.N.M Hospital, Kalyani, West Bengal

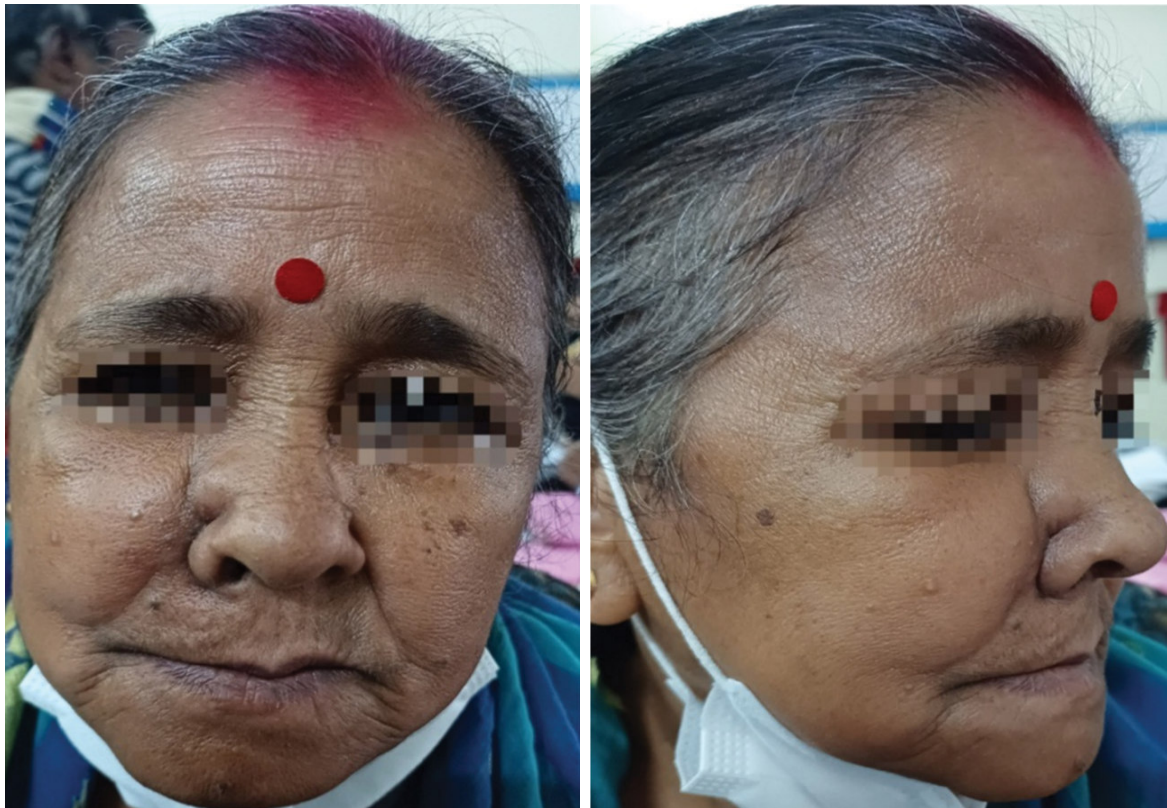### Corresponding author:

Dr. Tamajit Sau  
email: tamajitsau@gmail.com

### Case Report

A 65-year-old housewife with hypertension and type 2 Diabetes Mellitus presented with a painless swelling over right side of face for last 5 months which was insidious in onset, gradually progressive to reach the present size. There were no aggravating or relieving factors. There was no paresthesia over the swelling. On clinical examination, localized, oval, 2cm x 2cm swelling over right maxilla extending from 0.5cm lateral to ala of nose along the lateral aspect of nasofacial groove, superiorly 2 cm below the infraorbital margin (Figure 1). Nasofacial groove was partially obliterated. The overlying skin appeared stretched and tensed with no punctum or ulceration. It was non-tender, hard in consistency, non-

mobile, not fixed to the skin with smooth surface and ill-defined margins. The skin was pinchable over the lesion. Intra-oral and anterior rhinoscopy examination were normal and did not reveal any swelling. Diagnostic nasal endoscopy was within normal limit. There was no proptosis and vision was normal. The cervical lymph nodes were not palpable. However, patient had a history of taking smokeless tobacco for last 8 years. No significant past, allergic or drug history. Overall clinical presentation was suggestive of a benign subdermal lesion with differential diagnosis of nasolabial cyst, ossifying fibroma, epidermoid cyst, neurogenic tumour, trichoepithelioma, sebaceous hyperplasia, infra-orbital nerve schwannoma.



**Fig. 1. Lesion presenting as subdermal nodular swelling**

Computed Tomography (CT) Scan was advised to study the nature, size and extent of the lesion in relation to right maxilla. It revealed a well-defined heterogenous oval mass over the right maxilla which was extending to

right nasofacial region. There was no evidence of bony erosion or extension of mass into maxillary sinus, nasal cavity or oral cavity.

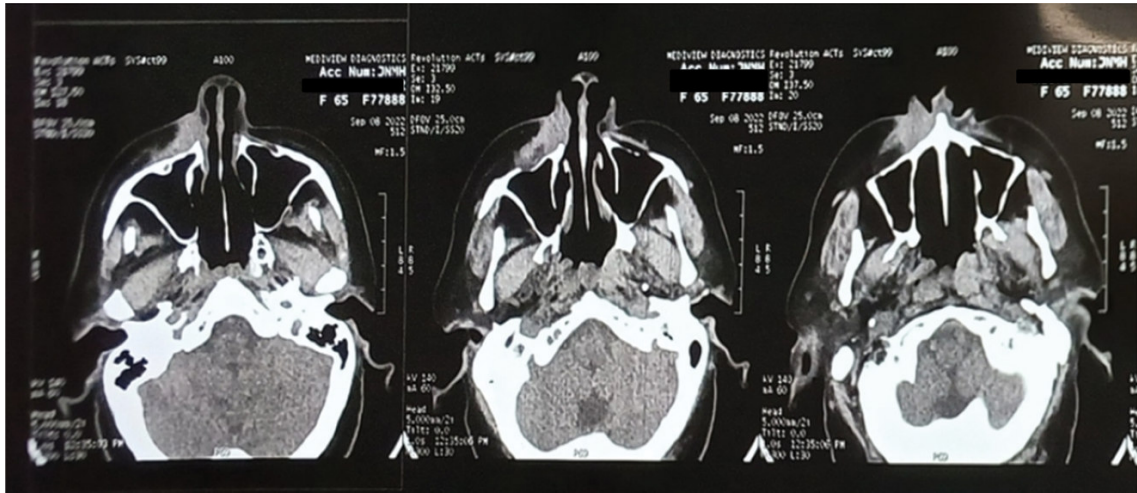


Fig. 2. CT-Scan showing a heterogeneous oval mass over right maxilla

Fine Needle Aspiration Cytology (FNAC) of lesion showed a few round to oval epithelial cells and fibrous stroma in a haemorrhagic background.

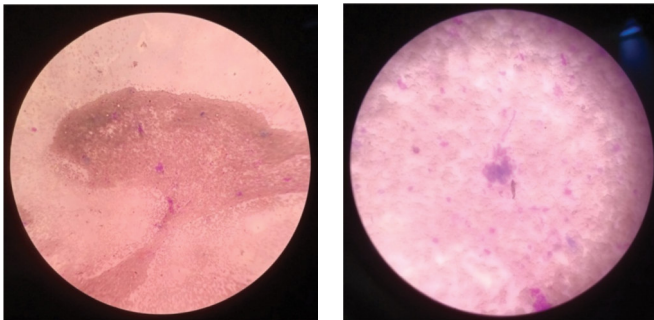


Fig. 3. H & E-stained section of FNAC slides at 10X magnification

A provisional diagnosis of Appendageal tumour in the nasofacial groove was made.

Surgical excision of the lesion was planned under general anaesthesia. After infiltrating adequately with sterile water and adrenaline, Lateral rhinotomy incision (Moure's approach) was made. Skin flap was elevated, tumour was identified and separated off its margins. Oncological safe margins were not ensured since we did not suspect malignancy. The lesion was not connected to nasal mucosa or skin in the nasofacial groove. Haemostasis was achieved and wound closed in two

layers. Patient withstood the procedure well. Post operatively patient did not experience any paresthesia over right cheek.

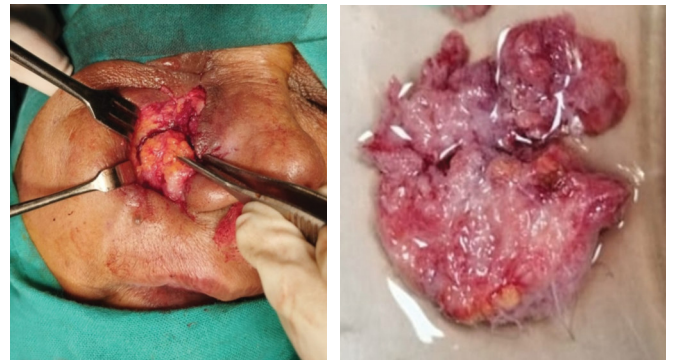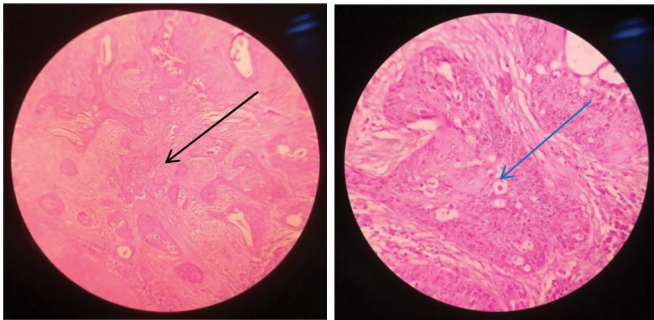


Fig. 4. Lateral rhinotomy incision with skin flap elevation, tumour not attached with nasal mucosa or skin (A), Excised tumour (B)

Histopathological examination of the excised lesion showed grossly solid and grey mass. Microscopically the lesion showed features of moderately differentiated squamous cell carcinoma. Infiltration of muscle by the tumour is also noted.

This sudden diagnosis of invasive malignancy obviated the need for radical surgery with wide local excision of the tumour bed along with elective neck dissection. Hence Total Maxillectomy with Modified Radical Neck





HPE Slide (Low Power)

HPE Slide (High Power)

**Fig. 5. H & E-stained section of excised specimen at 40X magnification showing squamous cells (black arrow) & mitotic figures (blue arrow)**

Dissection type 3 was done at another centre but the patient died in the immediate post-operative period.

### Discussion

Squamous cell carcinoma (SCC) is a non-melanoma skin cancer characterized by malignant proliferation of epidermal keratinocytes and is the second most common skin cancer after basal cell carcinoma (BCC).<sup>5</sup> Based on epidemiological data, the incidence of SCC has increased in the last thirty years. Squamous cell carcinoma in the nasofacial groove is extremely rare.<sup>6,7</sup> To the best of our knowledge, no such case of SCC in nasofacial groove has been reported till now in English medical literature. Squamous cell carcinoma generally presents as slow-growing, painless swelling.<sup>1</sup>

It may be located within the face at different sites. Squamous cell carcinoma is caused by the cumulative exposure of skin to UV light.<sup>1</sup> However, in our case, it was a well-localised, painless, mid-face, subdermal swelling without any ocular, nasal, oral lesions or involvement of underlying osseous skeleton.

It is rare for squamous cell carcinomas to present with numbness which tally with our case with no paresthesia experienced.<sup>8</sup>

Fine Needle Aspiration Cytology (FNAC), Ultrasonography, Magnetic resonance imaging (MRI) and Computed Tomography (CT) images are diagnostic tools for Squamous cell carcinoma. FNAC has a diagnostic accuracy of 84% and is characterised by the presence

of round to oval epithelial cells with scant cytoplasm and high N:C ratio.<sup>9</sup>

The treatment of squamous cell carcinomas is surgical and the approach depends on the extent and location of the tumour. In our case, we did lateral rhinotomy or Moure's approach. Since the clinical presentation and pre-op FNAC did not suggest malignancy, we removed only the tumour and didn't ensure oncological safe margins. Other approaches used include Caldwell-Luc approach for tumour within the maxillary sinus, Sub-ciliary or eyelid crease incision, Weber Ferguson incision combined with osteotomy for larger lesions.<sup>13</sup>

While malignant, squamous cell carcinomas are unlikely to spread to other parts of the body if treated early.<sup>10</sup> They may be locally disfiguring if not treated early.<sup>11,12</sup> Its recurrence rate is 15% to 50%.<sup>13</sup> In our patient we were successful in achieving timely and complete excision of the tumour. But we could not take adequate surgical margins around the tumour due to ignorance of its malignant nature.

On Post-operative follow up, patient underwent PET-CT scan (Positron Emission Tomography and Computed Tomography). No distant metastasis was detected. She underwent Total Maxillectomy with elective Modified Radical Neck Dissection type 3 but unfortunately expired 3 days post-operation.

### Conclusion

Incidence of Squamous cell carcinoma in the nasofacial groove is very low making it difficult to diagnose. It is rare for a Squamous cell carcinoma to arise denovo in connective tissue planes. It is possible to have a Squamous cell carcinoma not connected to nasal mucosa or skin in the nasofacial groove - along embryologic fusion lines. This is a distinct possibility in our case. Hence, Squamous cell carcinoma in the nasofacial groove may be included in the differential diagnosis of a localised subdermal mid-face swelling.

### References

1. Lonsdorf A, Hadaschik E. Squamous cell carcinoma and keratoachantoma. In: Kang S, Amagai M, Bruckner A, Enk A,

- Margolis D, McMichael A, editors. Fitzpatrick's Dermatology. 9 ed. New York: McGraw-Hill; 2019:1901–1919
2. Stratigos AJ, Garbe C, Dessinioti C, et al. European interdisciplinary guideline on invasive squamous cell carcinoma of the skin: part 2. Treatment. *Eur J Cancer*. 2020;128:83–102. doi: 10.1016/j.ejca.2020.01.008
  3. Que SKT, Zwald FO, Schmults CD. Cutaneous squamous cell carcinoma: incidence, risk factors, diagnosis, and staging. *J Am Acad Dermatol*. 2018;78(2):237–247
  4. Burton KA, Ashack KA, Khachemoune A. Cutaneous squamous cell carcinoma: a review of high-risk and metastatic disease. *Am J Clin Dermatol*. 2016;17(5):491–508
  5. Maru GB, Gandhi K, Ramchandani A, Kumar G. The role of inflammation in skin cancer. *Inflammation Cancer*. 2014;1:437–469
  6. Green AC, Olsen C. Cutaneous squamous cell carcinoma: an epidemiological review. *Br J Dermatol*. 2017;177(2):373–381
  7. Firnhaber JM. Diagnosis and treatment of basal cell and squamous cell carcinoma. *Am Fam Physician*. 2012;86(2):161–168
  8. Gupta G, Madan V, Lear J. Squamous cell carcinoma and its precursor. In: Griffiths C, Barker J, Bleiker T, Chalmers R, Creamer D, editors. *Rook's Textbook of Dermatology*. New Jersey: John Wiley & Sons; 2016:p.142.1 -.40
  9. Badash I, Shauly O, Lui CG, Gould DJ, Patel KM. Nonmelanoma facial skin cancer: a review of diagnostic strategies, surgical treatment, and reconstructive techniques. *Clin Med Insights Ear, Nose Throat*. 2019;12:1179550619865278
  10. Samarasinghe V, Madan V, Lear JT. Management of high-risk squamous cell carcinoma of the skin. *Expert Rev Anticancer Ther*. 2011;11(5):763–769. doi: 10.1586/era.11.36
  11. Brodland DG, Zitelli JA. Surgical margins for excision of primary cutaneous squamous cell carcinoma. *J Am Acad Dermatol*. 1992;27(2):241–248. doi: 10.1016/0190-9622(92)70178-I
  12. Cherpelis BS, Marcusen C, Lang PG. Prognostic factors for metastasis in squamous cell carcinoma of the skin. *Dermatol Surg*. 2002;28(3):268–273. doi: 10.1046/j.1524-4725.2002.01169.x
  13. Sutedja EK, Yuliasari R, Rizki KA, Sutedja E. A Large Squamous Cell Carcinoma on the Face Treated with Wide Excision and Defect Closure Using Forehead Flap Reconstruction. *Clin Cosmet Investig Dermatol*. 2022 May 16;15:895-901. doi: 10.2147/CCID.S360744.