

Surgical Management of Tracheocutaneous Fistula in Paediatric Population

<https://doi.org/10.47210/bjohns.2025.v33i1.180>

Bincy Joseph,¹ Prem Kumar P,¹ Sahana Raju,¹ Satish Kumar K¹

ABSTRACT

Introduction

Persistent tracheocutaneous fistula (TCF) is a complication of prolonged use of tracheostomy tube. Although many procedures exist to correct this issue, there is no consensus regarding its optimal management. We seek to review the outcome of TCF closure in pediatric population by primary closure and adjuvant application of fibrin glue.

Materials and Methods

Upon retrospectively reviewing our hospital's records, we identified twelve children who underwent surgical repair of tracheocutaneous fistula through primary closure and adjuvant fibrin glue application between January 2019 and January 2023. We collected pertinent data related to their cases.

Results

We identified 7 male and 5 female patients. The mean duration of tracheostomy dependence was 19.52 months, and the mean time from decannulation to surgical closure was 9.29 months. All patients underwent primary closure with the adjuvant application of fibrin glue. There were no perioperative mortalities or morbidities, except for one patient who developed a minor wound infection.

Conclusion

The closure of a tracheocutaneous fistula by primary closure and application of fibrin glue is safe and effective and can allow for shorter hospital stays in children with persistent TCF.

Keywords

Tracheostomy; Decannulation; Tracheocutaneous Fistula; Fibrin Glue

Tracheostomy is a commonly performed surgical procedure for airway management in children. It is estimated to be performed in about < 3% of ICU patients among tertiary pediatric hospitals.¹ Over the past few decades, there has been a significant shift in the reasons for pediatric tracheostomy. Advances in immunization strategies and the use of endotracheal intubation for respiratory support have led to a reduced frequency of tracheostomy for acute infections. Instead, the majority of pediatric tracheostomies are now carried out to address chronic conditions, such as prolonged respiratory insufficiency, congenital malformations, and neuromuscular disorders. Tracheostomies are now more commonly performed in younger children to manage chronic conditions, as opposed to older children with acute illnesses. The prolonged cannulation periods required in these patients have been linked to increased rates of tracheocutaneous fistula (TCF) formation².

The formation of a TCF following tracheostomy decannulation may be due to incomplete closure of the tracheal stoma or breakdown of tissue during the healing process. Other factors that may increase the risk of TCF formation include poor wound healing, infection, tissue necrosis, or preexisting conditions that impair normal tissue repair. A persistent tracheocutaneous fistula (TCF) can result in significant morbidity due to recurring aspirations, subsequent respiratory infections, challenges in vocalization, ineffective coughing, skin irritation, cosmetic concerns, social acceptance issues, and an inability to

1 - Department of Pediatric Otorhinolaryngology, Indira Gandhi Institute of Child Health, Bangalore. Karnataka medical council

Corresponding author:

Dr Bincy Joseph
email: bincy46joseph@gmail.com

tolerate submersion. The significant morbidity that results from TCF formation occurs secondary to the squamous epithelium that lines the tracheostomy tract and prevents its closure. Persistent fistulas have been reported to occur between 6.2% and 52.2% of pediatric patients following tracheostomy decannulation^{1,2}.

Surgical closure is often considered in cases of persistent TCF, but the choice of method remains a subject of debate and vary based on otolaryngologist's preference. Surgical procedures for tracheocutaneous fistula closure can be associated with various complications, including subcutaneous emphysema, pneumomediastinum, pneumothorax, bleeding, respiratory distress, wound infection, and the need for readmission.³

Fibrin glue, a biological adhesive composed of fibrinogen, thrombin, and other clotting factors (such as aprotinin, factor 13, and calcium), which when combined lead to the last step of the clotting mechanism, resulting in the formation of a gel like clot. Fibrin glue has found extensive application in various surgical disciplines as a biological adhesive system for tissue adhesion or hemostasis⁴. For instance, Fiorelli et al⁵ documented its successful utilization in the repair of tracheal lacerations. Furthermore, it has been employed in procedures like Laryngotracheoplasty and laryngotracheal reconstruction⁶. The adjunct use of fibrin glue in the fistula tract may enhance healing and create a secure seal.

Materials and Methods

This retrospective case series study was approved by the institutional review board. Searching our hospital's medical records, we identified twelve children who had received TCF repairs between January 2019 and January 2023 at our hospital.

We collected and analyzed several clinically relevant variables, including age, sex, indication for tracheostomy, duration of tracheostomy dependence, timespan between decannulation to surgical closure, operative techniques, and hospital length of stay. All the surgeries were performed by the senior author. The decision to proceed with surgical closure was made if the fistula had been

present for six months or longer to allow time for the fistula to close spontaneously. In addition, the open fistula provides access for an emergency airway if one is needed.

Prior to TCF repair, laryngotracheo bronchoscopy was done to evaluate each patient's airway to ensure there were no tracheal abnormalities, such as tracheomalacia or granulation, that might need to be addressed before initiating surgery.

All the cases were performed under general anesthesia. An elliptical incision was made around the tracheocutaneous fistula site. The fistulous tract was dissected and divided. The tracheal end of the tract was closed horizontally using simple intermittent sutures with 4-0 vicryl. Fibrin glue was applied over the sutured stump to create an airtight seal. Normal saline was instilled into the surgical field, and positive pressure ventilation was applied to detect any leaks and ensure airtight closure. (figure 1-5). The wound was closed in multiple layers using 3-0 vicryl, including muscle, subcutaneous tissue, and skin, respectively. All children were extubated in the operating room, and ICU monitoring was conducted for 24 hours. After discharge, follow up appointments were scheduled for the 10th day, 1 month, and 1 year.

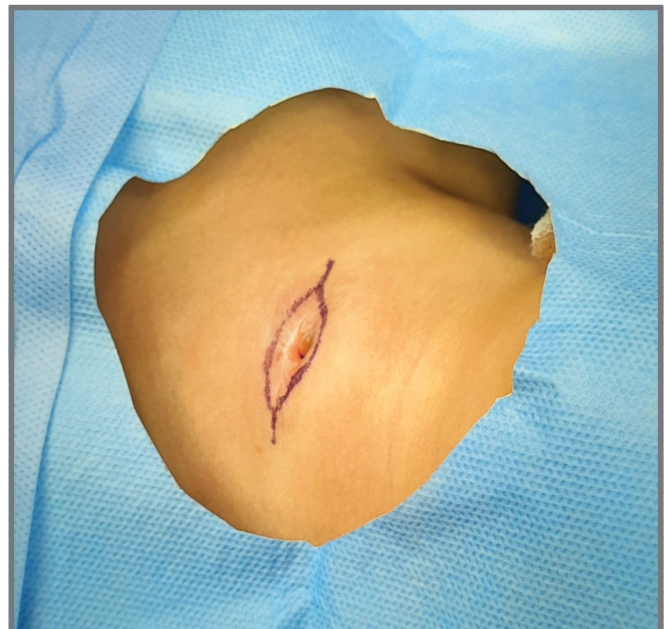

Fig. 1. Shows elliptical incision around the fistula.

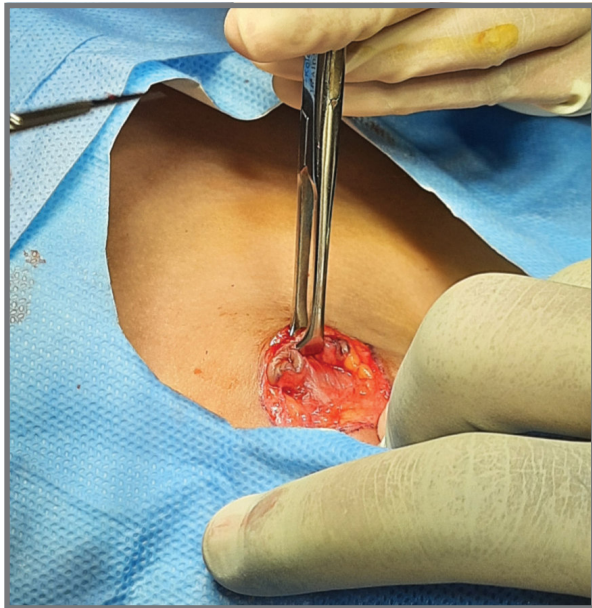


Fig. 2. Shows fistulous tract dissection

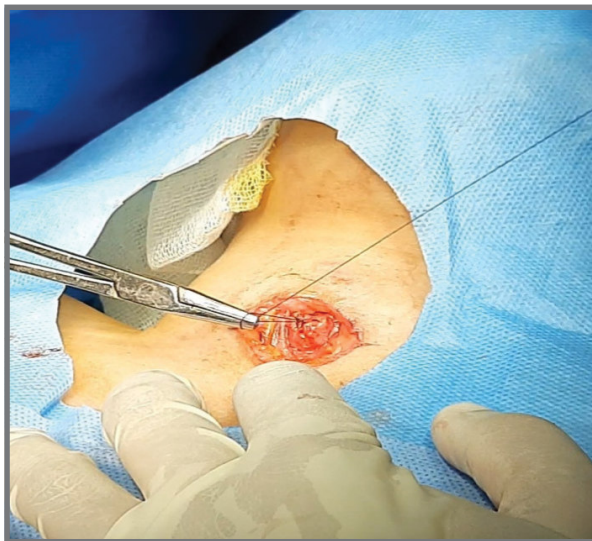


Fig. 3. Showing primary closure of The tracheal stump

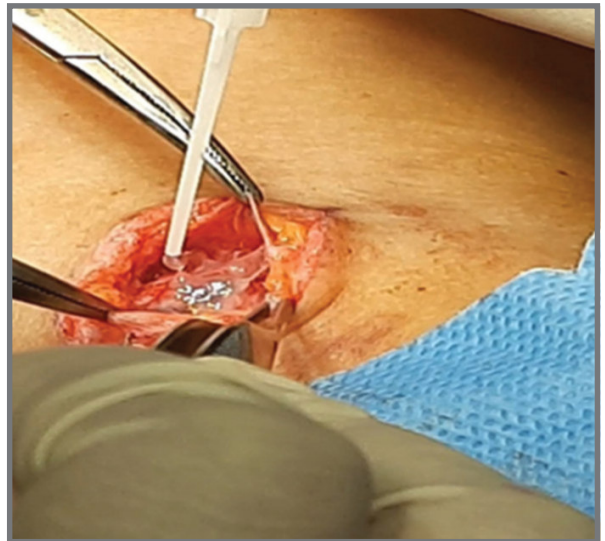


Fig. 4. Showing application of fibrin glue over closed stump

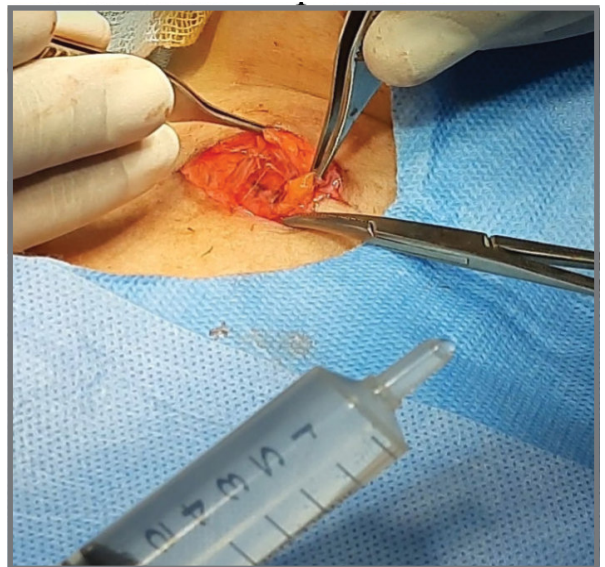


Fig. 5. Showing saline instillation and positive pressure ventilation.

Results

Twelve children with persistent tracheocutaneous fistula were identified consisting of Seven males and five females. The patient data are summarized in Table 1. The patients ranged in age from 3 to 17 years of age at the time of repair. The mean age at the initial tracheostomy was 2.29

years. The mean age at TCF closure was 6.65 years. The mean duration of tracheostomy was 19.52 months. The mean time from decannulation to TCF closure was 9.29 months.

The indications for the placement of the initial tracheostomy were neurological (n=7), respiratory (n=4), which required

prolonged mechanical ventilation, and one case was due to upper airway obstruction (n=1) caused by severe laryngomalacia. There was no statistically significant relationship observed in gender, ethnicity, or the indication for tracheostomy concerning persistent fistula formation.

A laryngotracheobronchoscopy was done before the surgery to assess suprastomal granulations or obstructions, aiding in the identification and preoperative resolution of any identified issues. No patient required postoperative

intubation after fistula closure. All the children were discharged home after 48 hours of observation.

During the follow-up period, there were no surgery related complications or incomplete closures of TCF. All patients had uneventful recoveries, except for one who developed a mild wound infection. This infection was treated with oral and topical antibiotics for five days, and the patient recovered well without any further issues.

Table I: Characteristics of study population

SI. NO	AGE (YEARS)	GENDER	INDICATION FOR TRACHEOSTOMY	DURATION OF TRACHEOSTOMY. MONTHS	TIME SPAN BETWEEN DECANNULATION TO SURGERY. MONTHS	FOLLOW UP CONDITION
1	3.2	M	GDD, Spastic QP, with aspiration pneumonia	10	6	normal
2	7	M	Phenylketonuria with seizures status post neurosurgery	17	6	normal
3	17	F	Neuro-cysticercosis, status epilepticus	6	10	normal
4	5.5	F	Covid MISC, ARDS	10	9	normal
5	4	M	Viral encephalitis	8	15	normal
6	4	F	Severe pneumonia	37	8	Wound infection
7	5	F	Seizure disorder, HIE	26	10	normal
8	10	M	Febrile encephalopathy	9	9	normal
9	8	M	Transverse myelitis	48	8	normal
10	5	M	Severe pneumonia	60	19	normal
11	14	M	Febrile encephalopathy	20	13	normal
12	8	M	Severe laryngomalacia	75	6	normal

Discussion

Many children who undergo tracheostomy placement will eventually experience decannulation. Following decannulation, stoma sites may either close naturally or require surgical closure. Persistent TCF after tracheostomy decannulation is a recognized sequela of long-term tracheostomy. The incidence of fistula formation is related to the duration of cannulation. Kulber et al⁷ reported that a fistula does not develop when cannulation is less than 16 weeks, but incidence increases to 70% when the cannulation period is greater than 16 weeks. In our study the minimum duration of cannulation was 6 months, and the mean duration of cannulation was 19.52 months. A persistent fistula hinders the accumulation of subglottic pressure necessary for effective vocalization, safeguarding the airway during swallowing, and generating a functional cough. Furthermore, the fistula can have cosmetic concerns and may be socially undesirable. It often results in mucoid discharge, which can lead to clothing stains and irritation of the adjacent skin. Additionally, children with persistent fistula are unable to swim due to the risk of aspiration. Hence, there is a clear medical indication for the surgical closure of the fistula.

A wide range of surgical techniques have been employed to close a TCF. Our literature review revealed various methods including simple cauterization,⁸ multilayered closure using skin flaps and muscle flaps,⁹ primary closure over a drain, excision of the tracheocutaneous fistula and healing by secondary intent,¹⁰ and partial fistulectomy with multilayered closure.¹¹ While primary closure yields a more favourable cosmetic outcome, there is some debate regarding its safety. The primary concern is the development of subcutaneous emphysema, pneumo-mediastinum, pneumothorax, and resultant respiratory distress.¹¹

Fibrin glue (also known as fibrin sealant) is a biodegradable, biocompatible hemostatic agent used to promote tissue adhesion and wound healing. It mimics the final stages of the coagulation cascade to create a fibrin clot that seals tissue defects.

Fibrin glue consists of two primary components:

- Fibrinogen (combined with Factor XIII and aprotinin or another antifibrinolytic agent)
- Thrombin (combined with calcium chloride)

When these two components are mixed and applied to the surgically closed fistulous tracheal stump, thrombin converts fibrinogen into fibrin monomers, which then polymerize to form a stable fibrin clot ensuring an airtight seal. Factor XIII cross-links the fibrin strands, further strengthening the clot and enhancing tissue adhesion. The fibrin matrix serves as a scaffold for fibroblasts, endothelial cells, and mesenchymal cells, promoting tissue regeneration. The presence of fibronectin in the fibrin clot enhances cell adhesion and migration, leading to epithelialization and help in the healing of the fistula tract. Over time, collagen deposition and fibroblast proliferation replace the fibrin clot with native tissue, leading to permanent closure. The antifibrinolytic agent (e.g., aprotinin) prevents premature degradation of the clot, allowing sufficient time for tissue healing.

Our method of employing primary fistula closure, combined with the application of fibrin glue, has significantly reduced the incidence of complications. Further reducing the likelihood of such complications is the multilayered closure of the strap muscles, subcutaneous tissue, and skin. The pre-procedure laryngotracheobronchoscopy, conducted to assess stomal granulation tissue and other potential obstructions, has contributed to an enhanced success rate by identifying cases with such issues and allowing for potential delays. We took additional precautions, including irrigating the closed wound under positive pressure ventilation to detect any air leaks and admitting the patient to the ICU for 24 hours of observation.

None of the children experienced postoperative respiratory distress, and no postoperative intubation was required. There was only one instance of minor wound infection occurring ten days after the surgery, which responded well to antibiotics and appropriate wound care, healing within five days. Notably, all the children treated with this technique achieved complete closure of their fistula tract.

Conclusion

A tracheocutaneous fistula is a sequela of long term tracheostomy. The failure of spontaneous obliteration of a tracheocutaneous fistula may necessitate surgical closure. The optimal technique for treating TCF has been a subject of debate and varies among hospitals. Our method of Fistulectomy, involving primary closure of the tracheal end using horizontal intermittent sutures, followed by the application of fibrin glue to ensure a tight seal, along with multilayered closure of muscles, subcutaneous tissue, and skin, appears to be a promising treatment approach for closing a persistent tracheocutaneous fistula.

References

1. Watters KF. Tracheostomy in infants and children. *Respir Care*. 2017;62(6):799-825
2. Wisniewski BL, Jensen EL, Prager JD, Wine TM, Baker CD. Pediatric tracheocutaneous fistula closure following tracheostomy decannulation. *Int J Pediatr Otorhinolaryngol*. 2019;125:122-7
3. White A, Smitheringale A. Treatment of tracheocutaneous fistulae in children. *J Otolaryngol*. 1989;18(1):49-52
4. Schneider G. Tissue adhesives in otorhinolaryngology. *GMS Curr Top Otorhinolaryngol Head Neck Surg*. 2009;8:Doc07
5. Fiorelli A, Cascone R, Di Natale D, Pierdiluca M, Mastromarino R, Natale G, De Ruberto E, Messina G, Vicidomini G, Santini M. Endoscopic treatment with fibrin glue of post-intubation tracheal laceration. *J Vis Surg*. 2017;3:102
6. Monnier P. Pediatric airway surgery: management of laryngotracheal stenosis in infants and children. Berlin: Springer Science & Business Media; 2010
7. Kulber H, Passy V. Tracheostomy closure and scar revisions. *Arch Otolaryngol*. 1972;96(1):22-6
8. Eaton DA, Brown OE, Parry D. Simple technique for tracheocutaneous fistula closure in the pediatric population. *Ann Otol Rhinol Laryngol*. 2003;112(1):17-9
9. Tatekawa Y, Yamanaka H, Hasegawa T. Closure of a tracheocutaneous fistula by two hinged turnover skin flaps and a muscle flap: a case report. *Int J Surg Case Rep*. 2013;4(2):170-4
10. Wine TM, Simons JP, Mehta DK. Comparison of 2 techniques of tracheocutaneous fistula closure: analysis of outcomes and health care use. *JAMA Otolaryngol Head Neck Surg*. 2014;140(3):237-42
11. Schroeder JW Jr, Greene RM, Holinger LD. Primary closure of persistent tracheocutaneous fistula in pediatric patients. *J Pediatr Surg*. 2008;43(10):17