

# Does Anterior Tunnelling Really Help in Underlay Type I Tympanoplasty?

Sohag Kundu,<sup>1</sup> Bhaskar Ghosh,<sup>1</sup> Bijan Kumar Adhikary,<sup>1</sup> Mainak Dutta<sup>1</sup>

## ABSTRACT

### **Introduction:**

Stabilizing the graft can be difficult with the conventional method of underlay tympanoplasty when the tympanic membrane perforation is subtotal, large or anteriorly placed with thin anterior rim. Tympanoplasty with anterior tunnelling has been tried to overcome this problem.

### **Materials and Methods**

A prospective study over two-year period was carried out with follow up for three months on 59 patients under two groups- the underlay tympanoplasty with anterior tunnelling and the conventional tympanoplasty with anterior tucking for comparison in terms of pre-and post-operative anatomical correction and physiological improvements

### **Results**

Follow up at 6 weeks and 12 weeks post operatively gives statistically comparable graft take up, hearing result and residual perforations.

### **Discussion**

Among various techniques of dealing with these types of perforations, statistical comparability of the two groups brings in an acceptability to this simple but satisfying procedure of the underlay tympanoplasty with anterior tunnelling.

### **Conclusion**

Underlay tympanoplasty technique (type-I) for subtotal, large or anteriorly placed perforations with thin anterior rim, can be managed by combining with anterior tunnelling which provides at least comparable results (if not more security against graft medialization) in respect of anatomical closure of perforations and hearing outcomes.

### **Keywords:**

Tympanoplasty; Anterior Tunnelling

All of us are aware of the uncertainty related to the postoperative results of tympanoplasty especially in large or subtotal perforations, which are prone to graft medialization, residual perforations or reperforations and lack of significant improvements in hearing.

This article provides a comparison between the anterior tunnelling technique of underlay tympanoplasty and the anterior tucking technique of conventional ones i.e. the underlay tympanoplasty with anterior tunnelling (ut+T) and the conventional tympanoplasty group with anterior tucking (ut+at), with regards to the graft uptake

rates and physiological restoration of hearing.

Underlay tympanoplasty with anterior tunnelling differs from conventional ones with anterior tucking in that the fascial flange is taken out through an anteriorly created tunnel over the antero-superior portion of the deep meatus adjacent to the drum annulus thereby providing additional support; whereas in conventional underlay tympanoplasty with anterior tucking the anterior end of the fascia is blindly placed beneath the anterior drum remnant supposedly over the deep meatal bony canal with gel foam support beneath medially.<sup>1</sup>

## Materials and Methods

Fifty-nine patients with inactive (for more than 3 weeks) large to subtotal or anteriorly placed central perforations (involving antero superior part of drum) with very minimal

*1 - Department of ENT, Medical College, Kolkata*

### **Corresponding author:**

Dr Bhaskar Ghosh

email: docgvas@gmail.com

anterior drum remnant were included in this prospective study where every alternate patient was distributed between the two cohorts under comparison. The patients had undergone underlay Type I tympanoplasty with anterior tunnelling or the conventional Type I tympanoplasty with anterior tucking, depending upon the group they belonged to.

The study population of 59 patients was further statistically compared in terms of demography, pre-and post-operative anatomical correction and physiological improvements. The patients were recruited during the two-year period from May 2014 to April 2016 and each patient was subsequently followed up for 3 months in the post-operative period.

Chronic otitis media with squamous disease, retraction pocket, cholesteatoma or marginal perforation or ears needing atticotomy/ mastoid exploration were excluded from the study, as also the cases of ossiculoplasty. Patient below twelve years of age or patients with bilateral perforations<sup>2</sup> were also excluded from the study.

*Preoperative evaluation* - Patients in the OPD presenting with COM were followed with proper elicitation of history, examination with otoscope and microscope, estimation of hearing with tuning-fork tests, pure tone audiometry at 0.5, 1, 2, and 3 kHz and assessment of nose and throat with rhinoscopy and indirect laryngoscopy accompanied by vestibular function tests and cranial nerve examinations, if needed. Lateral oblique x-ray of the mastoids and haematological investigations for pre-anaesthetic check-up were done next. High-resolution computed tomography of the temporal bones, tympanometry and occipito-mental view of paranasal sinuses were obtained in selected cases. Those fulfilling the criteria were put up for the study.

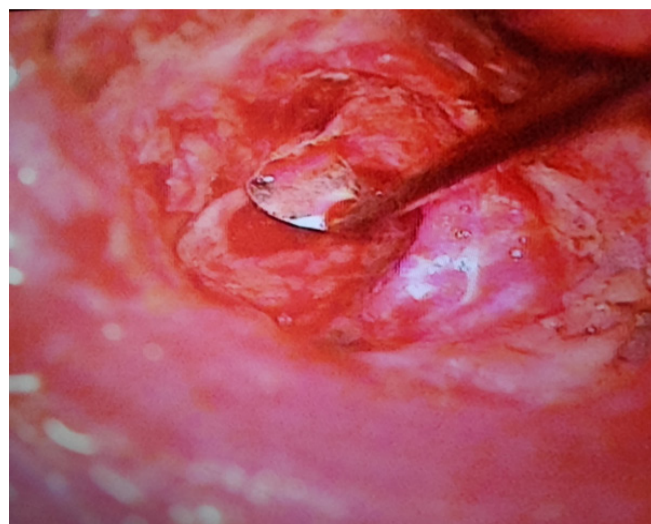
*Surgical technique* - After infiltration with 2% lidocaine with 1:200,000 adrenaline, all patients were operated through a post aural approach (Wilde's incision) by the same set of surgeons to gain surgical access after elevating a prior vascular strip end aurally.<sup>3</sup> After elevation of tympanomeatal flap and freshening of the margin, ossicular mobility and continuity were checked. In cases of an intact and mobile ossicular assembly and no evidence of squamous disease, patients

were subjected to randomization to either the underlay tympanoplasty with anterior tunnelling (ut+T) or the conventional tympanoplasty group with anterior tucking (ut+at) by allocating sequentially.

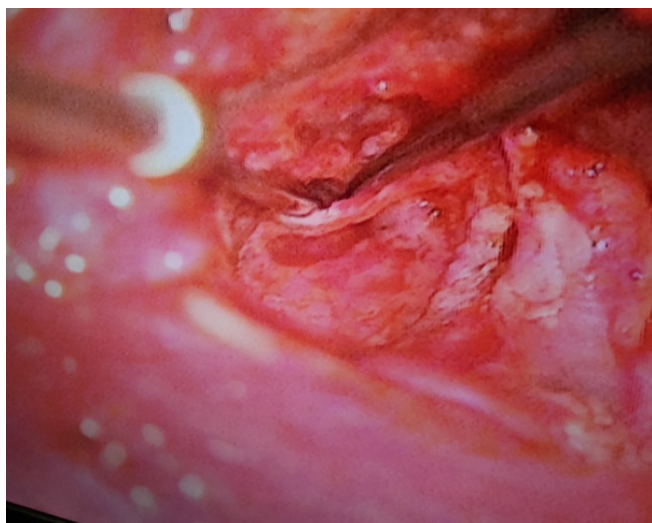
Temporalis fascia is harvested through the same incision line and wet temporalis fascia graft trimmed to approximately double the area of the perforation<sup>4</sup> was placed in an over-underlay fashion by placing the graft over the malleus and under the annulus.<sup>5</sup>

For the anterior tunnel group, a small horizontal incision about 3 mm in size (enough for passage of the tip of an alligator forceps and approximate the size of the diameter of a round knife) is placed, about one millimetre lateral to the annulus, in the antero superior portion of deep meatus and a suitable tunnel is created with the help of a round knife (Fig. 1) by medially elevating a small cuff of deep meatal skin along with the annulus along the anterior bony wall (starting at about one o'clock for the right ear and eleven o'clock for the left). The completion of the tunnel is judged by passing a curved needle through the tunnel into the anterior mesotympanum (Fig. 2). Through this tunnel, the tip of temporalis graft is pulled out with the aid of tip of micro suction cannula (Fig. 3) or an alligator forceps and the projection of graft is made to rest in between the skin cuff and meatal bony wall- (Fig. 4) and (Fig. 5 schematic).

For the conventional underlay tympanoplasty (type



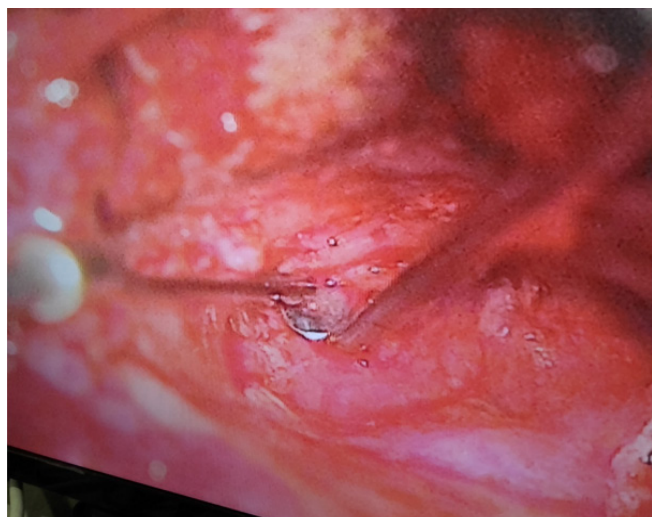
**Fig. 1. Incision for the tunnel- left ear**



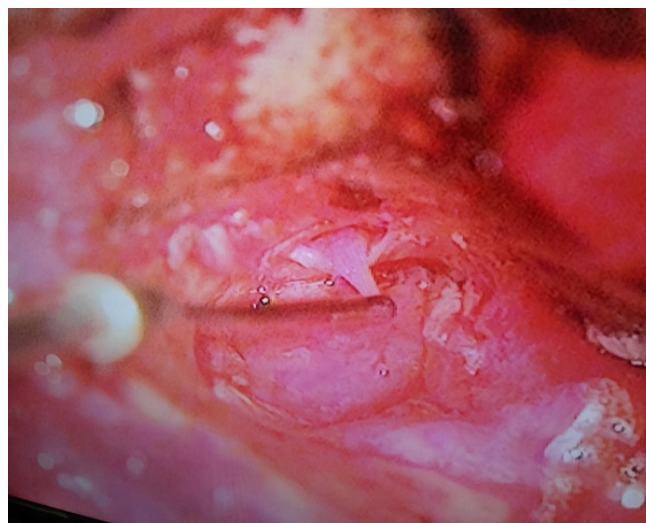**Fig. 2. Boring the tunnel and checking it with curved needle and suction tip**

I) anterior tucking is done by dislodging the anterior aspect of the annulus from the tympanic sulcus with a Cawthorne's knife and dragging it along with the anterior drum remnant laterally by scraping over the anterior deep bony meatal wall, thereby raising a miniscule flap for an amount deemed sufficient for tucking the anterior end of the fascial graft with the help of a flap repositor from the medial aspect of the graft, blindly. Middle ear and canal packing was done next with gel foams. Postural wound was closed in layers.

*Follow up* - Peri and postoperative cephalosporins were injected for 2 days; the aural pack was impregnated



**Fig. 4. Tucking the rest after closure of the tunnel**



**Fig. 3. Taking the fascial flange out through the tunnel**

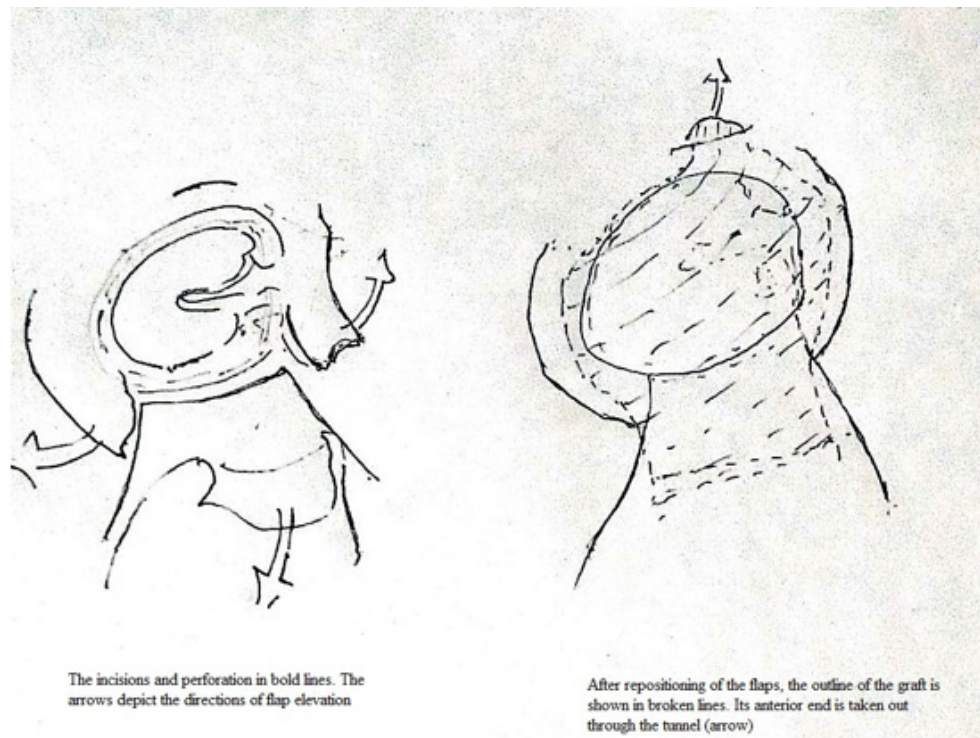
with framycetin. Removal of mastoid bandage, aural pack and stitches were done on the seventh postoperative day. Oral antibiotic coverage was continued for three weeks following operation. Gel foams were removed manually after two weeks and any remnant, with ofloxacin eardrop instillation for the next one week (canal toileting). Thus, patients were followed up weekly for the first three weeks. Primary surgical success was assessed by closure of anatomical gap. The patients were reassessed at sixth and twelfth weeks for proper epithelization and graft uptake, and hearing status respectively.

## Results

Initially 66 patients were selected for the study- 32 in the ut+at and 34 in ut+ tunnelling groups. (Table I) In the ut+at group 3 patients were lost to follow up at twelfth week. The attrition for the latter group is 4. Thus, the study was completed with 59 patients- 29 in ut+at, 30 in ut+T.

The ut+at group was made up of 12 males and 17 females, aged 20 to 50 years (mean: 30), and the ut+T comprised of 14 males and 16 females, aged 18 to 55 years (mean: 37). The two groups were thus more or less alike in terms of preoperative demographic variables.

At 6 weeks, residual or re-perforations were observed in 4 of the remaining 29 patients in the ut+at group and in 1 of the 30 in the ut+T group. Thus, the anatomic



**Fig. 5. Schematic diagram showing the essential steps of tympanoplasty with anterior tunnelling.**

success in the ut+at group was 86.2%, and that of the ut+T group, the success was found to be 96.67%. These results were not found to be statistically significant (p value 0.329 with Yate's correction,  $df=1$ , Chi square value=4.96).

No anterior canal blunting, canal wall sagging or granulation tissue were found in the two groups.

The average air bone gap closure within 30 dB at 6 weeks and 12 weeks show a rise of 10 % and 3% of effective study population respectively for the ut+T and ut+at group. The values, individually at 6 and 12 weeks, for these two groups are not statistically significant. (See Table I - p value 0.71 at 6 weeks, 0.365 at 12 weeks)

At 3 months, no significant differences in terms of pure tone average and gain were found between the two groups. No morphological changes were observed in the form of delayed graft failures, or retraction or thinning of neo tympanic membranes.

The failures with anterosuperior quadrant residual perforation in the ut+at group totalling 3, were caused by medial graft displacement. They were treated surgically

after a sufficient span of 6 months and on inability of Valsalva's manoeuvre to repose the graft. The one patient in the ut+T group, who developed a tiny perforation at 6 weeks, in the middle of the neotympanum, was managed with conservative TCA cautery.

### Discussion

The large or subtotal or anteriorly placed medium sized perforation usually pose a problem in that we can never be sure of the ultimate fate of graft uptake because of the precarious anatomical thin anterior margin which prevents a proper overlap of raw residual tympanic remnant with fascial graft as well as access to the bony deep meatal shelf margin in case where a large tympano meatal flap has to be elevated due to an anteriorly located perforation. Also, this prevents a proper support for the anterior most part of the graft which is often laid to rest against the lateral aspect of eustachian tube with medially placed gel foams in the protympanum. Medialisation of graft most often at antero-superior portion of perforation is not uncommon.

**Table I. Summary of the characteristics of the two groups of study populations pre-operatively, at 6 weeks and at 12 weeks**

PROCEDURES	UT+AT (UNDERLAY TYMPANOPLASTY TYPE-1+ ANTERIOR TUCKING)	UT+T (UNDERLAY TYMPANOPLASTY TYPE-1+ TUNNELLING)
N (total 66)	32	34
Attrition	3	4
Effective study population	29	30
Male: Female	12:17	14:16
Age range (Yrs)	20-50	18-55
Average Age (Yrs)	30	37
Av preop PTA value (dB)	33	35
Av post op PTA 6 weeks (dB)	30	29
Av post op PTA 12 weeks (dB)	26	27.5
Average ABg closure within 30 dB at 6 weeks	16 (55.17%)	18 (60%)
Average ABg closure within 30 dB at 12 weeks	17 (58.62%)	21 (70%)
Residual perforation at 6 weeks	4 (13.8%)	1 (3.33%)
Morphological changes in the neograft at 3 months	0	0

solve this problem. For anteriorly located small perforations a collar button suture<sup>6</sup> can be done by placing a small incision over the anterior drum remnant through which the tip of graft can be taken out like a collar button stud providing anchorage. But this is not possible in our scenario where the anteriorly located medium to large perforation bears a very minimal tympanic rim.

Over-Underlay technique, where graft is placed over handle of malleus, as has been carried out in this study, provides additional support to a large fascia in the subtotal perforations if done with finesse and preventing too much manipulation of handle of malleus.<sup>7</sup>

Circumferential sub annular grafting of Mokhtarinejad et al<sup>8</sup> where the annulus is elevated from sulcus tympanicus in the anterior segment for placement of the graft in between anterior annulus and anterior canal wall, which well-nigh mimics our conventional ut+at group, is another option if done with care to prevent anterior blunting. However, our ut+T group does away with this problem altogether as it requires very minimal raising of the annulus in the limited portion of the tunnel.

The superiorly based flap for anterior or subtotal perforations as described by Lee et al<sup>9</sup> is procedurally challenging with respect to ut+T.

In our study, placement of the graft, under vision, in the anterior canal wall, by drawing the anterior tip of the tongue shaped temporalis fascia through the tunnel created in the modified Underlay tympanoplasty type-1 with tunnelling, not only ensures graft anchorage in the anterior bony wall but also obviates the need of gel foam placement in the middle ear if the eustachian function is good.

The anatomic success as evinced by the graft take up rate at 3 months and the hearing at 3 months were statistically comparable for both ut+T group and ut+at group ; this is not only comparable to other studies of Ganguly et al, Gupta et al<sup>10, 11</sup> but the statistical comparability of the two groups brings in a new dimension to the problem of graft failure in large to subtotal perforations by shedding the inhibitions in accepting this simple but satisfying procedure of the underlay tympanoplasty with anterior tunnelling (ut+T).

Abbreviations: N- Number of patients, Av- Average, PTA- Pure Tone Average

## Conclusion

The Underlay tympanoplasty type-I with tunnelling is at least as effective if not better than the conventional underlay tympanoplasty type-I with anterior tucking, both in terms of anatomical as well as physiological dispositions as evinced from our present study. A larger sample size and a longer duration would have given a better idea but is left for futurity.

## References

1. Athanasiadis-Sismanis A. Tympanoplasty: tympanic membrane repair, p475-477 in: Gulya AJ, Minor LB, Poe D. Glasscock-Shambaugh Surgery of the Ear (6th Edition). Shelton, Ct.: People's Medical Publishing House-USA; 2010
2. Saha AK, Munsu DM, Ghosh SN. Evaluation of improvement of hearing in type I tympanoplasty & its influencing factors. *IJLO*. 2006;58(3):253-257
3. Vadiya SI, Shah SK, Chaudhary M. Comparison of canal wall incisions for tympanoplasty for large central perforations. *Indian J Otol*. 2015; 21:186-9
4. Merchant SN, Rosowski JJ, Shelton C. Reconstruction of the middle ear, p240 in: Ed Snow JB, Wackym PA. Ballenger's Otolaryngology Head and Neck Surgery (17th Edition). Shelton: PMPH USA, Ltd.; 2014
5. Kartush JM, Michaelides EM, Becvarovski Z, LaRouere MJ. Over under tympanoplasty. *Laryngoscope* 2002; 112:802-7
6. Poe SD. Perforations of the tympanic membrane. In: Ed Nadol JB, McKenna MJ. Surgery of the Ear and Temporal Bone (2nd edition). Philadelphia: Lippincott Williams and Wilkins; 2004
7. F. Fiorino, F Barbieri. 'Over-underlay' myringoplasty with umbo-anchor graft. *J Laryngol Otol*. 2008;122(8); 854-7
8. Mokhtarinejad F, Okhovat SA, Barzegar F. Surgical and hearing results of the circumferential sub annular grafting technique in tympanoplasty: A randomized clinical study. *Am J Otolaryngol*. 2012; 33:75-9
9. Lee HY, Auo HJ, Kang JM. Loop overlay tympanoplasty for anterior or subtotal perforations. *Auris Nasus Larynx* 2010; 37:162-6
10. Ganguly SN et al. Underlay tympanoplasty with tunnelling and placement of graft in anterior canal wall. *Journal of College of Medical Sciences-Nepal* 2011;7(4):44-47
11. Gupta S, Kalsotra P. Hearing gain in different types of tympanoplasties. *Indian J Otol*. 2013(19) Issue 4:186-193.