

Efficacy and Safety of Microdebrider Assisted Adenoidectomy over Conventional Adenoidectomy

Anil S Harugop,¹ Samanvaya Soni,¹ Tejaswini J S¹

ABSTRACT

Introduction

Adenoidectomy has conventionally been performed by curetting the adenoid tissue blindly with St. Clair Thompson curette leading to inadequate removal of tissue. Here the use of endoscopic guided adenoidectomy with microdebrider has been employed to compare the two methods.

Materials and Methods

It is a one-year randomized control trial conducted from January 2018 to December 2018. Patients were allocated into 2 groups i.e. conventional adenoidectomy and microdebrider adenoidectomy group. Pre and post-operative endoscopic grading of adenoid was compared and intraoperative blood loss and operative time were studied.

Results

Total 45 patients included 25 in conventional and 20 in microdebrider group. Following adenoidectomy operation the percentage of reduction of adenoid grading in microdebrider group was 63.79 % whereas 30.29% in conventional group, the average time taken by microdebrider assisted surgery was 16.45 mins as compared to 13.28 mins in conventional curettage. The average amount of blood loss in conventional group was 44.76 ml whereas in microdebrider group was 77.30 ml.

Conclusion

Microdebrider assisted adenoidectomy has proven to deliver completeness of clearance at the expense of slight increase in bleeding and the operative time.

Keywords

Adenoidectomy; Microdebrider, power-assisted; Endoscopic; Curettage

The adenoids are an aggregate of lymphoid tissues located in the posterosuperior region of the nasopharynx and directly affect the breathing in the upper airway. At birth the adenoids are relatively smaller in size and due to the hyperactivity of the immune system they progressively enlarge during the initial years of life and thus can manifest with nasal obstruction.¹

Adenoidectomy is the mode of treatment employed in managing sleep disordered breathing which is manifested as nasal obstruction, mouth breathing and snoring, middle ear pathologies, chronic rhino-sinusitis and recurrent adenotonsillitis.² It is conventionally performed by the curettage method with St. Clair Thompson adenoid curette which is a blind procedure. Damage to Eustachian tube opening leading to middle ear pathologies and also the remnant adenoid tissue postoperatively is a known fact. With the advent of

endoscopes, surgeries in the nasal cavities have become safer as they are being performed under vision and hence surgeons now-a-days are harnessing the power of it even in the anatomically challenging region of nasopharynx.²

Microdebriders are electrically powered instruments which have an excellent safety profile. They provide precise atraumatic dissection with lesser complications and faster postoperative healing. This study is designed to compare the microdebrider assisted adenoidectomy with the conventional curettage adenoidectomy and to study the efficacy and safety of microdebrider at our

1 - Department of ENT & HNS, KAHER's J.N. Medical College, Belagavi, Karnataka

Corresponding author:

Dr Samanvaya Soni

email: sonisamanvaya@gmail.com

center.

Materials and Methods

This study is a randomized controlled trial done in a tertiary care hospital over a period of 1 year from January 2018 to December 2018. A total of 45 patients were included and were divided into 2 groups randomly using their unique hospital identification number (odd number patients in group A and even number in group B). Group A patients underwent conventional curettage adenoidectomy and group B underwent microdebrider assisted adenoidectomy. The patients included were between the age group of 3-16 years and had symptoms of obstructive sleep apnoea, mouth breathing and snoring or adenoid facies. Patients having craniofacial syndromes (cleft lip or cleft palate) were excluded from study. Ethical clearance was obtained from the institution ethical committee.

Informed consent, routine blood investigations and fitness for surgery were taken. All the patients were operated under general anaesthesia with orotracheal intubation. Pre-operative endoscopic assessment of adenoid grade was done using Clemens-McMurray grading scale.³In the group A adenoidectomy was done using the St. Clair Thompson adenoid curette. In the group B microdebrider assisted adenoidectomy under endoscopic vision was done. We have used the microdebrider with 45° angled blade through oropharynx, set at 15 cc/min irrigation and 5000 oscillation/second. The zero degree endoscope is inserted through either of the nostrils. The intra operative parameters studied were operative time, blood loss, and completeness of clearance of adenoids. Post-operative parameter included assessment of damage to surrounding structures after 3 weeks with a repeat endoscopy.

Intra operative time was taken as the total time from the patient being handed over by the anaesthetist to surgeon to the time the patient is handed back to the anaesthetist for extubation. The amount of bleeding was assessed by a guide given by Algadiem et al. in 2009.⁴ Where they have calculated that a 10x10 cm. Square piece of gauze used for packing the nasopharynx will correspond to a volume of 12 ml. In the microdebrider

group the blood loss was calculated by subtracting the irrigation solution from the total collected fluid in the suction machine. The amount of irrigation solution will be noted down during surgery to avoid calculation error and prior to the surgery the suction machine will be emptied completely. The completeness of clearance of adenoid was assessed by nasal endoscopy at the end of the procedure in both the groups.

The study is focused on comparison of two groups. For the continuous quantitative variables mean and standard deviation were calculated. The inter group continuous variables were compared using suitable tools of statistics like normal test, unpaired student's t test. Two quantitative variables, within a group, were compared using student's paired t test. Discrete variables were represented by median. Suitable graphs were used to depict the comparison. The categorical data was expressed in terms of rates, ratios and percentages. The association between the outcome, clinical and demographic characteristics was tested using Chi-square test or Fisher's exact test. Statistical analysis was done using Statistical Package for the Social Sciences (SPSS) software. For all the tests the value of p less than 5% (0.05) was considered significant.

Results

Total number of cases in the present study were 45 where 25 patients (males 13 and females 12) belonged to group A and 20 patients (males 12 and females 8) belonged to group B. there was a male preponderance of 55.56%. The mean age of patients undergoing adenoidectomy was 9.24 years. The most common presenting complaint was mouth breathing and snoring followed by nasal obstruction and nasal discharge. (Fig. 1) Both the groups were comparable with respect to age, symptoms, gender and pre-operative endoscopic adenoid grade.

Clemens and McMurray adenoid grading before and after operation:

The conversion of patients after adenoidectomy to grade 1 is 12% and grade 2 is 64% in conventional group as compared to 95% patients landing in grade 1 post microdebrider assisted adenoidectomy which is

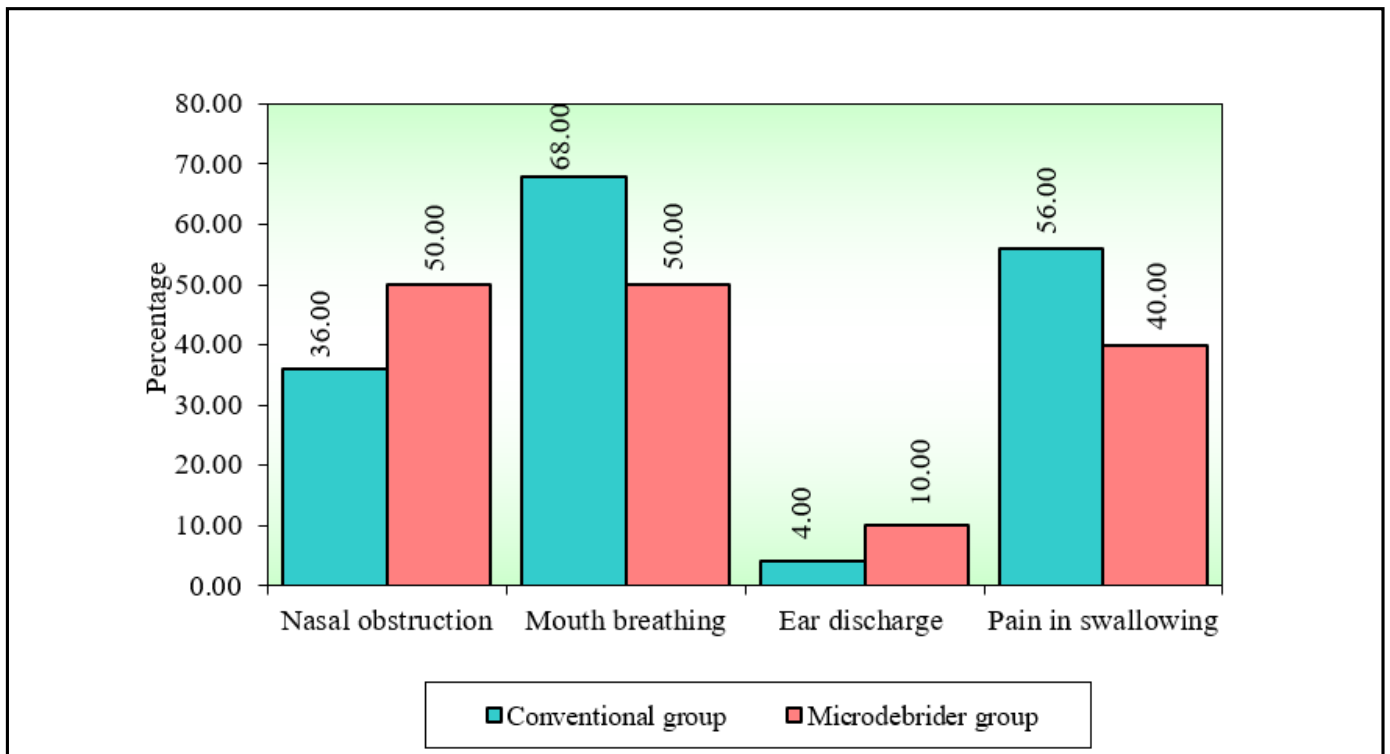


Fig.1. Comparison of two study groups (Conventional and Microdebrider) by chief complaints

statistically significant ($p < 0.05$). (Table I)

By using matched pair test it was clearly seen that pre-operative to post-operative endoscopic grading of adenoid showed that in both the groups the completeness of clearance is statistically significant but in microdebrider group the percentage of change i.e. the reduction of grading post operatively is 63.79% as compared to 30.29% in conventional group, which indicates the effectiveness of microdebrider. (Table II)

Operative time taken:

The average time taken by microdebrider assisted surgery was 16.45 mins as compared to 13.28 mins taken by conventional method which was significantly higher with a p-value of less than 0.05 and was statistically significant ($p = 0.041$). (Fig. 2)

Intraoperative blood loss:

The average amount of blood loss in conventional group

was 44.76 ml whereas in microdebrider group was 77.30 ml. The blood loss was higher in microdebrider assisted adenoidectomy and was statistically significant ($p < 0.05$). (Fig. 2)

Post-operative complications:

At 3 weeks follow-up none of the patients in either of the 2 groups showed eustachian tube dysfunction, uvular injury or posterior pharyngeal wall scarring.

Discussion

Conventional curettage adenoidectomy is a blind and crude procedure and as stated by Koltai and Havas in their studies in 1997 and 2002, there is often residual tissue left behind near choana and torus tubaris region.^{5,6} Our study also showed that residual tissue was left behind in children undergoing conventional curettage adenoidectomy specially near the choana. This might be due to the inability of adenoid curette to reach these

Table I: Clemens and McMurray adenoid grading before and after surgery

ADENOID GRADE	CONVENTIONAL		MICRODEBRIDER		TOTAL	
	PRE-OP	POST-OP	PRE-OP	POST-OP	PRE-OP	POST-OP
1	0	3	0	19	0	22
2	5	16	5	1	10	17
3	14	6	12	0	26	6
4	6	0	3	0	9	0
Total	25	25	20	20	45	45

areas and therefore it can be ascertained that these children may have persistent symptoms post-surgery.

In 1997, Koltai et al., had brought power-assisted adenoidectomy in light and under the vision of laryngeal mirror they achieved a superior resection of adenoid.⁶ Yanagisawa and Weaver in 1997 used an endoscope along with a microdebrider through a transnasal approach and concluded that they had a completeness of clearance of adenoid with significantly lesser complications.⁷ Costantini et al. in 2008, had used a 70° endoscope with video attachment introduced and a 40° microdebrider blade through the mouth to remove the adenoid and they realised that the limitation of mobility of instruments through the nasal cavity could be overcome with this approach.⁸ Anand et al. in 2014

suggested that this difficulty of manoeuvring the instruments can be overcome by passing the endoscope through one nostril and straight blade microdebrider through the other.⁹

Pagella et al. in 2009, on the other hand, combined conventional curettage method with endoscopic method and concluded that with this method though a longer time is taken for surgery but the need to use angled endoscopes and microdebrider blades can be avoided.¹⁰ Same was suggested by Das et al. in 2017.¹¹

Only performing the surgical steps of the adenoidectomy would take about 5-10 minutes, but a proper evaluation of the operative time must include all the steps like setting up the instrument trolley, painting and draping, achieving haemostasis and taking pre

Table II: Comparison of completeness of clearance of adenoids in both groups

GROUPS	TIME	MEAN	SD	MEAN DIFF.	SD DIFF.	% OF CHANGE	Z-VALUE	P-VALUE
Conventional group	Pre-op	3.04	0.68					
	Post-op	2.12	0.6	0.92	0.57	30.26	3.9199	0.0001*
Microdebrider group	Pre-op	2.9	0.64					
	Post-op	1.05	0.22	1.85	0.59	63.79	3.9399	0.0001*

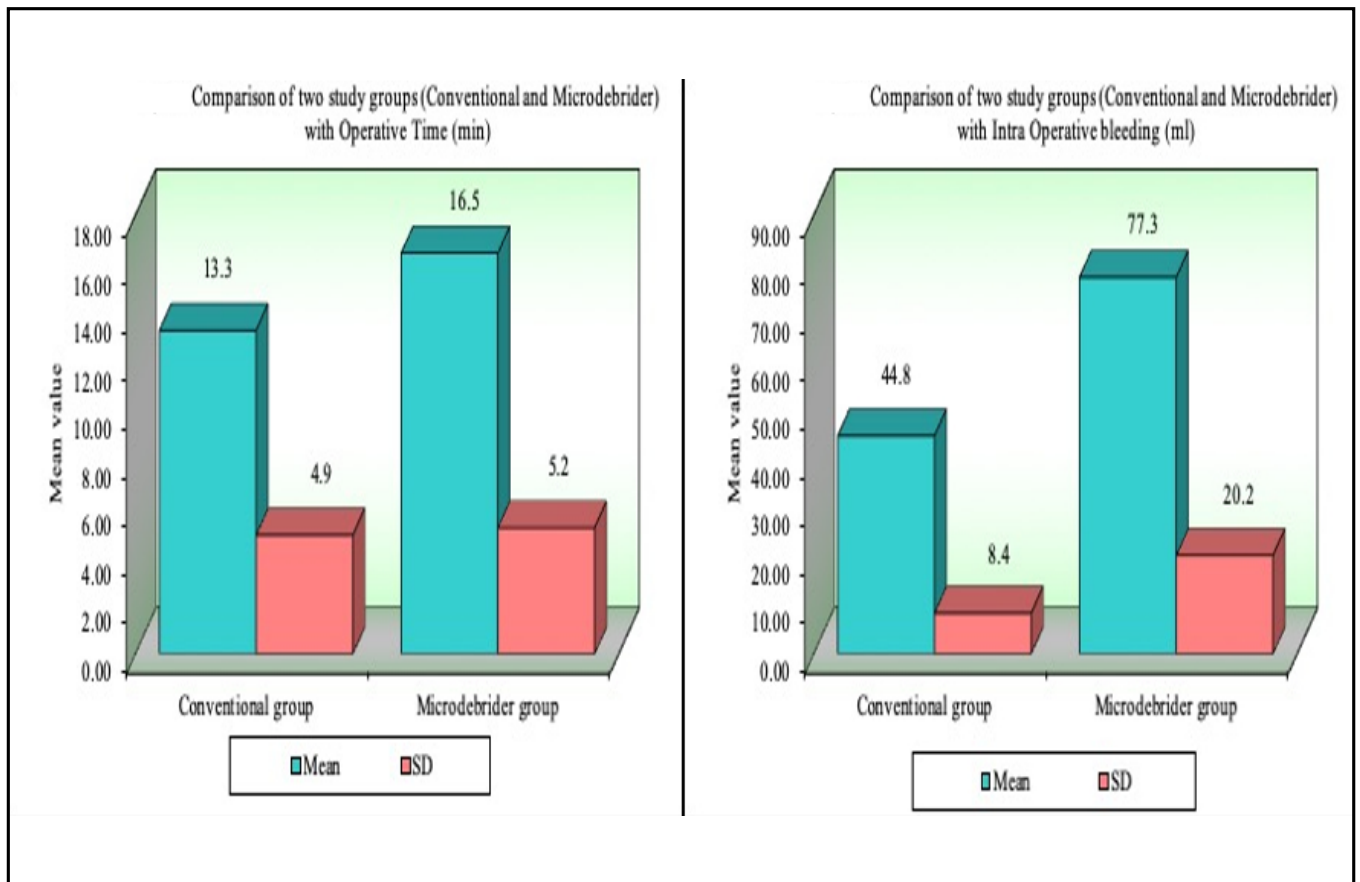


Fig. 2. Comparison of operative time taken and comparison of intra operative bleeding.

and post-operative endoscopic pictures of adenoids. In short, the time taken from patient being handed over to the surgeon by anaesthetist to the complete haemostasis of nasopharynx. The duration of microdebrider assisted adenoidectomy in our study was approximately 16 minutes 45 seconds which was roughly 3 minutes more than conventional adenoidectomy. This was due to increased time taken while setting up connections for powered instruments as well as repeated defogging of endoscope. In a study by Somani et. al. (2010), their operating time with endoscopic technique was 12 minutes 30 seconds, which was 2 minutes shorter than conventional adenoidectomy.¹² This finding was in contrast to our study.

We have used zero-degree endoscope through the nose with a 45° curved blade microdebrider through oropharynx whereby we prevented injury to the soft

palate by retracting the soft palate anteriorly by using a red rubber catheter passed through the other nostril and brought out through the mouth and clamped on the head towel. Our findings are opposite to those by Stanislaw et. al.,¹³ where powered adenoidectomy has merited to be 20% faster than curettage adenoidectomy. They also used 45-degree microdebrider blade through oropharyngeal route coupled with a laryngeal mirror for visualization. This might be the reason why they took lesser time, as setting up of powered instruments and repeated defogging was not needed in their case. In our opinion microdebrider can be a potentially dangerous instrument if not used under vision therefore we recommend endoscopic visualization.

Since in all the above-mentioned studies the operative instruments were not constant and the criterion for defining time taken for operation was not certain, so it

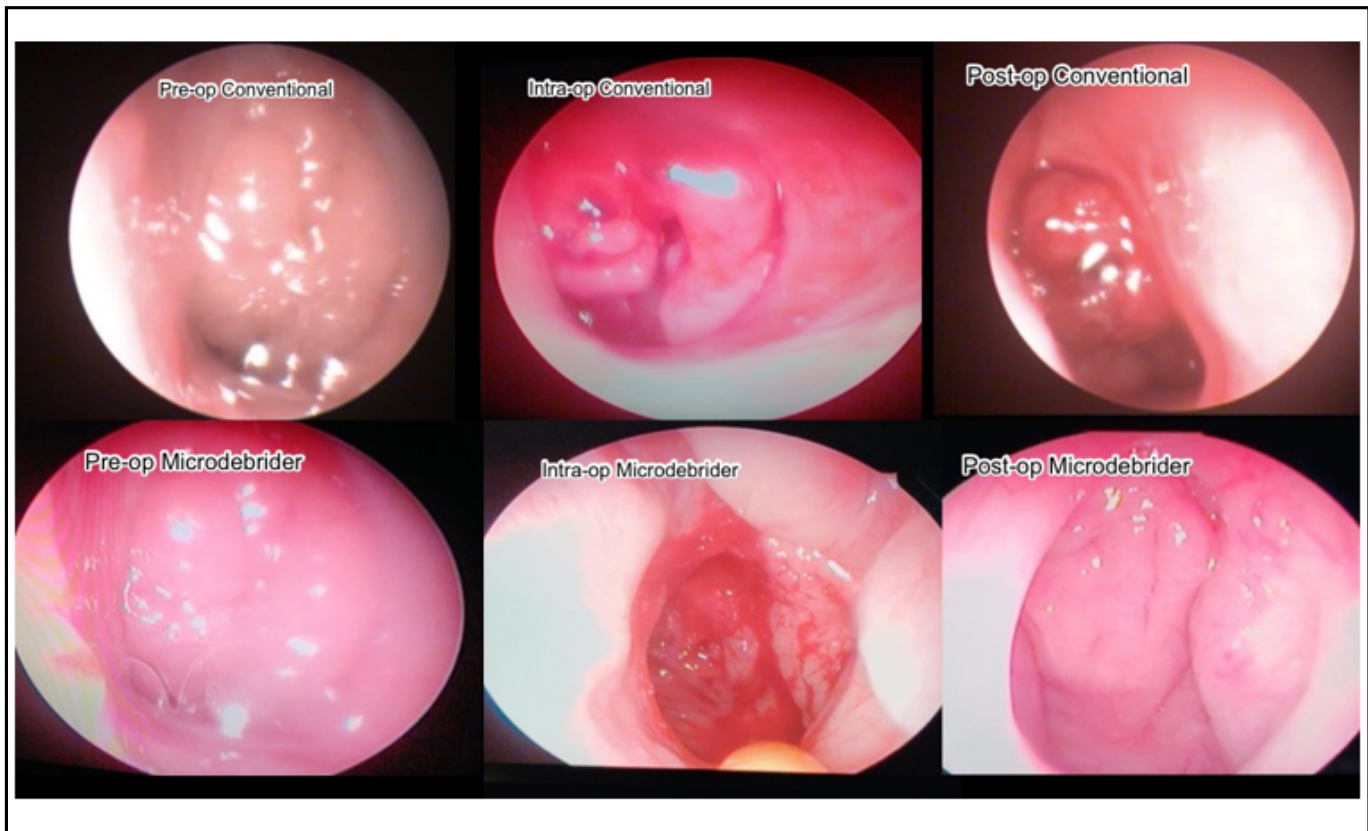


Fig. 3. Endoscopic images showing pre, intra and post-operative status of both the surgical methods

won't be correct to compare operative time.

In our study the intra-operative blood loss is more in microdebrider group. This was statistically significant though the difference was small i.e. 30 ml. Stanislaw et al.¹³ however reported a significant reduction in blood loss with endoscopic technique which was in contrast to our study. Also, in study by Feng et. al.¹⁴ conventional adenoidectomy group had more bleeding though it was not statistically significant. As the microdebrider cuts the tissues little by little in an oscillating fashion the bleeding surface is exposed for a longer time and the continuous suction effect of microdebrider also sucks in more blood.

After conventional adenoidectomy, 64% of patients still had grade II and 24% had grade III remnant adenoid tissue (Table I) which might later regrow and cause airway obstruction. Our results are similar to the ones reported by Havas et al. in 2002 and Pagella et al. in 1997, where

the remnant adenoid was seen in 39% and 49% cases respectively.^{5,10} The possible explanation to such high quantity of remnant adenoids in our understanding is that during conventional adenoidectomy only the tissue that overlies choana fails to get cleared or is pushed towards the nasal cavity, which on endoscopy is perceived as adenoids obstructing the choana. Whereas with the help of endoscope, the nasopharynx can be clearly visualised and any remnant thereof can be removed and a complete clearance of disease can be achieved.

In present study 95% of the patients post microdebrider assisted adenoidectomy landed with grade I adenoid. (Table I) Therefore, it can be agreed that endoscopic microdebrider-assisted adenoidectomy has the advantage of improved visualization and continuous suction of blood from the surgical field, thus one can precisely remove adenoid tissue from the choana and torus tubaris.¹³ (Fig. 3)

Collateral damage to adnexa following adenoidectomy is less but there is always a fear of trauma to the eustachian tube opening and subsequent otological complications. In our study the torus tubarius region was partially injured in two cases of curettage adenoidectomy. In microdebrider group, however there was an increased incidence of nasal mucosal injuries. To summarise, though both techniques have their own peculiar problems, they are usually self-resolving and minor. None of the patients developed any known post-operative complications like otitis media with effusion or damage to soft palate or uvula.

The newer method of microdebrider assisted adenoidectomy was found to be a safe and efficacious tool in terms of completeness of clearance. However, the drawbacks were increased time taken for surgery and increased amount of bleeding. The newer procedure still has some contra-indications and can't be used for taking a biopsy.

In the Indian scenario the limitation of instrumentation and the cost of surgery are important factors which govern the choice of surgical method. The use of nasal endoscopes is a routine practice now but availability of powered instruments like microdebrider is still less. Endoscopic microdebrider-assisted adenoidectomy is technically more difficult to perform than conventional adenoidectomy^{6,13} but those surgeons who are routinely performing endoscopic sinus surgery in them the learning curve is smaller¹⁵ and there was also high degree of surgeon satisfaction due to improved plane of dissection.¹³ Now a days documentation is very important and The TV monitor relays the display enabling recording for documentation and teaching purposes.

Conclusion

Adenoidectomy is a routine Otolaryngologic surgery done in Paediatric age group for various indications and often after conventional curettage there is remnant adenoid tissue which doesn't alleviate the symptoms. Microdebrider assisted adenoidectomy has proven to deliver completeness of clearance at the expense of slight increase in bleeding and the operative time. Though the

cost of surgery is higher but precise dissection under vision, lesser complications and better disease clearance makes this technique a safe and efficacious alternative over the blind curettage method.

References

1. Kim JW, Kim HJ, Lee WH, Kim DK, Kim SW, Kim YH, et al. Comparative study for efficacy and safety of adenoidectomy according to the surgical method: A prospective multicenter study. *PLoS ONE* 2015; 10(8):2-9
2. Datta R, Singh VP, Deshpal. Conventional versus endoscopic powered adenoidectomy: A comparative study. *Med J Armed Forces India*. 2009; 65(4):308-12. doi: 10.1016/S0377-1237(09)80089-0
3. Clemens J, McMurray JS, Willging JP. Electrocautery versus curette adenoidectomy: comparison of postoperative results. *Int J Pediatr Otorhinolaryngol*. 1998; 43(2):115-22
4. Algadiem EA, Aleisa AA, Alsubaie HI, Buhlaiah NR, Algadeeb, Bagir J, et al. Blood Loss Estimation Using Gauze Visual Analogue. *Trauma Mon*. 2009; 21(2):1-9
5. Havas T, Lowinger D. Obstructive Adenoid Tissue. *Arch Otolaryngol Neck Surg*. 2002; 128(7):789
6. Koltai PJ, Kalathia AS, Stanislaw P, Heras HA. Power-Assisted Adenoidectomy. *Arch Otolaryngol Head Neck Surg*. 1997; 123(7):685-8. doi: <https://doi.org/10.1001/archotol.1997.01900070023004>.
7. Yanagisawa E, Weaver EM. Endoscopic adenoidectomy with the microdebrider. *Ear Nose Throat J*. 1997; 76(2):72-4
8. Costantini F, Salamanca F, Amaina T, Zibordi F. Videoendoscopic adenoidectomy with microdebrider. *Acta Otorhinolaryngol Ital Organo Uff Della Soc Ital Otorinolaringol E Chir Cerv-facc*. 2008; 28(1):26-9
9. Anand V, Sarin V, Singh B. Changing Trends in Adenoidectomy. *Indian J Otolaryngol Head Neck Surg*. 2014; 66(4):375-80
10. Pagella F, Matti E, Colombo A, Giourgos G, Mira E. How we do it: A combined method of traditional curette and power-assisted endoscopic adenoidectomy. *Acta Otolaryngol (Stockh)*. 2009; 129(5):556-9
11. Das AT, Prakash SB, Priyadarshini V. Combined conventional and endoscopic microdebrider-assisted adenoidectomy: A tertiary centre experience. *J Clin Diagn Res*. 2017; 11(2):MC05-7
12. Somani SS, Naik CS, Bangad SV. Endoscopic Adenoidectomy with Microdebrider. *Indian J Otolaryngol Head Neck Surg*. 2010; 62(4):427-31
13. Stanislaw Jr. P, Feustel PJ, Koltai PJ. Comparison of power-assisted adenoidectomy vs adenoid curette adenoidectomy. *Arch Otolaryngol - Head Neck Surg*. 2000; 126(7):845-9
14. Feng Y, Yin S. Comparison of the powered-assisted

adenoidectomy with adenoid curette adenoidectomy. Lin
Chuang Er Bi Yan Hou Ke Za Zhi. 2006; 20(2):54-7

15. Abdel-Aziz M. Endoscopic nasopharyngeal exploration at the end of conventional curettage adenoidectomy. Eur Arch Otorhinolaryngol. 2012; 269(3):1037-40.