

# Mucormycosis: Effect of Comorbidities and Repeated Debridement on the Outcome

Harshavardhan N Reddy,<sup>1</sup> Sanjay B Patil,<sup>1</sup> Chandrakiran Channegowda,<sup>1</sup> Aiswarya Muralidharan,<sup>1</sup>

## ABSTRACT

### Introduction

Mucormycosis is an aggressive, invasive infection caused by ubiquitous filamentous fungi belonging to the subphylum Mucormycotina, order Mucorales. Mucormycosis most commonly affects immunocompromised hosts, but are rarely reported in immunocompetent hosts as well. The most common reported sites of invasive mucormycosis have been the sinuses (39%), lungs (24%), and skin (19%). The hallmark of mucormycosis is angioinvasion resulting in vessel thrombosis and hence, tissue necrosis.

### Materials and Methods

Ambispective study of 20 cases with mucormycosis seen and treated in our hospital between 2009 and 2015 and followed up to 2017 to compare the prognosis of the cases of repeated debridement with that of single debridement and effect of comorbidities in the outcome of patients mortality.

### Results

Out of 20 patients 19 (95%) received Liposomal Amphotericin B. 11 (55%) were male and 9 (45%) were female. All the 7 (35%) who underwent repeated debridement survived. Out of 13 (65%) patients who underwent single debridement, 5 (25%) did not survive. 2 (10%) patients were lost for follow up. The survival amongst the patients undergoing multiple debridement and single debridement was statistically significant ( $p=0.042$ )

### Conclusion

The chances of survival are better in cases with better controlled comorbid conditions like diabetes mellitus. Repeated debridement with Liposomal Amphotericin B is the most effective mode of management.

### Keywords

Mucormycosis; Comorbidity; Amphotericin B; Debridement

Mucormycosis is an aggressive, invasive infection caused by ubiquitous filamentous fungi belonging to the subphylum Mucormycotina, order Mucorales, which grow in soil and dead and decaying matter. Fungi belonging to this order are further divided into 6 families, all of which can cause cutaneous and deep infections. Species belonging to the family Mucoraceae are most often responsible for mucormycosis and among them, Rhizopus species is by far the most common cause of infection followed by

Mucor and Lichtheimia species.<sup>1</sup>

Mucormycosis most commonly affects immunocompromised hosts, but has rarely been reported in immunocompetent hosts as well. It infects people with haematological malignancies, on cancer chemotherapy, organ transplant, uncontrolled diabetes, patients on deferoxamine therapy in iron overload following dialysis. It has been observed that trauma patients also develop mucormycosis as wounds get contaminated with the fungus.<sup>2</sup>

Mucormycosis is an emerging problem of the developing world and more recently, even in the developed countries. Owing to the rising prevalence of diabetes, cancer, and organ transplantation in the ageing population, the number of patients at risk for this deadly infection is expected to continue to rise.<sup>3</sup>

1 - Department of ENT, M S Ramaiah Medical College  
Bengaluru

### Corresponding author:

Dr Harshavardhan N Reddy  
email: docharshavardhan@yahoo.com

The main principles of treatment are early diagnosis, correction or control of the associated comorbidities, surgical debridement of infected tissue and adequate and appropriate antifungal therapy.<sup>1</sup>

## Materials and Methods

Ambispective study of patients who were diagnosed and treated at our centre from Jan 2009 to Dec 2015. Data was assessed regarding age, sex, presenting symptoms, orbital involvement, comorbidities and management.

## Results

Our study included 20 patients, out of which 11 (55%) were males and 9 (45%) were females. Age ranged from 10 years to 65 years with a mean age of 41.05 years. 18 (90%) of the patients had associated comorbidities. Of the other 2 (10%) without comorbidities, one 65 year old patient with isolated sphenoid sinus involvement and a 15 year old boy who presented with extensive involvement with cavernous sinus thrombosis.

13 (65%) patients had uncontrolled Diabetes Mellitus and a total of 6 (30%) patients had Chronic Kidney Disease. Out of 13 patients with Diabetes Mellitus, 3 had Chronic Kidney Disease. Out of these 13 patients with Diabetes Mellitus, 5 (38%) survived after adequate control of blood sugars, extensive debridement and liposomal Amphotericin B and 2 (15%) were lost to follow up. 13 (65%) patients had orbital involvement. Out of this 13 with orbital involvement, 5 (38.4%) patients underwent orbital exenteration and remaining 8 (61.5%) underwent orbital decompression (Table I).

A total of 5 (25%) patients succumbed to the disease and a total of 2 (10%) patients were lost to follow up. 7 (35%) patients underwent repeated debridement. All the patients who underwent repeated debridement survived the disease. Of the 5 (25%) patients who succumbed to the disease, 3 (15%) patients had orbital involvement.

After suspicion of Sino nasal mucormycosis, patients underwent biopsy. Tissue was sent for both KOH mount and culture. After the initial report was suggestive of fungal hyphae, patients were started on intravenous Liposomal Amphotericin B, if the serum creatinine was

within normal limits. All but one patient (19 (95%)) received Liposomal Amphotericin B ranging from 100 mg to 4.3 gms. The only patient who did not receive Amphotericin B was case 1, who could not afford it and expired on 2nd day post-op. Initial dose varied from 50 milligrams to 200 milligrams, depending on the serum creatinine and disease load. Patients with orbital involvement and intracranial extension received up to 200 mg and others were started on 50 mg.

All the patients were put in the ICU and remained there as long as they received Liposomal Amphotericin B. Patients were taken up for endoscopic debridement within the next 24 hours. Extensive debridement of the involved mucosa and tissue were debrided, till fresh bleeding normal tissue was encountered. All the tissue was again sent for histopathology and KOH mount. Patients were examined with nasal endoscopy in the OPD on every day and upon finding further tissue involvement, repeated endoscopic debridement was done in the operation theatre.

Repeated debridement was planned based on clinical findings of further progress of disease like palatal discoloration, worsening of orbital swelling etc. and repeat endoscopy in OPD (only if the patient is stable enough to be shifted to OPD). If any clinical sign of disease progress or endoscopic findings of further tissue necrosis was identified, then further debridement was done in OT.

No radiological investigations were undertaken in deciding repeated debridement. Orbital decompression or exenteration was done based on whether orbit was oedematous or involved. Orbit involvement with no vision was a prerequisite for orbital exenteration. Orbital exenteration was done by Ophthalmologists. Patient continued to receive Liposomal Amphotericin B till they were completely disease free or till they developed toxicity. Serum creatinine was monitored daily and if the value was deranged, Liposomal Amphotericin B was withheld till the values returned to normal (Table I).

Patients were followed up to a period of two years and endoscopic examination was done in the OPD during each review. Initially patient was reviewed every 2 weeks for 1 month, then monthly for 6 months and subsequently every 6 months up to 2 years.

Table I: Details of the cases including management and survival

SL NO	AGE/SEX	ORBIT INVOLVED	CO MORBIDITIES #	SURGICAL MANAGEMENT *	AMPHOTERICIN B (TOTAL DOSE)	SURVIVAL @
1	65/F	Yes	DM	DO, OE	NIL	x
2	28/F	No	CKD	DO	200 mg	+
3	48/M	No	CKD	DO	200 mg	+
4	55/F	Yes	DM	DR, OD	1.3 gm	+
5	65/M	No	NIL	DO	1.3gm	+
6	45/M	Yes	DM	DR, OD	1.2gm	+
7	10/M	Yes	Ac. Lymp. Leuk.	DO, OD	200 mg	+
8	65/M	No	Rec, CKD, DM	DO	1.0 gm	x
9	15/M	Yes, CST	NIL	DO, OE	150 mg	x
10	16/F	Yes	PVF (Dengue) -1 week	DR, OE	2.5 gm	+
11	45/M	No	DM	DO	150mg	x
12	33/M	No	CKD, Post Renal Transplant	DO	100mg	+
13	50/M	Yes	DM	DO, OE	1.5 gm	+
14	40/M	Yes	DM, CKD	DO, OD	50 mg	--

**Table I: Details of the cases including management and survival**

SL NO	AGE/SEX	ORBIT INVOLVED	CO MORBIDITIES #	SURGICAL MANAGEMENT *	AMPHOTERICIN B (TOTAL DOSE)	SURVIVAL @
15	45/F	No	DM	DO	100mg	--
16	62/F	Yes	DM, CKD	DO, OD	250 mg	x
17	32/F	Yes	DM, PVF & TCP	DR, OE	4.3gm	+
18	34/F	Yes	DM	DR, OD & RM	1.3gm	+
19	33/M	Yes	DM	DR, OD	2.0 gm	+
20	35/F	Yes	DM	DR, OD	2.0 gm	+

Abbreviations:

# (DM = Diabetes Mellitus, CKD = Chronic Kidney Disease, Ac. Lymph. Leuk. = Acute Lymphocytic Leukemia, CST = Cavernous Sinus Thrombosis, PVF = Post Viral Fever, TCP = Thrombocytopenia, Rec = Recurrence of mucormycosis).

\* (DO = Debridement Once, DR = Debridement Repeated, OE = Orbital Exenteration, OD = Orbital Decompression, RM = Radical Maxillectomy).

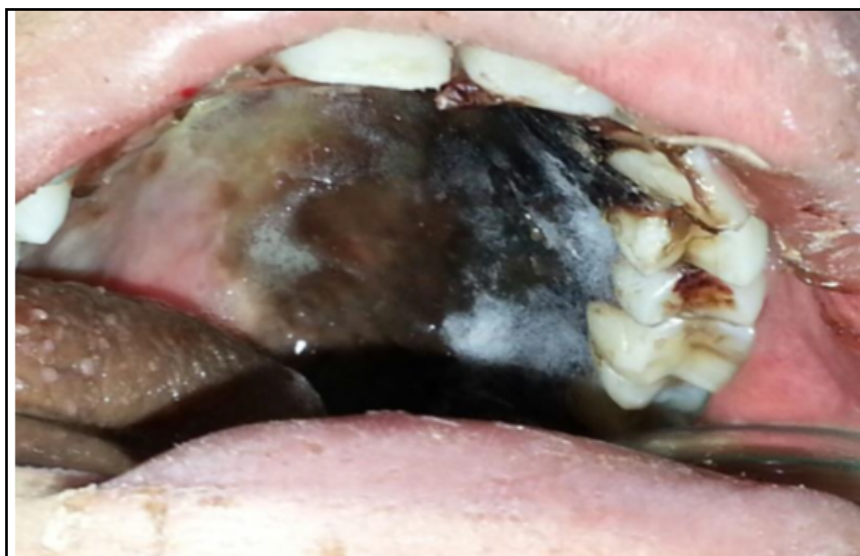@ (survived = +, not survived = x, lost for follow up = --)

## Discussion

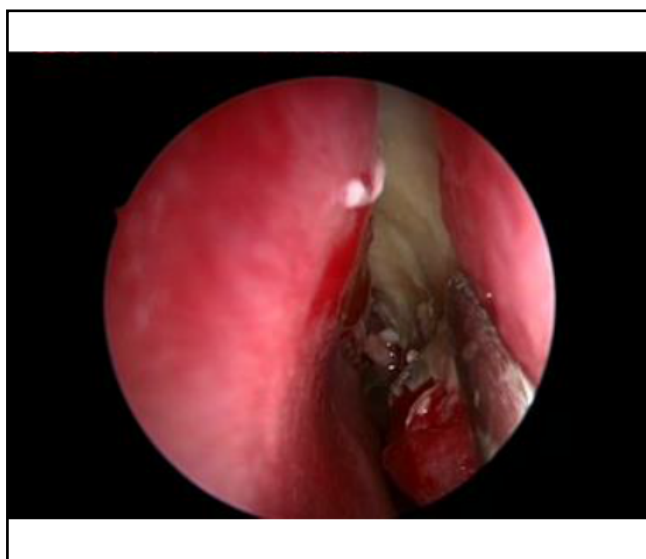
Mucormycosis is an emerging problem of the developing world and more recently, even in the developed countries. Owing to the rising prevalence of diabetes, cancer, and organ transplantation in the ageing population, the number of patients at risk for this deadly infection is expected to continue to rise.<sup>3</sup>

There has been an increasing incidence of Diabetes Mellitus and Cancer in the elderly population which translates to an increase in the incidence of mucormycosis. The initial symptoms of Rhinocerebral mucormycosis are vague and present similar to sinusitis and periorbital cellulitis<sup>1</sup> and include eye or facial

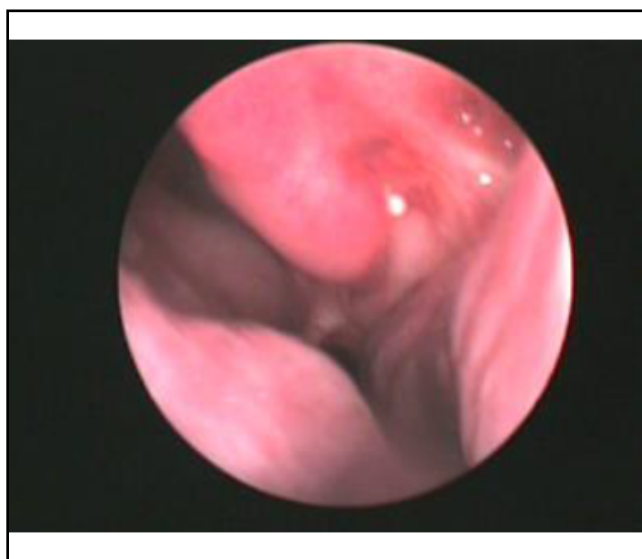
pain and facial numbness, followed by the onset of conjunctival suffusion, blurry vision, and soft tissue swelling. If undetected and left untreated in the early stages, the infection spreads from the paranasal sinuses into the orbit and this could affect the function of the extraocular muscles. Upon visual inspection, infected tissue may appear normal during the earliest stages of spread of the fungus. Infected tissue then progresses through an erythematous phase, with or without edema, before onset of a violaceous appearance, and finally the development of a black, necrotic eschar (Figs. 1 & 2) as the blood vessels become thrombosed and tissue infarction occurs.<sup>4</sup> Further involvement of the orbit causes proptosis and progressive vision loss. This could



**Fig. 1. Mucormycosis in a 15 year old boy with palatal involvement with eschar of palate.**



**Fig. 2. Mucormycosis involving the left lateral nasal wall in a 16 year old patient recovering from Dengue fever**



**Fig. 3. Post treatment Diagnostic Nasal Endoscopy of the patient in Fig 2 (OPD Review).**

be due to direct involvement of the optic nerve or due to thrombosis of the vessels supplying the nerve or because of cavernous sinus thrombosis. The infection can further extend superiorly and posteriorly into the cranial cavity.

The most common reported sites of invasive mucormycosis have been the sinuses (39%), lungs (24%), and skin (19%).<sup>3</sup> The hallmark of mucormycosis

is angioinvasion resulting in vessel thrombosis and hence, tissue necrosis. This ability of angioinvasion by the fungus causes the fungus to disseminate haematogenously from the site of origin to other areas.

The main principles of treatment are early diagnosis, correction or control of the associated comorbidities, surgical debridement of infected tissue and adequate and

appropriate antifungal therapy.<sup>1</sup> Early and rapid diagnosis is achieved by a detailed endoscopic evaluation of the nasal cavity. Radiographic evaluation is not diagnostic, but aids to ascertain the extent of the disease and to substantiate diagnosis. Contrast Enhanced Computed Tomography of the Paranasal Sinuses shows mucosal thickening, periorbital thickening and erosion of bone margins. Magnetic resonance (MR) imaging is quite useful in identifying the intradural and intracranial extent of rhino-orbito-cerebral mucormycosis, cavernous sinus thrombosis, and thrombosis of cavernous portions of the internal carotid artery. Contrast-enhanced MR imaging can also demonstrate perineural spread of the infection.<sup>5</sup> This devitalized mucosa appears on contrast-enhanced MR imaging as contiguous foci of non-enhancing tissue.<sup>6</sup>

Diagnosis is confirmed by histopathological examination. Stains like hematoxylin and eosin, Grocott-Gomori methenamine–silver nitrate, and periodic acid-Schiff, reveal characteristic hyphal elements in tissue. Histopathologic examination reveals characteristic broad (3-25 µm in diameter), ribbon-like, thin-walled, aseptate hyphae that have irregular diameters; with nondichotomous irregular branching and accompanying tissue necrosis and fungal angioinvasion. Improved staining procedures with fluorescent stains, such as Calcofluor White, may be more revealing with small numbers of hyphae or limited tissue samples. Even the presence of fungal hyphae in histopathologic analysis, fungal cultures are only positive in 50% of cases because of the friable nature of nonseptate hyphae, which are frequently damaged during tissue manipulation.<sup>7</sup>

Pathogenesis research has led to the possibility of using Mucorales-specific T cells as a potential diagnostic test for mucormycosis.<sup>2</sup>

The only two systemic anti fungals with good activity against Mucorales are Amphotericin B and Posaconazole. Reed et al, in a retrospective analysis of diabetic patients with rhino-orbital-cerebral mucormycosis, noted that patients who received combination lipid amphotericin B-caspofungin therapy had significantly better treatment success and survival time compared with patients who received amphotericin B monotherapy.<sup>8</sup>

Patients who respond to a parenteral amphotericin

B-based treatment, given for at least 3 weeks, are then switched over to oral Posaconazole as maintenance therapy. Amphotericin B has the ability to produce prolonged tissue concentration and hence maintenance therapy using 5mg/kg 2-3 times a week after initial therapy can be used instead of Posaconazole.<sup>7</sup>

For potential novel therapies, passive immunization targeting virulence genes of Mucorales such as iron acquisition through high affinity iron permease or proteins involved in mediating host cell invasion has proven to be effective against experimental mucormycosis.<sup>2</sup> Equally important, research into the immunopathogenesis of mucormycosis likely will pave the road for new treatment modalities that include adoptive immunotherapy using Mucorales-specific T cells and/or NK cells.

Aggressive antifungal therapy and extensive and sometimes even disfiguring debridement of the infected tissues is the treatment of choice and despite this, the mortality is about 40% or more.

The study conducted at our centre, included 20 patients with a confirmed diagnosis of Mucormycosis. 19 (95%) received Liposomal Amphotericin B, only 1 patient did not receive Amphotericin B due to financial constraints and he succumbed to the disease. Out of the 20 patients, 2 (10%) patients did not have any known comorbidities, a 65 year old patient with isolated sphenoid sinus involvement and a 15 year old boy who presented with extensive involvement with cavernous sinus thrombosis. Out of 18 (90%) who had complete follow up 16 (80%) patients had co morbidities, out of which 13 (65%) patients had Diabetes Mellitus, 6 (30%) patients had Chronic Kidney disease and 3 (15%) patients had both Type 2 Diabetes Mellitus and Chronic Kidney Disease. 1 (5%) patient had Acute Lymphocytic Leukemia and 1 (5%) patient was recovering from Dengue fever (Fig 2 and 3). Diabetes Mellitus is the most common comorbidity seen in 65% cases (Table I).

Out of the 20 patients, 13 (65%) patients had orbital involvement of which 8 (61%) patients underwent Orbital Decompression and 5 (38%) patients underwent Orbital Exenteration. A total of 5 (25%) patients succumbed to the disease and a total of 2 (10%) patients were lost to follow up. All the 7 (35%) patients who

underwent repeated debridement survived (100%), while out of the 13 (65%) who underwent single debridement, 2 were lost to follow up and of the 11 (55%) who were followed up only 6 (54.5%) survived. As per Chi Square test differences in the survival rate with multiple debridement and single debridement amongst the comorbidities was found to be statistically significant ( $p=0.042$ )

Of the 5 (25%) patients who succumbed to the disease, 3 (15%) patients had orbital involvement, 4 (20%) of them had uncontrolled Diabetes Mellitus and 2 (10%) had both (Table I).

The above results indicate the importance of control of blood sugar levels in patients with Mucormycosis. The chance of survival is better in cases in which the comorbid conditions are controlled better. Our study shows that repeated debridement with Liposomal Amphotericin B is the most effective mode of management, especially in Orbital involvement. Due to small sample size individual morbidities were not considered.

After the initial surgery, patient has to be reassessed every day in the OPD with diagnostic nasal endoscopy (Fig. 3) and if tissue is found to be unhealthy, then further debridement has to be carried out at the earliest. Rigid control of the diabetes along with Liposomal Amphotericin B is very important in controlling the spread of the disease. Only drawback is ICU set up is needed for these patients to receive Amphotericin B, due to the toxicity of Amphotericin, so it may not be possible to undertake these measures in a rural set up.

## Conclusion

The initial study suggests that repeated debridement give a better prognosis compared with single debridement along with Liposomal Amphotericin B in all cases. Proper control of co-morbidities ensures a better outcome. Larger sample studies with appropriate randomisation is warranted to generate clinical evidence in this regard.

## References

1. Spellberg B, Edwards J, Jr, Ibrahim A. Novel perspectives on mucormycosis: Pathophysiology, presentation and management. *Clin Microbiol Rev.* 2005; 18:556-69
2. Ibrahim A.S, Kontoyiannis D., Update on Mucormycosis pathogenesis, *Curr Opin Infect Dis.* 2013; 26(6): 508-15
3. Torres-Narbona M, Guinea J, Martinez-Alarcon J, et al. Impact of mucormycosis on microbiology overload: a survey study in Spain. *J Clin Microbiol.* 2007; 45:2051-3
4. Petrikkos, G., A. Skiada, H. Sambatakou, A. Toskas, G. Vaiopoulos, M. Giannopoulou and N. Katsilambros. Mucormycosis: ten-year experience at a tertiary-care center in Greece. *Eur. J. Clin Microbiol Infect Dis.* 2003; 22:753-6
5. Petrikkos, G., A. Skiada, Lortholary O., Roilides E., Walsh T. Kontoyiannis D. Epidemiology and Clinical Manifestations of Mucormycosis. *Clin Infect Dis.* 2012; 54 (suppl 1): S23-S34
6. S. Safder, J.S. Carpenter, T.D. Roberts, N. Bailey. The "Black Turbinate" Sign: An Early MR Imaging, Finding of Nasal Mucormycosis. *AJNR Am J Neuroradiol.* 2010; 31(4):771-4 doi: 10.3174/ajnr.A1808.Epub 2009 Nov 26
7. Kontoyiannis D, Lewis R. How I treat mucormycosis *Blood* 2011; 118(5): 1216-24
8. Reed C, Bryant R, Ibrahim AS, et al. Combination polyene-caspofungin treatment of rhino-orbital-cerebral mucormycosis. *Clin Infect Dis.* 2008; 47(3):364-71.