

# Parapharyngeal Tumours : Our Experience in a Tertiary Care Hospital

<https://doi.org/10.47210/bjohns.2020.v28i3.313>

Debabrata Das,<sup>1</sup> Arjuman Parveen,<sup>2</sup> Apurba Sarkar,<sup>1</sup> Sk Nawazur Rahaman<sup>2</sup>

## ABSTRACT

### Introduction

Tumours of parapharyngeal space are rare. Surgical excision is the mainstay of its management. However, approach to the space is rather difficult. The transcervical approach is most commonly practiced as opposed to the transoral approach, due to fear of complications. The present study aims to study the two approaches with respect to treatment outcomes and complications.

### Materials and Methods

A prospective study was conducted from July 2018 to December 2019 (1.5 years) at the Department of ENT in a tertiary care Hospital. A total of 10 cases of parapharyngeal tumours were selected; 5 of involving the prestyloid compartment underwent transoral surgery and the other 5 involving the post styloid compartment underwent transcervical surgery. The results of surgery and complications were studied.

### Results

The mean age of presentation was 36.5 yrs. Male: Female ratio was 3:2. There were 9 benign and 1 malignant case in the study. The most common presentation was an asymptomatic oropharyngeal mass (80%). The most common pathological type was pleomorphic adenoma of the salivary gland (50%).

### Conclusion

We found that the transoral approach is as effective as transcervical approach in surgical cure and contrary to the popular belief, it is associated with fewer complications. Hence, carefully selected cases can be safely managed by this approach.

### Keywords

Parapharyngeal Tumors; Surgical Approaches; Treatment Outcome

Parapharyngeal space (PPS) is one of potential fascial planes of head and neck and resembles an inverted triangular pyramid with the base at the skull base and apex at the greater cornu of hyoid bone. The prevertebral fascia joining the styloid process to the tensor veli palatini divides it into the pre-styloid (containing adipose tissue, lymphatics and ectopic salivary gland tissue) and post-styloid (containing the internal carotid artery, internal jugular vein, cranial nerves IX to XI, the cervical sympathetic chain, lymph

nodes and glomus bodies) compartments.

Tumours of the parapharyngeal space are uncommon, comprising 0.5 - 1% of all head and neck neoplasms.<sup>1</sup> According to one study, about 80% are benign and 20% malignant.<sup>2</sup> Due to its deep location in the neck, clinical examination is limited and hence diagnosis of PPS lesions is completely dependent on imaging. Fine needle aspiration cytology (FNAC) reveals inconsistent results. On cross sectional imaging (CT/MRI), PPS appears as a small triangular space with density/signal consistent with fat.<sup>3</sup> Prestyloid mass causes displacement of the PPS fat medially and displacement of internal carotid artery (ICA) posteriorly. Poststyloid mass causes displacement of PPS fat anterolaterally, displacement of ICA anteriorly or medially.

The choice of surgical approach is dictated by the size of the tumour, its location, its relationship to the great vessels, and suspicion of malignancy. Because most of

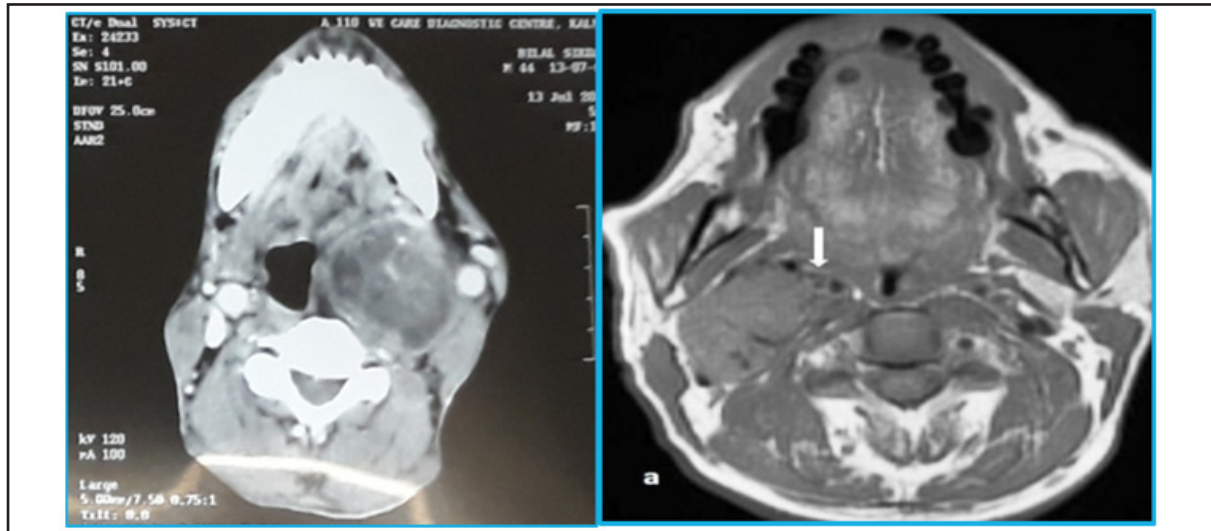
1 - Department of ENT, R G Kar Medical College & Hospital, Kolkata

2 - Department of ENT, Burdwan Medical College & Hospital, Burdwan

### Corresponding author:

Dr Arjuman Parveen

email: arjuman2391@gmail.com



**Fig.1. Axial CT of left prestyloid mass and TW1 axial MRI of right poststyloid mass**

these tumours are benign, the approach chosen should minimize surgical morbidity, as well as the risk of surgical recurrence. These tumours can be approached intra orally or through an external incision which can be transcervical (below mandible), transparotid (behind mandible) or transmandibular (through a mandibulotomy). A combination of these approaches may be required at times. Most surgeons discourage intraoral approach due to its limited exposure, fearing greater chances of major vessels and nerve injury. However, this approach can be undertaken in carefully selected cases of prestyloid compartment lesions with similar efficacy and lower morbidity than external approach. The present study aims to redefine the advantages of using the approach and alleviate the misconceptions around it.

### Materials and methods

All cases of head and neck tumours attending the OPD of the Department of ENT were evaluated and a total of 10 cases of parapharyngeal tumours were selected. After obtaining written consents, a prospective study was conducted from July 2018 to December 2019 (1.5 years). After meticulous history taking and a thorough clinical examination of head and neck, these patients were subjected to routine investigations, FNAC and CT

scans. (Fig.1) Surgical approach was decided based on the following criterion:

Transoral approach - Benign, relatively avascular, well encapsulated tumours of prestyloid compartment (Size  $\leq$  3 cm) with no neck/ parotid component and no involvement with vital structures.

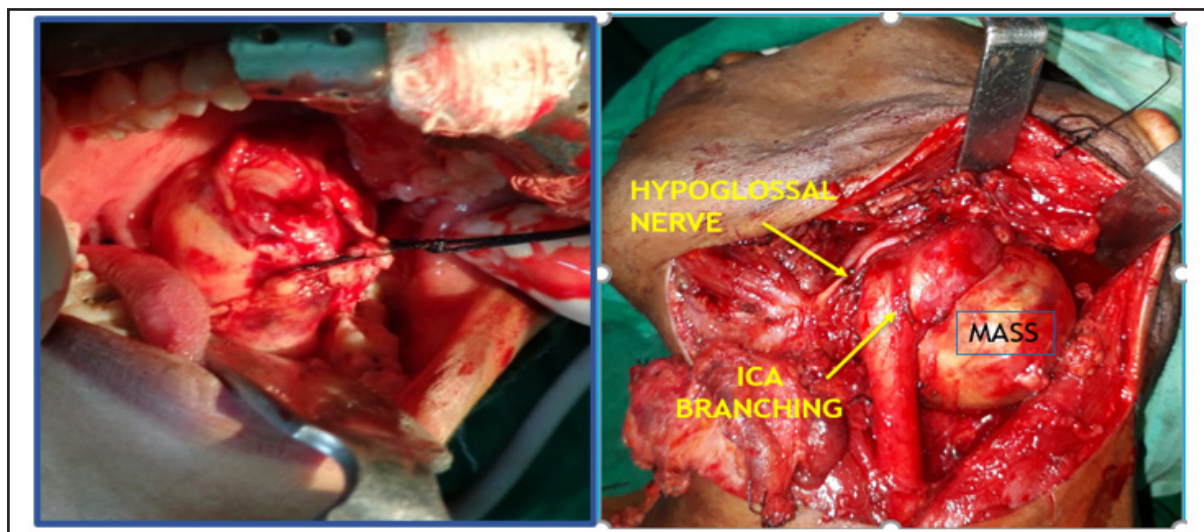
Transcervical approach- Malignant or vascular tumour of poststyloid compartment (Size  $>$  3 cm) with close relation to vital structures.

Thus, 5 cases involving the prestyloid compartment underwent transoral surgery and the other 5 involving the post styloid compartment underwent transcervical surgery. (Fig. 2)

Postoperatively, the histopathological report confirmed the diagnosis and the patients were observed for development of complications for a period of 6 months.

### Results

Out of all the patients of head and neck tumours attending the ENT OPD for the given period of the study, 0.46% were found to suffering from parapharyngeal tumours. 60% patients were male and 40% were female, with a male: female ratio of 3:2. The most common presenting age group was 21-40 years (40%) and the most common



**Fig. 2. Tumour delivery by transoral route (left) and by transcervical approach (right).**

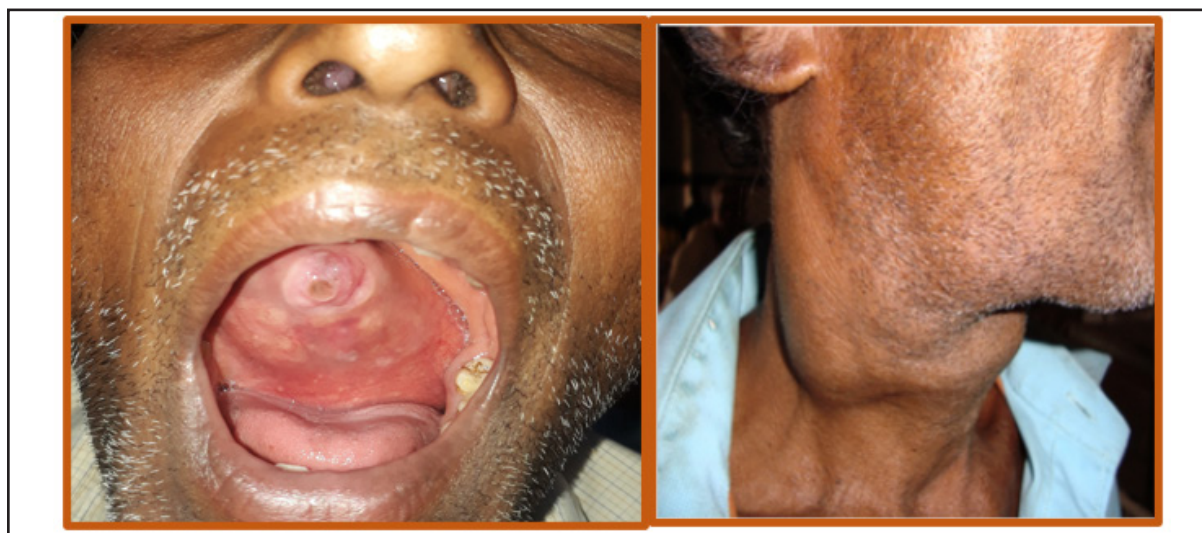presenting feature was oropharyngeal mass (80%) followed by neck mass (50%), (Fig. 3) dysphagia, hoarseness of voice and tongue deviation (Fig.4).

Histopathologically, 90% cases were benign and there was only one case of malignant vagal paraganglioma. Out of the total, 50% tumours were of salivary gland origin, 30% were schwannomas and 20% were paragangliomas. (Table I)

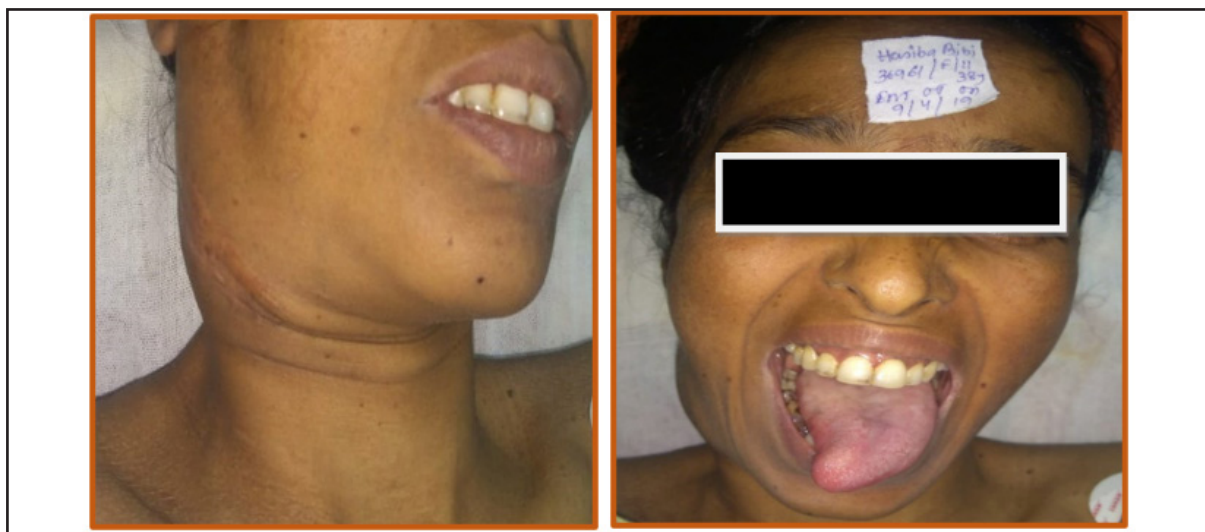In the transoral approach group, there were no

incidence of nerve or vascular injury but in one patient, there was wound dehiscence (Fig. 5) that was managed conservatively (Ryle's tube feeding followed by healing by secondary intention). There was 1 case of recurrence as it was misdiagnosed preoperatively as benign tumour of prestyloid compartment (postoperatively turned out to be malignant paraganglioma) that was referred for radiotherapy.

In the transcervical group, one patient suffered from



**Fig. 3. Presentation as an intraoral mass and as a neck mass**



**Fig. 4. Neck mass with hypoglossal nerve involvement**

transient vagal nerve paresis and another from transient marginal mandibular branch of facial nerve paresis (Fig.5) which resolved spontaneously to conservative management. Intra-op. ligation of internal jugular vein

in one patient for better exposure and tumour delivery. One of the patients suffered from a CVA on 3<sup>rd</sup> postop day. There was one case of hypertrophied scar formation. No recurrences were seen.

**Table I: Case profile (n=10)**

CASE NO	AGE/SEX	PREOP FNAC REPORT	SURGICAL APPROCH	POSTOP HPE REPORT
1	16/F	Benign salivary gland tumour	Transoral	Pleomorphic Salivary Adenoma (PSA)
2	20/F	Benign salivary gland tumour	Transoral	Pleomorphic Salivary Adenoma (PSA)
3	25/F	Benign salivary gland tumour	Transoral	monomorphic Salivary Adenoma
4	32/M	Paraganglioma	Transcervical	Carotid body tumour
5	36/M	Schwannoma	Transcervical	Vagal Schwannoma
6	37/M	Benign salivary gland tumour	Transoral	PSA deep lobe
7	42/M	Benign salivary gland tumour	Transcervical	Pleomorphic Salivary Adenoma (PSA)
8	45/M	Paraganglioma	Transoral	Vagal paraganglioma (Malignant)
9	50/F	Schwannoma	Transcervical	Hypoglossal Schwannoma
10	62/M	Schwannoma	Transcervical	Vagal Schwannoma

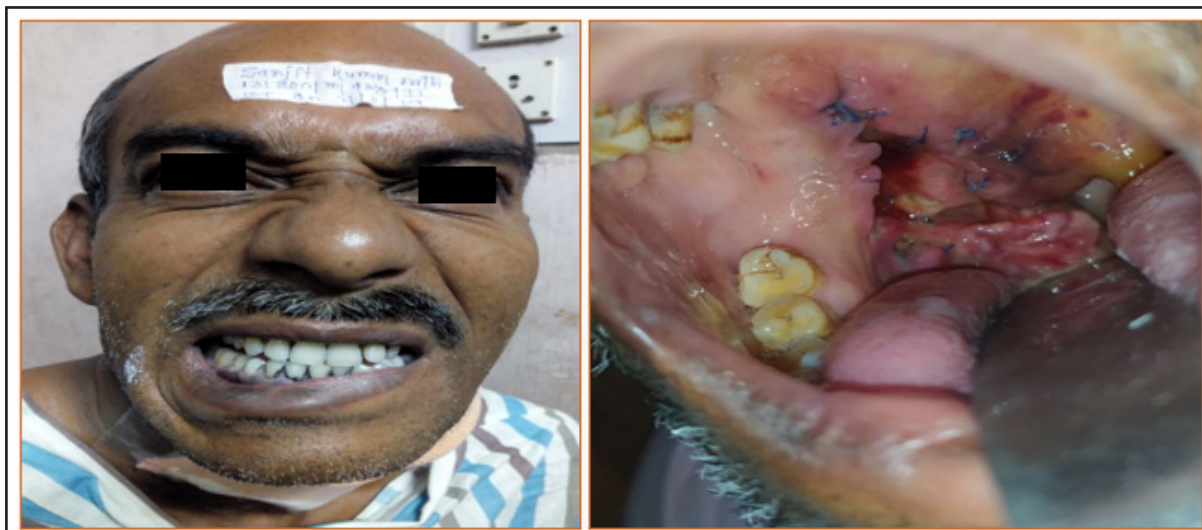

Fig. 5. Case of nerve injury (marginal mandibular nerve) and wound dehiscence.

### Discussion

In the present study, majority of the patients affected by parapharyngeal tumours were male in the age group of 21-40 years. These tumours are rare in extremes of ages. Most tumours were benign salivary gland adenomas limited to the prestyloid compartment of the parapharyngeal space, a finding that is consistent with other studies as well. (Table II) The usual presentation is an asymptomatic oropharyngeal mass with or without

neck extension. It has been reported by other studies that the tumour must be at least 3cm in size to have a neck component.

A high clinical suspicion is needed for timely diagnosis and appropriate management. Imaging studies are instrumental in reaching to a diagnosis. Many of these patients may be subjected to repeated inconclusive intraoral FNAC before they undergo a CT scan, thereby allowing progression of disease to the neck, precluding the use of a relatively less morbid transoral surgery. The

Table II : Comparison with other recent studies

FINDINGS	PRESENT STUDY	F BOZZA ET AL 2009 <sup>4</sup>	KEI IGICHI ET AL 2017 <sup>5</sup>
Number of cases	10	10	29
Mean Age	36.5 yrs	49 yrs	43.5 yrs
M : F	03:02	02:01	15:14
MC Presentation	Oropharyngeal mass (80%)	Neck mass	Neck mass (37.5%)
Benign : Malignant	09:01	02:01	23:02
MC Pathological type	Salivary gland tumour (50%)	Salivary gland tumour (80%)	Salivary gland tumour (44.8%)
Most Frequent complication	"Hoarseness (Vagal nerve paresis)"	"Horner's syndrome (Sympathetic nerve plexus)"	"Horner's syndrome (Sympathetic nerve plexus)"

**Table III: Comparison between the two approaches to surgery.**

COMPLICATION	TRANSORAL (N=5)	TRANSCERVICAL (N=5)
External scar	No	Yes
Nerve injury (Temporary)	Nil	2
Vascular injury	Nil	2
Wound complication	1	1
Recurrence	1	Nil

surgeon is forced to go for a more extensive surgery due to late presentation and diagnostic delay.

In the present study, the cases selected for transoral approach were diagnosed early and managed successfully with little complications. (Table III) In spite of limited exposure in this method, neurovascular injury could be avoided because of adequate knowledge of tumour location and its relationship with the structures in the neck. Using the technique of blunt finger dissection aids in avoiding any such injury. Taking care so as to not rupture the capsule of the tumour prevents seeding of the tumour and recurrences. The recurrent case encountered in the present study was not a consequence of the surgery per se but more due to the malignant nature of the tumour. This approach also has the benefit of no external scar which maybe an issue with young individuals.

It is noteworthy that despite adequate exposure in the transcervical surgical approach, neurovascular injury could not have been prevented in an advanced tumour that has already involved the structures in the neck. However, whenever there is any doubt with respect to completeness of tumour removal, full and extensive exposure must be ensued that may require conversion of a transoral approach to a transcervical one with or without mandibulotomy or mandibulectomy wherever needed.

### Conclusion

As it is evident from this study that there was no case

of nerve or vascular injury in patients who underwent transoral resection, this approach must be considered for carefully selected patients because it produces less morbidity than the transcervical approach.

Complications are not associated only with a particular surgical approach but it is largely determined by the tumour characteristics like location, malignancy and relationship with important structures in the neck. A surgeon must not shy away from the transoral approach fearing higher complication rate.

However, all patients must be counselled regarding the conversion of a transoral approach to transcervical and that a mandibulotomy or even a tracheostomy may be necessary.

### References

1. Stell PM, Mansfield AO, Stoney PJ. Surgical approaches to tumors of the parapharyngeal space. *Am J Otolaryngol.* 1985; 6:92–97. doi: 10.1016/S0196-0709(85)80045-4
2. Riffat F, Dwivedi RC, Palme C, et al. A systematic review of 1143 parapharyngeal space tumors reported over 20 years. *Oral Oncol* 2014; 50(5): 421-30
3. Rajagopal K, Ramesh A, Sreepathi S, Shetty C. CT Evaluation Of Parapharyngeal Masses: Pictorial Essay. *The Internet Journal of Radiology* 2008; 10(2): 1-12
4. Bozza F, Vigili MG, Ruscito P, Marzetti A, Marzetti F. Surgical management of parapharyngeal space tumours: results of 10-year follow-up. *Acta Otorhinolaryngol Ital.* 2009 Feb;29(1):10-5
5. Ijichi K, Murakami S. Surgical treatment of parapharyngeal space tumors: A report of 29 cases. *Oncology Letters* 2017; 14(3): 3249-54. <https://doi.org/10.3892/ol.2017.6480>.

# Hydatid Cyst of Submandibular Region

BOI Number

Jyotirmoy Phookan,<sup>1</sup> Pritam Chatterjee,<sup>2</sup> Sritama De<sup>3</sup>

## ABSTRACT

### Introduction

Hydatid cysts in the neck are relatively exceptional. We report a rare case of a hydatid cyst localized in the right submandibular region of the neck with a second cyst in lung discussing diagnostic and management algorithm with brief review of literature.

### Case Report

A 6 years old boy presented to us in Gauhati Medical College & Hospital with a gradually enlarging painless swelling in right submandibular region since last 4 months. The patient was thoroughly evaluated. Imaging and FNAC was performed. Suspected common locations were also screened prior to surgery. He was treated with total pericystectomy and followed up regularly.

### Discussion

Hydatid disease is a widespread public health problem in developing countries. The possibility of hydatid disease, especially in endemic regions, may always be considered in the differential diagnosis of mesenchymal neoplasms or soft tissue cystic masses in the neck. Radiologic imaging modalities in such cases are mandatory for the diagnosis. The prognosis is excellent in hydatid cyst cases treated with total removal of the cyst without rupture.

### Keywords

Hydatid Cyst; Submandibular

Hydatid cyst is an infectious disease which is most commonly caused by *Echinococcus granulosus* and less commonly by *Echinococcus multilocularis*. Humans are accidental intermediate hosts in echinococcus lifecycle, as infection of human beings represents a terminal event. Dogs are the main host, and animals like cattle, sheep, horse and pig are intermediate hosts in the disease. Parasite eggs that penetrate the organism hatch in small intestine of the main host, pass into portal venous system or lymphatic system and reach liver and lungs, and finally form hydatid cyst lesions.

Moreover, they can cross hepatic sinusoid or pulmonary capillary barriers, and embryos get into systemic circulation and can settle in all the organs and structures in the body.<sup>1,4</sup> Typically, a man is exposed to the organism by ingestion of contaminated vegetable or meat.

Infection may also occur when playing with dogs harbouring tapeworm, as eggs cling to their fur. The larval form may invade any organ system, and distribution of infection is limited only by blood flow and filtration. Hydatid cyst is most frequently involved in liver and lungs, and rarely in the bone, brain, eye, heart, kidney, spleen and parotid gland.<sup>3,5</sup> Atypical localization of hydatid cyst may be challenged the diagnosis of hydatid disease.<sup>2</sup> The neck is one of the atypical sites of hydatid disease, accounting for no more than 1% of all hydatid sites.<sup>1,6</sup>

## Case report

A 6 years old boy presented at Gauhati Medical College with a painless swelling in right submandibular region which he noticed 4 months back. The swelling had gradually increased in size however there was no history

1 - Department of Otorhinolaryngology & Head-Neck Surgery, Assam Medical College & Hospital, Dibrugarh, Assam

2 - Department of Otorhinolaryngology & Head-Neck Surgery, Bankura Sammilani Medical College & Hospital, Bankura

3 - Department of Otorhinolaryngology & Head-Neck Surgery, Jag Pravesh Chandra Hospital, New Delhi

### Corresponding author:

Dr Jyotirmoy Phookan  
email: jpphookan@hotmail.com