

# A Comparative Study of the Effects of Anterior Nasal Packing versus Trans-Septal Suturing in Post-Septoplasty Patients

<https://doi.org/10.47210/bjohns.2020.v28i2.323>

Prakash N S,<sup>1</sup> Shreyas K,<sup>1</sup> Puneeth P J,<sup>1</sup> Nishtha Sharma,<sup>1</sup> Veena Prabhakaran<sup>1</sup>

## ABSTRACT

### Introduction

Following septoplasty, the usual norm is to pack the nose using polyvinyl alcohol or white petroleum jelly impregnated gauze. But due to side effects like pain, respiratory problems, headache or pain during pack removal, trans-septal suturing is recommended as it provides stability and prevents septal hematoma formation without causing the above mentioned complaints. This study aims to conduct an in-depth comparison of the outcomes of the two aforementioned methods in an Indian population.

### Materials and Methods

A prospective randomized comparative study was done for 30 patients between 18-50 years undergoing septoplasty, while excluding those requiring additional surgical interventions. Trans-septal suturing was done for 15 patients and polyvinyl alcohol nasal packing for the rest. Visual Analogue Scale was used to record discomfort levels 1 day post-operatively. A vast multitude of symptoms were assessed during regular visits for 3 months after surgery.

### Results

Post-operatively, nasal pain, headache, dyspnoea, sleep disturbance, post-nasal drip, crusting, and epiphora were found to be reduced in patients who underwent trans-septal suturing when compared with packing, deeming it to be a superior choice of method. However, nasal bleeding was comparable in both groups.

### Conclusion

Trans-septal suturing reduces pack related problems and post-operative complications, without significantly increasing the duration of surgery. Hence, we recommend the practice of placing sutures to positively improve patients' quality of life post-surgery.

### Keywords

Septoplasty; Nasal Packing; Sutures, Trans-septal

Septoplasty is a common surgery in otorhinolaryngology, performed primarily on patients with deviated nasal septum causing nasal obstruction, mouth breathing, snoring and recurrent episodes of sinusitis and otitis media. It is also indicated in patients having recurrent epistaxis due to a septal spur, and as a part of septorhinoplasty procedures. Nasal packing has been considered to be an essential step of the surgery, performed via different techniques.<sup>1</sup> However, there is lack of definitive standards entailing the preferred

materials which should be used for nasal packing, how long the pack should be left in place, or the specific indications for nasal packing.<sup>2</sup>

Some of the common scenarios warranting packing in nasal septal surgeries include control of

*1 - Department of ENT, JJM Medical College, Davangere, Karnataka*

### Corresponding author:

Dr Prakash N S

email: drprakashns@gmail.com

haemostasis, avoidance of septal haematoma, and prevention of displacement of replaced cartilage.<sup>3</sup> But nasal packing comes with its own disadvantages, mainly patient discomfort and the need for hospital stay.<sup>3</sup> Nasal packing has been reported as one of the leading causes of early postoperative pain,<sup>4</sup> and pack removal in the postoperative period is accompanied by pain.<sup>5</sup> Additional complications include the worsening of sleep-disordered breathing and risk of postoperative infections, predominantly toxic shock syndrome resulting from post-septoplasty packing.<sup>6</sup>

Trans-septal suturing alleviates all the aforementioned problems without causing any complications. In 1984, Sessions et al studied continuous suture quilting, where he used 4-0 plain catgut suture mounted on a small cutting needle in order to approximate the mucosal flaps.<sup>7</sup> A similar technique was discussed by Lee et al, the difference being the usage of a curved needle instead of the cutting type.<sup>8</sup> These techniques aid in closure of mucosal tears and provide support to the remaining cartilage.<sup>9</sup>

Although there is no paucity of studies comparing selective outcomes of nasal packing with trans-septal suturing following septoplasty, there appears to be a dire need of a broad all-inclusive study, which delves into the entire spectrum of post-procedural complications in the same subset of patients, so as to

avoid any confounders or bias caused by differences in patient demographics or criteria of selection for study. Our study has hence been conducted to achieve the same and overcome the limitations of research articles on this topic conducted in the past, while simultaneously evaluating the post-operative quality of life.

## Materials and Methods

After obtaining institutional ethical clearance, a single blinded prospective randomized comparative study was conducted in a district general hospital from September 2018 to February 2019. Thirty patients of either sex between the age groups of 18 to 50 years having symptomatic deviated nasal septum, who were willing to undergo the procedure of septoplasty, were selected for the study. Those requiring additional interventions such as turbinectomy, conchoplasty or endoscopic sinus surgery were excluded from the study. Patients were divided into two groups of 15 patients each using envelope method. polyvinyl alcohol (Meroce1®) nasal packing was proposed for patients of Group A, while Group B patients were planned to undergo trans-septal suturing after septoplasty.

Informed written consent was taken from all patients, following which all cases were taken up

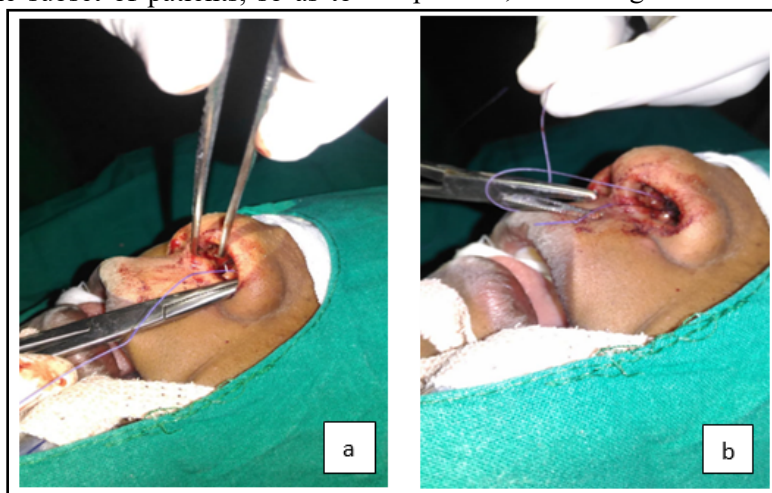
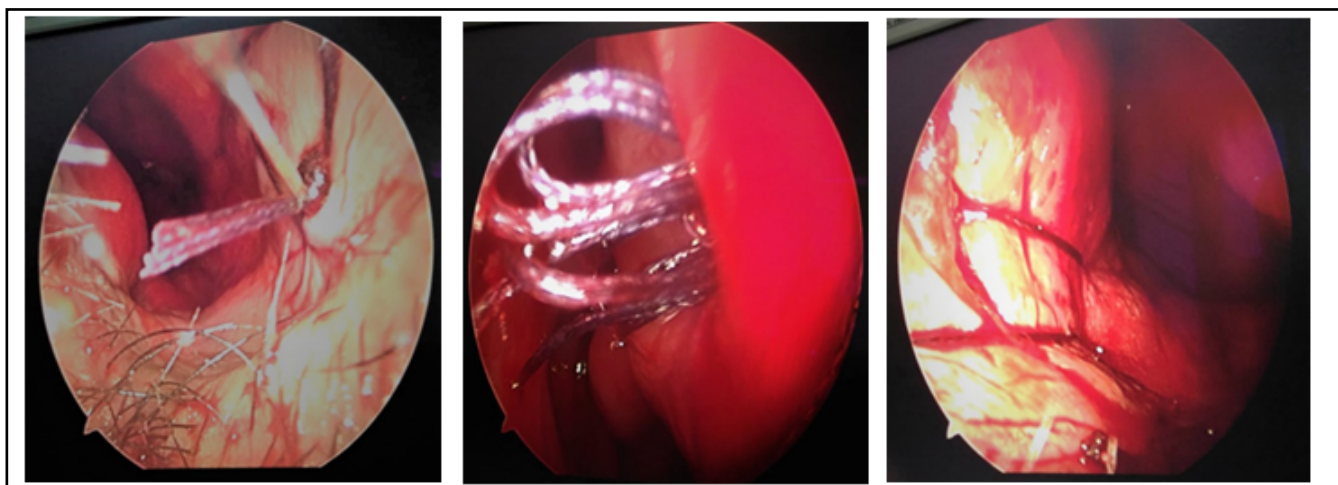


Fig. 1. a & b : Fracture of the body of mandible; c : fracture at the condyle of mandible; d : fracture at the symphysis of the mandible



**Fig. 2. Endoscopic view of trans-septal suturing**

under general anaesthesia. Surgery for all cases was done by a single surgeon to maintain uniformity. Infiltration using 2% lignocaine with 1 in 1,00,000 adrenaline was given over the septal mucosa on both sides. Killian's incision was given 2–3 mm behind the caudal end of septal cartilage on the concave side. Mucoperichondrial and mucoperiosteal flap was elevated on one side, following which bony-cartilaginous junction was identified and dislocated. Deviated part of bony septum was removed using Luc's forceps. Inferior strip of cartilaginous septum was removed. Maxillary crest was removed using gouge and hammer. Hemostasis achieved and flaps were repositioned.

During this stage, it was revealed to the surgeon if patient belonged to Group A or Group B. Patients of Group A underwent nasal packing using polyvinyl alcohol nasal packing. Trans-septal quilting sutures were placed (Fig. 1-a, 1-b) to Group B patients using Vicryl® 3-0 absorbable suture material. (Fig. 2) After surgery, patients received parenteral antibiotics, and adequate analgesia for 3 days. Nasal packing was removed for patients of Group A on second post-operative day. Patients were advised to use saline nasal wash for three months post-surgery.

Patients were asked to record post-operative symptoms using a Visual Analogue Scale (VAS) on first post-operative day. (Fig. 3) The intensity of post-operative symptoms was graded from 1 to 10,

with 10 being the score for maximal discomfort and 1 being the least.

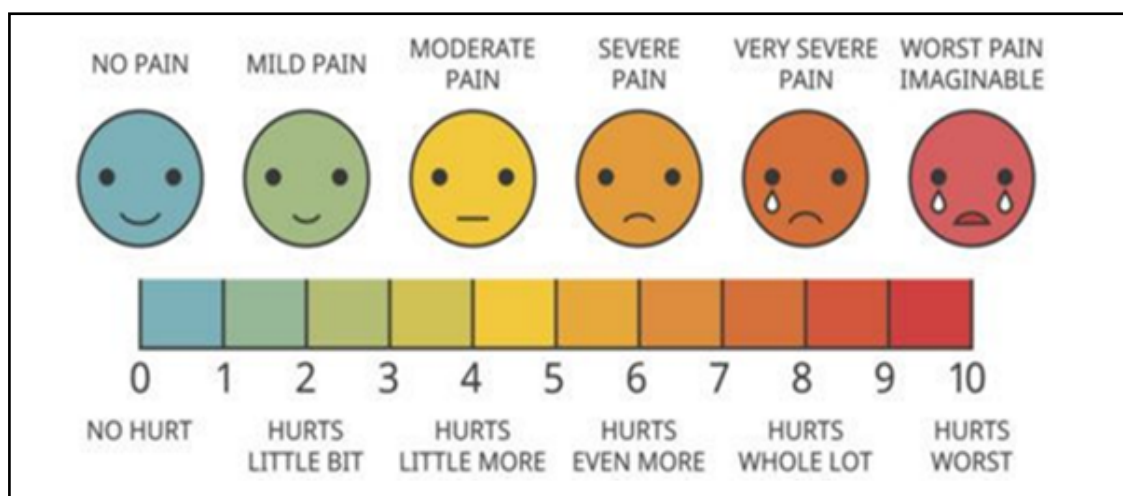
Various symptoms, namely nasal pain, nasal bleeding, headache, difficulty in breathing, sleep disturbance, increased lacrimation, post nasal dribbling, and excessive crusting were assessed using VAS during immediate post-operative period and during subsequent visits. Complications like septal hematoma, septal adhesions, and synechiae were also documented. Three follow-up visits were scheduled at first week, second week and third month following surgery.

Results were presented as Mean  $\pm$  SD and range values of VAS and categorical data as numbers and percentages. Since the observations were made in scores (VAS), which is a non-parametric method, Mann-Whitney test was used to compare between two groups. Chi-square test was used for analyzing categorical data. p value of 0.05 or less was considered for statistical significance. SPSS software (version 17) was used for analysis.

## Results

The mean age of the sample (30 cases), who were ranging from 18 to 50 years, was  $23.2 \pm 5$  years in Group A and  $24.2 \pm 6.0$  years in Group B. (Table I)

The first assessment was carried out on the first



**Fig. 3. Visual analogue score to document responses from patients**

postoperative day, and the severity graded between 0 to 10 based on the Visual Analogue Scale. The results obtained were tabulated and compared for each symptom separately, which are discussed in the subsequent paragraphs.

Post-operative nasal pain was found to be significantly higher in Group A, (mean -  $4.5 \pm 1.8$ ) as compared to Group B (mean -  $2 \pm 1.6$ ). On comparison, p was found to be less than 0.001, which was highly significant. (Fig. 4)

Post - operative nasal bleeding was found to be equal in both the groups, with mean values being  $3.3 \pm 2.3$  in group A and  $3.2 \pm 2.5$  in group B. (Fig. 5) It was more in cases of correction of gross deviation of septum and prominent spurs, irrespective of the method used.

Patients in Group A complained of headache more than the patients in Group B. Mean was  $4.3 \pm 2.2$  in Group A, whereas it was  $1.5 \pm 1.4$  in Group

B. Hence, headache was found to be significantly reduced on trans-septal suturing ( $p < 0.001$ ).

Post-operative difficulty in breathing was significantly lower in Group B ( $1.1 \pm 1.3$ ) as compared to Group A ( $4.7 \pm 1.5$ ). p value was found to be less than 0.001 which was statistically highly significant, proving trans-septal suturing to be a better method in this parameter.

Post-nasal drip and sleep disturbance were found to be significantly lower in Group B when compared with Group A, with mean values of  $0.8 \pm 1.1$  and  $1.2 \pm 1.4$  respectively in group B as opposed to  $3.3 \pm 2.3$  and  $3.8 \pm 2.5$  respectively in Group A.

Increased lacrimation and excessive crusting were assessed, but results were not found to be statistically significant.

Overall, patients who underwent trans-septal suturing had a better quality of life as compared to patients who underwent nasal packing due to

**Table I: Mean age of patients in both the groups**

AGE DISTRIBUTION		GROUP A	GROUP B	GROUP A V/S GROUP B	
				T	P
Age (years)	Mean $\pm$ SD	$23.2 \pm 5.1$	$24.2 \pm 6.0$	0.5	0.62, NS

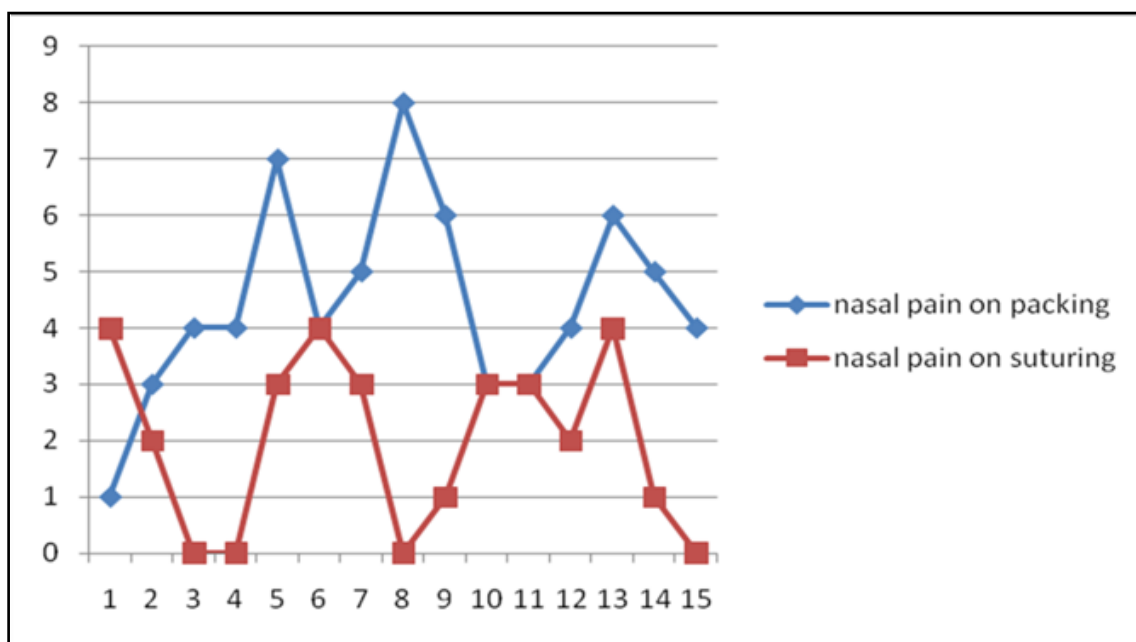


Fig. 4. Comparison of nasal pain between nasal packing and trans-septal suturing

a marked reduction in symptoms of nasal pain, headache, decreased quality of sleep and post nasal drip (Fig. 6). There was no incidence of complications

such as septal hematoma or synechiae in either group. Hence, it is a safer and easier alternative to nasal packing post-septoplasty, as proved by our

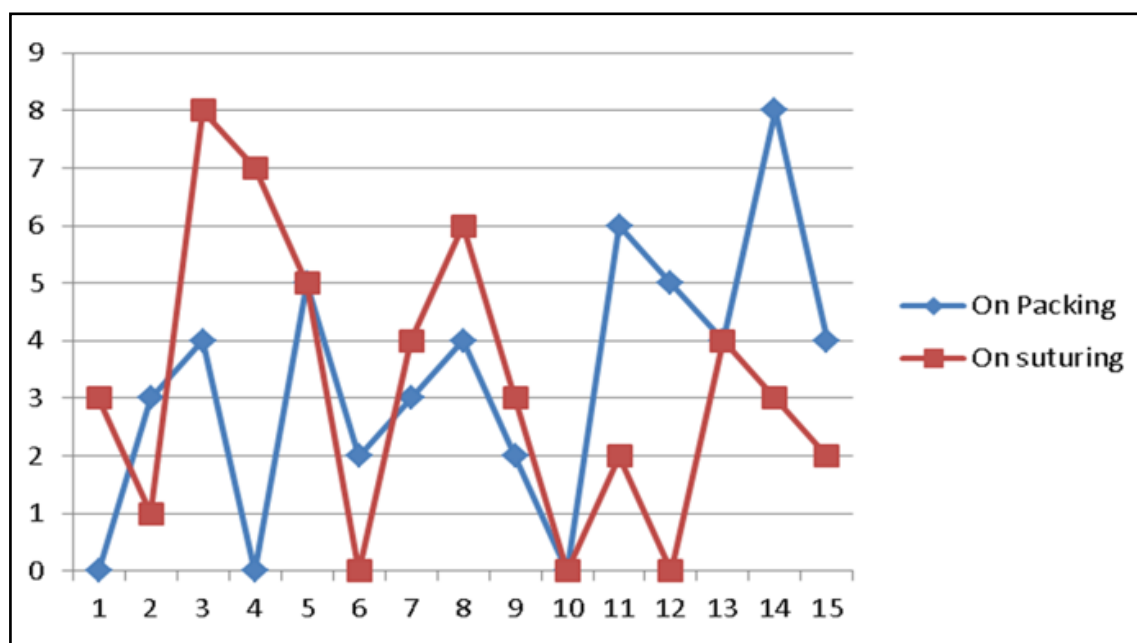


Fig. 5. Comparison of nasal bleeding between nasal packing and trans-septal suturing



TABLE II: Comparison of symptom scores between both the groups on post-operative day

SYMPTOMS ASSESSED POST-SEPTOPLASTY	GROUP A	GROUP B	COMPARISON
	MEAN ± SD	MEAN ± SD	P VALUE
1.Nasal pain	4.5±1.8	2.0±1.6	< 0.001, HS
2.Nasal bleeding	3.3±2.3	3.2±2.5	0.78, NS
3.Headache	4.3±2.2	1.5±1.4	0.001, S
4.Difficulty in breathing	4.7±1.5	1.1±1.3	< 0.001,HS
5.Post nasal drip	3.3±2.3	0.8±1.1	0.002, S
6. Sleep disturbance	3.8±2.5	1.2±1.4	0.004, S
7.Increased lacrimation	1.7±1.9	1.1±1.4	0.51, NS
8. Excessive crusting	1.3±1.6	0.9±1.4	0.51, NS

Mann-Whitney test

p < 0.05, Significant (S)

Group A - nasal packing

p < 0.001, Highly Significant (HS)

Group B - trans-septal suturing

p < 0.05, Not Significant(NS)

study. (Table II)

The follow up visits were conducted at the end of first week, second week and third month after surgery. But symptom score for all patients in both groups were less than or equal to 1 according to VAS in all parameters at the end of first week, and 0 in subsequent visits. Hence, these were treated as clinically insignificant.

## Discussion

Worldwide, nasal packing is commonly practised after septoplasty to augment mucoperichondrial flap apposition and to facilitate closure of dead space.<sup>3</sup> The commonly used nasal packing materials are paraffin gauze, gauze impregnated with antibiotics, Vaseline gauze, bismuth iodoform paraffin paste,

fibrin glue, gelfoam, merocel, silastic sheets, and rarely glove fingers.<sup>10</sup>

We have used Merocel as a packing material in our study as it is comparatively easier to remove after surgery and does not cause foreign body reaction. However, nasal packing itself causes complications. As enlisted by Huang et al, the complications of packing include mucosal injury leading to septal perforation, displacement of packing material or its aspiration, allergic reaction, toxic shock syndrome, and occasionally eustachian tube dysfunction.<sup>11</sup>

In order to overcome these complications, Cukurova et al conducted a retrospective analysis of 697 septoplasty cases, and concluded that trans-septal suturing techniques used in septoplasty cause negligible pain and post-procedural complications, allowing patients to resume their routine day-to-day

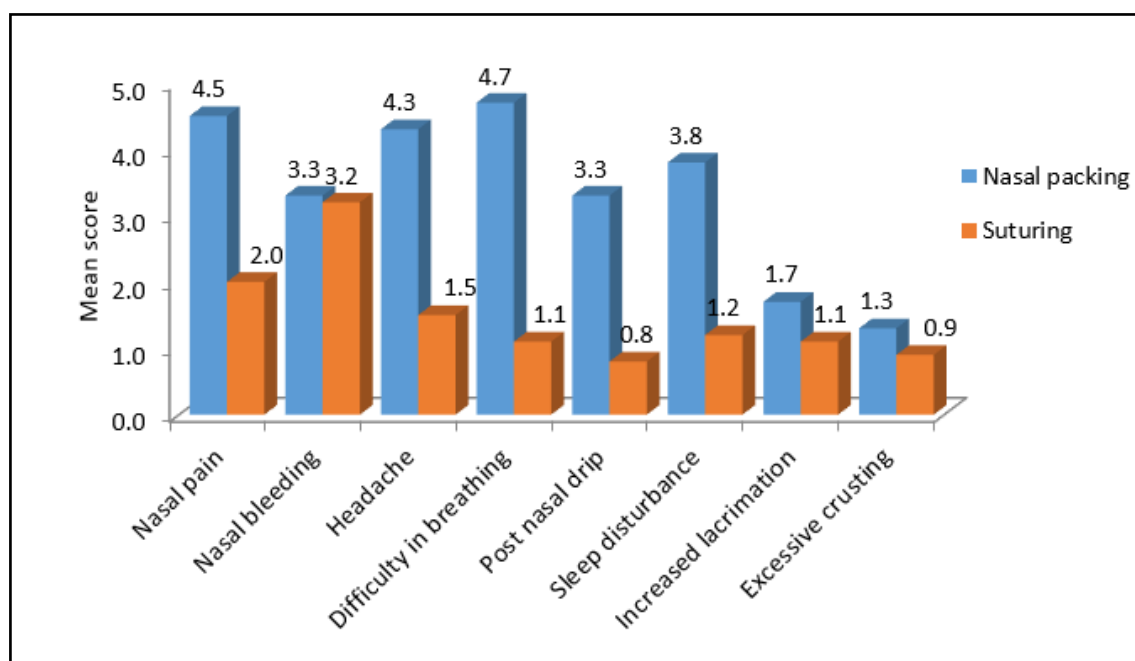


Fig. 6. Comparison of mean of visual analogue scores between the two groups

functions within a relatively short duration.<sup>12</sup> Their study affirmed that nasal packing is a risk-associated procedure having no justified reason for its continued use in routine practice, while concurrently emphasizing enhanced patient comfort after septoplasty if the suturing technique is practised.<sup>12</sup> Likewise, in our study, trans-septal suturing significantly reduced the incidence of post surgical nasal pain, headache, difficulty in breathing, post-nasal drip, sleep disturbance, and alleviated the concerns faced by the patient during pack removal.

Naik too, confirmed that intranasal packing lead to increased incidence of synechia and adhesions when compared with trans-septal through-and-through splint suturing in the Indian demographic.<sup>13</sup> Our study, on the contrary, was conducted with the intent to propose the efficacy of a more cost-effective procedure and still gives the desired result. Hence, for our study, trans-septal suturing was chosen as the parameter of comparison with packing, instead of more expensive alternatives available in the market, such as splints. We did not encounter any post-operative complications in either of the groups. Hence, we recommend the practice of placing

sutures to positively improve the quality of life of the patients while also relieving the financial burden on the patients presenting to a government setup.

Another drawback of nasal packing is that it tends to restrict the nasal component of respiration and thereby the overall respiratory function, rendering the quality of sleep to be impacted negatively.<sup>12</sup> This is implicated to reduced PaO<sub>2</sub> levels after bilateral nasal packing and the inadequate oral breathing during sleep, which causes hypoxia to be appreciated by the patient more in the nocturnal phase.<sup>12</sup> This is especially highlighted in elderly patients with underlying ischaemic heart diseases accompanying respiratory conditions such as obstructive sleep apnoea or chronic obstructive pulmonary disease.<sup>12</sup> Patients undergoing suturing suffered significantly reduced incidence of respiratory problems ( $p < 0.001$ ) along with a higher comfort score.<sup>14</sup> Likewise, in our study, sleep disturbance was significantly lesser ( $p < 0.004$ ) in trans-septal suturing group as compared to nasal packing. Patients with nasal packs confirmed that the presence of nasal obstruction, anxiety and headache caused them to develop sleep disturbance. Hence we effectively conclude that trans-septal

suturing alleviates the concerns and anxiety of patients and helps them to recuperate faster.

In a study done by Certal et al, packing and non-packing methods seemed to give equal incidence of postoperative risk of bleeding.<sup>15</sup> However, suturing techniques implicated a significant reduction in incidence of post-operative nasal pain as well as headache.<sup>15</sup> Similarly, post-operative bleeding in both groups were comparable in our study. Correction of grossly deviated septum and prominent spurs resulted in more incidence bleeding post-procedurally, irrespective of the group that the patient belonged to. However, nasal pain and headache were significantly relieved in trans-septal suturing group with  $p < 0.001$ , proving yet again the benefit of suturing over packing.

Though epiphora is mainly the result of nasolacrimal duct obstruction caused by packing, Abdulkhaliq et al proved in their study that there was no statistical difference between both the groups.<sup>16</sup> Even in our study, though epiphora was higher in the packing group, it was not found to be statistically significant on comparing with the suturing group.

What makes our study of great value is that not only does it extensively cover multiple parameters in its post-operative symptom assessment than ever done before in a single study; but it also evaluates the occurrence of post-nasal drip in relation to these two techniques, which has never previously been reported with respect to Indian population in literature. This renders our study pivotal as a benchmark for future studies of comparison in this aspect, eliciting a highly significant reduction of post-nasal discharge in patients who underwent trans-septal suturing ( $p$  value - 0.002). This also resulted in reduced hawking, throat irritation and coughing in patients leading to a symptom-free post-operative period.

Thus, while the long term impact and complications of the two methods are similar, we can conclude from our study that trans-septal suturing offers better quality of life to patients in the weeks following septoplasty due to its undeniable superiority in relieving symptomatic troubles. Hence, our study promotes its routine use in patients undergoing

septoplasty, rather than following traditional methods of packing, especially in the poor strata of the Indian society.

## Conclusion

Nasal pain, headache, dyspnoea, sleep disturbance, post – nasal drip, crusting, excessive lacrimation were reduced in the trans – septal suturing group as compared to packing. However, nasal bleeding was present in both the groups. Trans-septal suturing also alleviates pack removal problems like anxiety, pain, bleeding in a patient. It also proves to be a cost-effective modality and gives a better post-operative quality of life to patients. Hence, we recommend trans-septal suturing as the preferred method over anterior nasal packing in patients after septoplasty.

## References

1. Dubin MR, Pletcher SD. Postoperative packing after septoplasty: Is It Necessary? *Otolaryngol Clin North Am.* 2009; 42: 279-85
2. Von Schoenberg M, Robinson P, Ryan R. Nasal packing after routine nasal surgery -is it justified? *J Laryngol Otol.* 1993; 107: 902-5
3. Lemmens W, Lemkens P. Septal suturing following nasal septoplasty. A valid alternative for nasal packing? *Acta Otorhinolaryngol Belg.* 2001; 55:215-21
4. Yilmazer C, Sener M, Yilmaz I et al. Pre-emptive analgesia for removal of nasal packing: A double-blind placebo controlled study. *Auris Nasus Larynx* 2007; 34: 471-5
5. Samad I, Stevens HE, Maloney A. The efficacy of nasal septal surgery. *J Otolaryngol.* 1992; 21: 88-91
6. Taasan V, Wynne JW, Block AJ. The effect of nasal packing on sleep-disordered breathing and nocturnal oxygen desaturation. *Laryngoscope* 1981; 91: 1163-72
7. Sessions R. Membrane approximation by continuous mattress sutures following septoplasty. *Laryngoscope* 1984; 94: 702-3
8. Lee IN, Vukovic L. Hemostatic suture for septoplasty: how we do it. *J Otolaryngol* 1988; 17:54-6
9. Hari C, Marnane C, Wormald Peter-John. Quilting sutures for nasal septum. *J Laryngol Otol.* 2008; 122(5):522-3
10. Daneshrad P, Chin Gregory Y, Rice Dale H. Fibrin glue presents complications of septal surgery: findings in a series of 100 patients. *Ear Nose & Throat J.* 2003; 82:196-8
11. Huang IT, Podkomorska D, Murphy MN, Hoffer I.



- Toxic shock syndrome following septoplasty and partial turbinectomy. *J Otolaryngol.* 1976; 15:310-2
12. Cukurova I, Cetinkaya EA, Mercan GC, Demirhan E, Gumussoy M. Retrospective analysis of 697 septoplasty surgery cases: packing versus trans-septal suturing method. *Acta Otorhinolaryngol Ital.* 2012; 32(2):111-4
  13. Naik K. A Novel way of Trans-Septal Splint Suturing Without Nasal Packing for Septoplasty. *Indian J Otolaryngol Head Neck Surg.* 2015; 67(1):48-50 doi: 10.1007/s12070-014-0763-x. Epub 2014 Aug 10.
  14. Ali AP, Mahbobeh O, Shahrokh K. Comparison results of nasal septum suturing and nasal packing following septoplasty. *Romanian Journal of Rhinology.* 2019; 9(34): 97-99. DOI: 10.2478/rjr-2019-0012
  15. Certal V, Silva H, Santos T, Correia A, Carvalho C. Trans-septal suturing technique in septoplasty: a systematic review and meta-analysis. *Rhinology* 2012; 50(3):236-45
  16. Abdulkhaliq KA, Dashti AH, Ammar MSJ. Trans-septal suture versus intranasal silicone splint in septoplasty; *International Journal of Technical Research and Applications.* 2015; 3(3):159-65.