

Synchronous Buccal Carcinoma and Laryngeal Carcinoma- A Rare Presentation

<https://doi.org/10.47210/bjohns.2020.v28i2.325>

Ishita Sen,¹ Debangshu Ghosh,² Goutam Guha³

ABSTRACT

Introduction

Second primary malignancy as squamous cell carcinoma of larynx is rare after squamous cell carcinoma of buccal mucosa.

Case Report

A 47 year old male patient presented with a painless, progressive ulcer of left buccal mucosa near the angle of mouth for the last 3 months who also developed alteration in the quality of voice and respiratory distress 2 months later. On biopsy buccal lesion came out to be moderately differentiated squamous cell carcinoma. Direct laryngoscopy revealed a glottic growth and guided biopsy from the lesion revealed well differentiated keratinising squamous cell carcinoma which was managed successfully by total laryngectomy and buccal carcinoma by wide local excision followed by primary closure and supraomohyoid neck dissection in the same sitting.

Discussion

Having both index primary tumour and second primary tumour in head and neck region is a rare occurrence more so glottic carcinoma occurring synchronously with buccal carcinomas. Surgery is the mainstay of treatment in both the conditions.

Keywords

Neoplasms, Second Primary; Carcinoma, Squamous Cell; Larynx; Mouth Mucosa

Head and neck region are a harbour of malignancies with global incidence between 400,000 and 600,000 new cases per year and 223,000 and 300,000 yearly deaths.¹ Head and neck squamous cell carcinomas (HNSCC) incidence wise are the sixth leading human cancer worldwide.² More than 90% of these cancers arise from the mucosal surfaces of the oral cavity, oropharynx and larynx with oral cancer being by far more common in the Indian subcontinent.^{3,4}

Second primary malignancy (SPM) is a common entity in the head and neck region. Multiple primaries are seen in about 9.7% of head and neck cancer patients.

Multiple malignancies can be of two types; synchronous when the second primary neoplasm (SPN) is diagnosed within 2-6 months of diagnosis of index tumour or metachronous, if the second primary tumour is diagnosed 6 months following diagnosis of primary tumour.^{5,6} Out of the multiple primary malignancies in the head and neck region, 46.9% present as synchronous.⁷ The criteria used for diagnosis of multiple primary cancers was first given by Warren and Gates, which are:

1. Each of the tumours must be malignant, being confirmed on histology.
2. Each must be geographically separate and distinct. The lesions should be separated by normal mucosa.
3. Probability of one being the metastasis of the

1 - Department of Otolaryngology, Suri Multispeciality Hospital, Suri, Birbhum

2 - Department of Otolaryngology, Deben Mahato Government Medical College Hospital, Purulia

3 - Department of Plastic and Reconstructive Surgery, I.P.G.M.E.R & S.S.K.M. Hospital, Kolkata

Corresponding author:

Dr Debangshu Ghosh

email: ghoshdr.d777@ymail.com

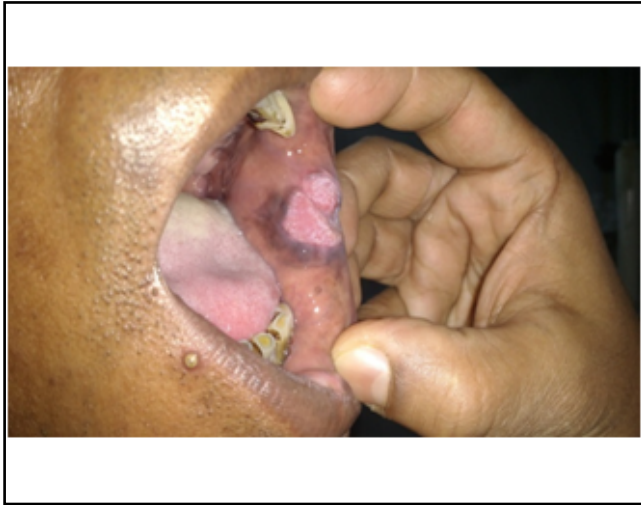

Fig. 1. Appearance of the buccal lesion before treatment

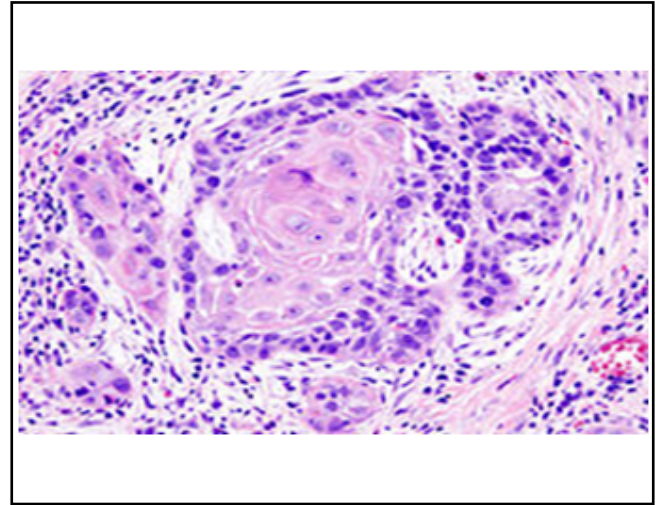


Fig. 2. Histopathological picture of moderately differentiated squamous cell carcinoma of buccal mucosa (H & E, 10X)

other must be excluded.

It was modified later by Moertel et al (1961), Curtis and Ries (2006) and Morris et al (2010).⁸ The most common site of second malignancy following index primary tumour in head and neck is breast and gastrointestinal system followed by lungs.⁹ Our case in this report has both the tumours in the head and neck region with the index tumour in the oral cavity and the SPT in the larynx.

Case Report

A 47-year old male presented to ENT department with complaints of an ulcerative lesion in the left buccal mucosa, near the angle of mouth for 3 months. The ulcer was insidious in onset, gradually increasing in size and painless. The patient had a history smoking twenty bidis a day for last twenty years. On examination the ulcerative lesion being 2.5×3 cm. in size and had rolled out, discontinuous margins, indurated base with melanoplakia of surrounding mucosa. Skin of the cheek was free on palpation and easily pinchable. No enlarged neck node could be palpated. Thus overall TNM stage becomes T2N0M0. The patient was then planned for wedge biopsy from the lesion including its margin. The histopathological examination (HPE) report came out to be moderately differentiated squamous cell carcinoma.

The patient was then planned for wide local excision of the buccal carcinoma with 1.5 cm margin followed by primary repair in collaboration with department of plastic surgery as the presumed need for commissuroplasty and left supraomohyoid neck dissection in this clinically N0 neck.

In the meantime when the patient was being prepared for that planned surgery he started to develop hoarseness of voice, episodes of respiratory distress and aspiration of food materials for 2 months following the appearance of the oral ulcer. Fiberoptic Laryngoscopic (FOL) findings using a 8 mm 70° rigid laryngoscope, revealed a growth involving the right vocal cord, right aryepiglottic fold, anterior commissure, right false cord, anterior part of the left vocal cord. Right hemi-larynx was fixed. Glottic chink was narrow. CECT scan of neck including larynx revealed a growth involving right vocal cord, right aryepiglottic fold, anterior commissure with compromised airway. Breach was seen in the inner lamina of the thyroid cartilage with no involvement of the neck structures and no lymphadenopathy. Metastatic workup was negative and hence the TNM stage was Stage-III (T3N0M0). The patient was planned for direct laryngoscopy and biopsy from representative areas of growth in the department of ENT.

Direct laryngoscopy was done after a high tracheostomy and the HPE result of biopsy specimen

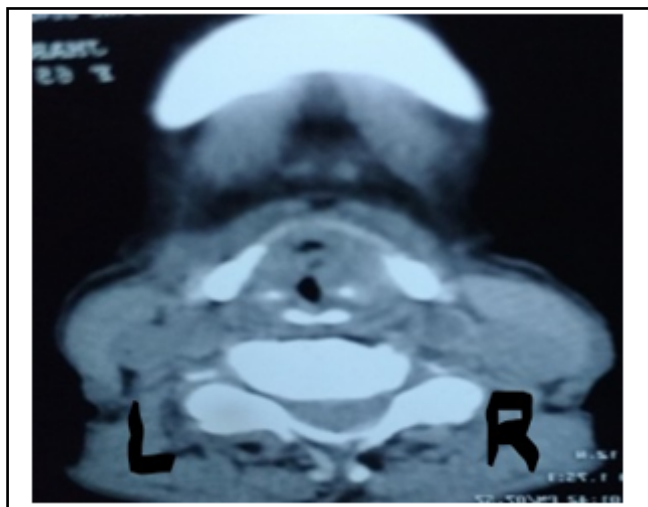

Fig. 3. CECT scan of neck and larynx at the level of thyroid ala showing cartilage breach on right side

came out to be well differentiated keratinizing squamous cell carcinoma. The patient was then planned for total laryngectomy as in this T3 glottic disease with dysfunctional larynx in the same sitting with excision of buccal carcinoma followed by repair and neck dissection and adjuvant radiotherapy and the patient party counselled likewise with informed consent taken. Total laryngectomy was done by conventional technique using Gluck-Sorenson incision and the usual postoperative period was uneventful. The patient was discharged after two weeks. The patient was followed up in the OPD after three weeks of surgery with HPE report of the specimens of total laryngectomy, excised buccal mucosa and supraomohyoid neck dissection. The HPE report of excised buccal mucosa specimen was moderately differentiated non keratinizing squamous cell carcinoma with depth of invasion less than 5mm and margins were free from tumour, laryngectomy specimen was well differentiated keratinizing squamous cell carcinoma, neck dissection specimen was deep fascia and no lymph node sample detected. The patient during the postoperative period had normal oral stoma with adequate mouth opening and the neck wound was healthy with patent airway (adequate permanent tracheostoma). The patient was then referred for external beam radiation therapy and he was thereafter followed up every 1 month for 3 months and thereafter

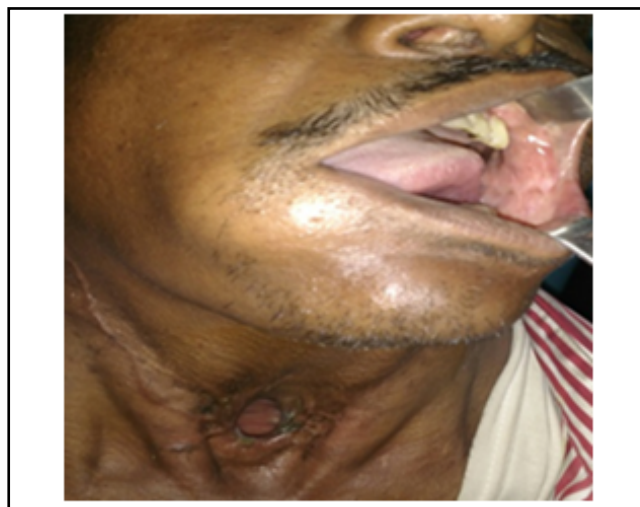

Fig. 4. Postoperative follow up showing healed permanent tracheostome and buccal lesion after excision

every 6 months. The postoperative period till now has been uneventful.

Discussion

The first case of synchronous cancers was reported by Billroth in 1889. That was a case of stomach cancer and second primary in external ear. Development of multiple malignant lesions can be explained by the phenomenon of “field of cancerization”, that occurs in the aerodigestive tract mucosa at this level when exposed to the same type of carcinogens if they act consistently for a prolonged period of time.¹⁰ Tobacco is a common risk factor responsible for the occurrence of both laryngeal carcinoma and buccal carcinoma and our reported case can be explained by theory of the “field of cancerization”.

Buccal carcinoma arises from the overlying epithelium with its higher rate attributed to the widespread practice of betel nut chewing. It generally presents as a slow growing mass on the buccal mucosa. Associated symptoms are pain, bleeding, sensory deficit, dysphagia, odynophagia, trismus, facial palsy. The neck and parotid gland are palpated for lymphadenopathy. According to Diaz et al, 27 percent patients presented with clinically positive neck nodes in their study.¹¹ A meta-analysis by Chhetri et al involving four studies on

223 patients whereby in most T-stage were either T2 or T3.¹² Early lesions are managed by wide local excision by transoral route with at least 1 cm margin, whereas advanced lesions are excised and reconstructed with a cheek flap.

Min et al from their study on Korean population found standardised incidence ratio of SPN among oral cancer survivors was 1.47. Index oral cancer subsite was mainly floor of mouth (1.95) followed by gingiva (1.30). Most of the second cancers were associated with radiation history (1.94). The incidence of SPN was highest between 6 and 23 months after index oral cancers.¹³ In a study by Sassi et al on Brazilian population most common index tumour site was the floor of mouth (43.2%) followed by buccal mucosa (2.7%). Most primary tumours were diagnosed at an advanced stage (stage 4 > stage 3). The most common site of SPN was oral cavity (40.5%) followed by oesophagus (16.2%) and larynx (8.1%). The average interval between diagnosis of first primary tumour and SPN was 65 months.¹⁴ Rajani et al in their study on a group of Indian people showed the most common subsites of oral cancer leading to SPN were lower gingivobuccal sulcus followed by palate, tongue and buccal mucosa.¹⁵

Hoarseness of voice is a usual presenting feature of early stage glottic carcinoma while dysphagia and aspiration present late in the course. Early stage disease does not have lymph node metastasis whereas, metastasis to pretracheal lymph nodes occur following subglottic extension. Early glottic carcinomas are managed by radiotherapy, endoscopic laser excision or conservative laryngeal surgery. Moderately advanced lesions (T3) are usually treated with chemoradiation until and unless there are features of laryngeal dysfunction. T4 (T4a) lesions are treated by total laryngectomy with central compartment neck dissection. Ghosh et al in such a rare case report opined that if surgery is needed for both the tumours, it can be done in a single stage in majority of the cases with low mortality and morbidity.¹⁶ In our case too, we performed surgeries for both conditions in a single sitting.

The case being reported here is unusual as: (a) In our case the index tumour is in the buccal mucosa which isn't the most common site when compared with other studies. (b) Most of the SPNs present after 6 months

as described in the above studies whereas our case is that of a synchronous secondary tumour. (c) Most of the cases of SPN have been found to be diagnosed at an advanced stage, whereas in our case the index buccal cancer belongs to early stage. (d) Most commonly reported SPN for oral carcinoma is the oral cavity itself but here second malignancy was in the larynx which is rare. (e) SPN for oral carcinomas have mostly been found in previously irradiated cases whereas in our case had no such history. (f) Most common laryngeal cancer associated with oral carcinoma is supraglottic carcinomas whereas our case it was glottic carcinoma.

References

1. Chaturvedi A K, Anderson W F, Lortet-Tieulent J, Curado M P, Ferlay J, Franceschi S, Rosenberg P S, Bray F, and Gillison M L. Worldwide Trends in Incidence Rates for Oral Cavity and Oropharyngeal Cancers. *J Clin Oncol.* 2013; 31(36):4550-4559
2. Jemal A, Siegel R, Ward E, Murray T, Xu J, Thun M J. Cancer statistics. *CA Cancer J Clin.* 2007;57(1):43-66
3. Vigneswaran N, Michelle D. Williams. Epidemiological Trends in Head and Neck Cancer and Aids in Diagnosis. *Oral Maxillofac Surg Clin North Am.* 2014; 26(2): 123-41
4. Lambert R, Sauvaget C, de Camargo Cancela M, Sankaranarayanan R. Epidemiology of cancer from the oral cavity and oropharynx. *Eur J Gastroenterol Hepatol.* 2011; 23:633
5. Mehdi I, Shah AH, Moona MS, et al. Synchronous and metachronous malignant tumours expect the unexpected. *J Pak Med Assoc.* 2010; 60(11):905-9
6. Morris L G, Sikora A Gg, Patel S G, Hayes R B, Ganly I. Second primary cancers after an index head and neck cancer: subsite-specific trends in the era of human papillomavirus-associated oropharyngeal cancer. *J. Clin. Oncol.* 2011; 29(6):739-46
7. Krishnatreya M, Rahman T, Katakaki A C, Das A, Das A K, Lahkar K. Synchronous primary cancers of the head and neck region and upper aero digestive tract: Defining high-risk patients. *Indian J Cancer* 2013;50:322-6
8. Warren S, Gates O. Multiple primary malignant tumours: A survey of the literature and statistical study. *Am J. Cancer.* 1932; 16:1358-414
9. Bagri P K, Singh D, Bardia M R. Double Primary Malignancies: A Clinical & Pathological Analysis Report from Regional Cancer Institute in India. *Iran J Cancer Prev.* 2014 Spring7(2)
10. Slaughter D P, Southwick H W, Smejkal W. Field cancerization in oral stratified squamous epithelium; clinical implications of multicentric origin. *Cancer* 1953; 6(5):963-8
11. Diaz E M Jr, Holsinger F Cc, Zungia E R, et al. Squamous cell

- carcinoma of the buccal mucosa: one institution's experience with 119 previously untreated patients. *Head Neck*. 2003; Apr. 25(4):267-73
12. Chhetri D K, Rawnsley J D, Calcaterra T C. Carcinoma of the buccal mucosa. *Otolaryngol Head Neck Surg*. 2000; 123(5):566-71
 13. Min SK, Choi SW, Lim J, Park JY, Jung KW, Won YJ. Second primary cancers in patients with oral cavity cancer included in the Korea Central Cancer Registry. *Oral Oncol*. 2019; 95:16-28. doi:10.1016/j.oraloncology.2019.05.025
 14. Sassi L M, Cervantes O, Schussel J L, Stramandinoli R T, Guebur M I, Ramos G H A. Incidence of second primary oral cancer tumours: a retrospective study. *Rev. Oconto ciênc*. 2010; 25(4):367-70
 15. Rajani B C, Hoda N , Dikhit P S, Roy S. Incidence of Second Primary Tumor in Patients with Oral Squamous Cell Carcinoma: Experience from a Tertiary Cancer Centre. *IOSR Journal of Dental and Medical Sciences*. (IOSR-JDMS) 2019; 18(8):72-4
 16. Ghosh D, Sannigrahi R, Basu S K, Basu P. Synchronous squamous cell carcinoma of external acoustic meatus following pigmented basal cell carcinoma of cheek -a rare occurrence. *Bengal Journal of Otolaryngology and Head Neck Surgery* 2015; 23(3):123-8.