

# Eagle Syndrome - An Entity Often Misdiagnosed

<https://doi.org/10.47210/bjohns.2020.v28i2.333>

Puneeth S Nayak,<sup>1</sup> Anil Kumar S Harugop,<sup>1</sup> Paramita Debnath,<sup>1</sup> Prashant H Patil<sup>1</sup>

## ABSTRACT

### **Introduction**

Throat pain is one of the most common complaints that an otolaryngologist encounters in daily practice, there can be numerous aetiologies to it. Eagle Syndrome is one such entity which is characterized by chronic throat pain due to elongation of the styloid process or mineralization of the stylohyoid ligament. The vague symptomatology of this condition often leads to delayed diagnosis and treatment.

### **Case Reports**

We report 5 cases of Eagle Syndrome. All the patients presented to us with complaints of chronic throat radiating to neck which did not relieve on taking medications, for the same they have been consulting multiple specialities. The diagnosis of Eagle Syndrome was confirmed by palpation in tonsillar fossa and orthopantomogram revealed enlarged styloid process measuring more than 30mm. Upon confirmation, all the 5 patients underwent tonsillo-styloidectomy and on consequent follow ups, they were symptomatically improved.

### **Discussion**

Eagle Syndrome is a diagnosis of exclusion and should raise high index of suspicion in patients with nonspecific throat and neck pain not responding to any conservative treatment. With an increasing incidence of side effects following injudicious treatment given in such cases, this condition requires attention, as it a rare entity and often misdiagnosed.

### **Keywords**

Eagle Syndrome

Eagle syndrome is a clinical entity that is often misdiagnosed. It is a constellation of signs that occurs due to elongated styloid process or as a result of mineralization of the stylohyoid or stylomandibular ligament, also known as Long Styloid Process Syndrome or Styloid Process Neuralgia.<sup>1</sup> The term was coined by W. Eagle, an otolaryngologist in the year 1937.

The symptoms often vary from throat pain to chronic neck pain that doesn't relieve on medications, thus becomes one of the main differential diagnoses of chronic throat and neck pain. Affects approximately 4%

of population out of which only 4% are symptomatic thus diagnosing it becomes challenging and is often misdiagnosed owing its vague symptomatology.<sup>2</sup>

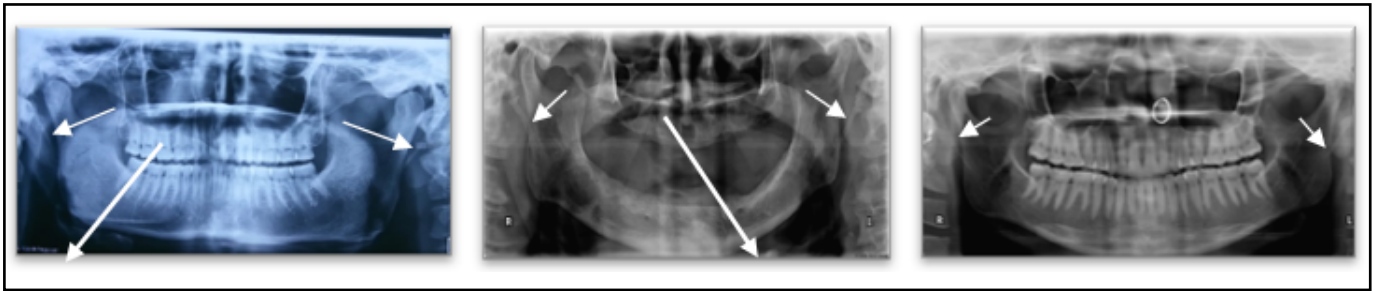
As a result, it becomes troublesome for the patient as he pays multiple visits to multiple specialities which leads to delayed diagnosis and treatment. Patient is prescribed unnecessary analgesics and antibiotics which predisposes him to laryngopharyngeal disease. However, palpable styloid process in tonsillar fossa with radiological evidence of the elongated styloid process accomplishes the diagnosis.

Tonsillo-styloidectomy remains the main stay of treatment for Eagle Syndrome with a high success rate as there are no recurrences.<sup>3</sup>

1 - Department of ENT, Jawaharlal Nehru Medical College, KLE University, Belagavi, Karnataka

### **Corresponding author:**

Dr Paramita Debnath  
email: paramitadebnath74@gmail.com



**Fig. 1.** Orthopantomogram showing elongated styloid process of our patients

## Case Reports

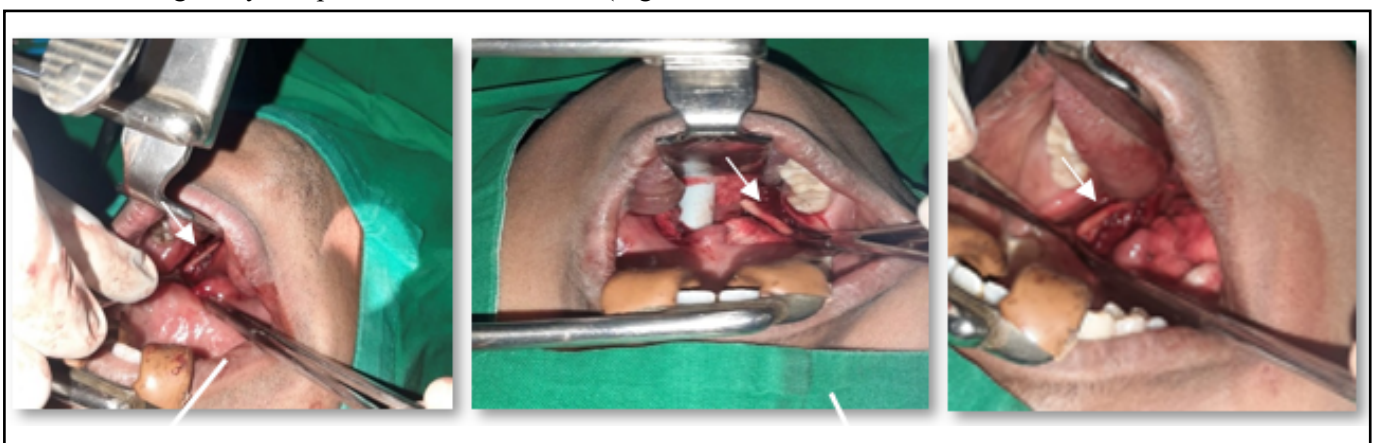
### Case 1

A 30-year-old male presented to us with complaints of intermittent throat pain associated with pain in the neck for 1 year, with history of low-grade fever. Patient gave history of visiting multiple specialities for the same complaints before he came to us. ENT examination revealed bilateral grade 1 tonsillar hypertrophy, on bimanual examination bilateral bony prominences were palpable in tonsillar fossa. Orthopantomogram revealed bilateral enlargement of styloid process measuring 40.5mm on right side and 60.2mm on left side. (Fig 1) Diagnosis of stylalgia was confirmed and was started on analgesics and preoperative evaluation was done. Following which the patient underwent bilateral tonsillo-styloidectomy (Fig. 2) by an intra oral approach and bilateral enlarged styloid process were removed. (Fig.

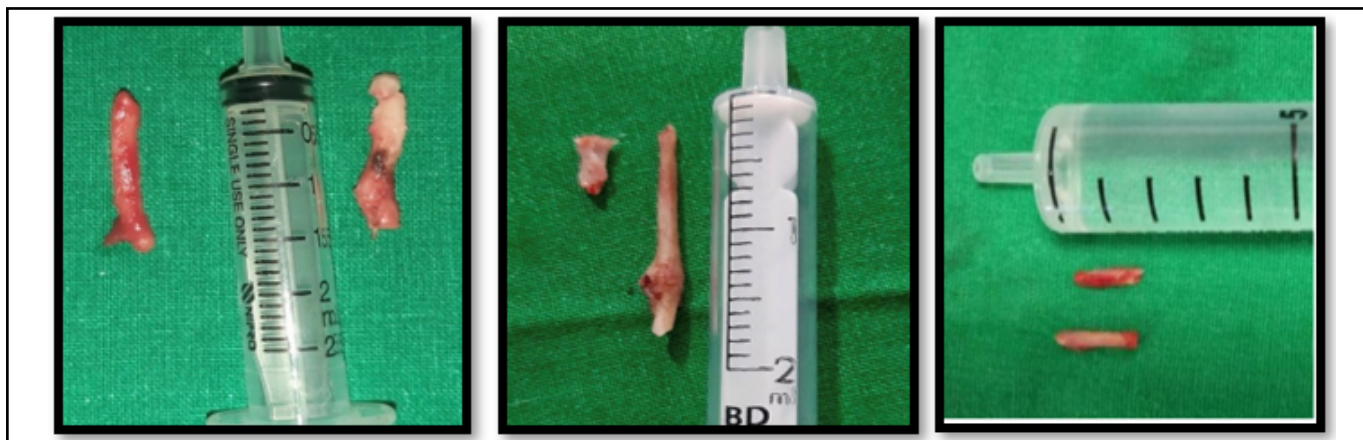3) On regular follow ups on day 7, day 14, and 1 month post-surgery, the patient symptomatically improved.

### Case 2

38-year-old female presented to us with complaints of right sided dull aching throat pain radiating to neck, right ear and foreign body sensation in throat for 6 months. ENT examination revealed tenderness over bilateral tonsillar fossa with palpable bony prominences. Orthopantomogram revealed bilateral elongated styloid process measuring right side 46.4mm, left side 48.8mm (Fig. 1). The diagnosis of Eagle Syndrome was thus accomplished. Initially patient was treated conservatively with analgesics but showed no improvement. Following which she underwent bilateral tonsillo-styloidectomy (Fig. 2) which showed bilateral enlarged styloid process (Fig. 3). Patient was discharged



**Fig. 2.** Intra operative picture showing enlarged styloid process



**Fig.3. Post operative specimen of styloid process after tonsillo-styloidectomy**

with oral antibiotics and analgesics, followed up on day 7, day 14 and 1-month following surgery and she showed prompt relief of symptoms.

#### Case 3

A 42-year-old female patient came to us with complaints of persisting nagging pain over the right side of the throat radiating to face and ipsilateral ear for the last 2 years and not relieved by any analgesics and antidepressants. She was examined by Oro-maxillo-facial surgeon and Neurologist elsewhere and found to be clinically normal. ENT examination here showed normal oropharynx on inspection. But a bony mass was palpable in bilateral tonsillar fossa and was tender, which again confirmed the site of pain. The diagnosis of stylalgia was confirmed by taking an orthopantomogram which revealed bilateral enlarged styloid process measuring 40mm on right and 42mm left side respectively. A course of conservative management with carbamazepine was tried but only temporary relief was noticed. She underwent tonsillo-styloidectomy (Fig. 3) after pre-operative evaluation. Patient was regularly followed up on day 7, day 14, and 1-month post-surgery was found to be symptom free.

#### Case 4

A 34-year-old male presented to us with complaints of intermittent dull aching throat pain associated with pain in the neck for 1 year. Patient has been visiting various

doctors for the same complaints before he came to us. On ENT examination bimanual examination bilateral tenderness was present in bilateral tonsillar fossa. Orthopantomogram revealed bilateral enlargement of styloid process measuring 30.5mm on right side and 31.6mm on left side. (Fig. 1) He was started on analgesics and preoperative evaluation was done, once diagnosis was confirmed. Following which the patient underwent bilateral tonsillo-styloidectomy (Fig. 2) by an intra oral approach and bilateral enlarged styloid process were removed (Fig. 3). Following surgery patient had regular follow ups on day 7, day 14 and 1 month and had symptomatic relief of symptoms.

#### Case 5

A 40-year-old female presented to us with complaints of dull aching throat pain radiating to neck, both ears and foreign body sensation in throat for 8 months which did not relieve on taking medications. ENT examination revealed tenderness over bilateral tonsillar fossa with palpable bony prominences. Orthopantomogram was done and the findings were: bilateral elongated styloid process measuring right side 35.4mm, left side 32 mm (Fig. 1). Based on the imaging findings and clinical examination, the diagnosis of Eagle Syndrome was thus accomplished. Initially patient was treated conservatively with analgesics but showed no improvement. Following which she underwent bilateral tonsillo-styloidectomy which showed bilateral enlarged styloid process (Fig.

3). Patient was discharged with oral antibiotics and analgesics, followed up on day 7, day 14- and 1-month post-surgery and she showed drastic relief of symptoms.

## Discussion

Eagle Syndrome refers to a constellation of signs and symptoms that occurs due to elongated styloid process or as a result of mineralization of the stylohyoid or stylomandibular ligament, also known as Long Styloid Process Syndrome or Styloid Process Neuralgia.<sup>1</sup>

The styloid process is an elongated projection which originates from the petrous part of temporal bone, medially and anteriorly to the stylomastoid foramen, between the internal and external carotid arteries, and laterally to the tonsillar fossa. Embryologically derived from Reichert's cartilage from the second branchial arch.<sup>3</sup> The normal length of the styloid process is 20–30 mm and it is said to be elongated when it is 30 mm or longer. 4% of world population is affected out of which only 4 % are symptomatic thus diagnosing it becomes challenging. It is frequently seen in females between 30-50 years.<sup>2</sup>

First described in literature by Lucke and Weinlecher in 1872 while in 1937 American otorhinolaryngologist W. Eagle described it as a syndrome complex mainly in two varieties. The classical variety that presents as throat pain with referred otalgia and foreign body sensation in the throat. The carotid artery variety in which styloid process compresses the carotid artery leads which to carotidynia, headache and dizziness.<sup>4</sup>

Several theories have been postulated regarding the etiology of Eagle Syndrome, the most accepted one being the growth of the osseous tissue along stylohyoid ligament.

Symptomatically it presents with throat pain, chronic neck pain, facial pain, odynophagia, throat pain radiating to ear, foreign body sensation in throat and neuralgic pain. Owing to such vague and varied symptoms the diagnosis is often delayed, misdiagnosed and it makes it troublesome for the patient as they undergo unnecessary investigations. It also makes the patient vulnerable for laryngopharyngeal reflex and allergic rhinitis symptoms.<sup>5</sup>

Differential diagnosis of Eagle Syndrome should include trigeminal neuralgia, migraine, temporomandibular joint disorders, temporal arteritis, unerupted or impacted molar teeth and faulty dental prostheses. As we proceed towards the treatment the differential diagnosis has to be kept in mind and thus making it a diagnosis of exclusion and should be considered as one of the important causes in the differential diagnosis of orofacial pain.

This syndrome is also known as glossopharyngeal neuralgia as it compresses the glossopharyngeal nerve along its course over the elongated styloid process leading to glossopharyngeal neuralgia. Thus, when we evaluate cases referred for glossopharyngeal neuralgia, the diagnosis of Eagle Syndrome should be kept in mind.<sup>5</sup>

Accomplishment of diagnosis of this syndrome thus necessitates a thorough clinical examination that includes proper history, bimanual palpation of tonsillar fossa for elongated styloid followed by radiological evaluation-Orthopantomogram or X-ray Towne's view.<sup>6</sup>

The treatment options for this syndrome includes both surgical and non-surgical approach. Conservatively in mild to moderate cases the patient can be treated with analgesics, anti-convulsant, anti-depressants and local injection of steroids in the tonsillar fossa but often there is temporary relief of symptoms with this line of management. And it thus necessitates a surgical approach, tonsillo-styloidectomy which remains the gold standard treatment modality as it provides prompt relief of symptoms with a high success rate.<sup>7,8,9</sup>

In our current case series, all the 4 patients presented to us with complaints of chronic throat pain radiating to neck, the condition was initially misdiagnosed and the patients were referred to different specialities which not only was troublesome but also affected the quality of their life. Following the confirmation of the diagnosis of Eagle Syndrome by palpation in tonsillar fossa and radiographically, we planned surgical excision because the patient's symptoms were severe and did not respond to medical management. As both elongated styloid processes were quite enlarged in all 4 cases, we performed tonsillo styloidectomy. All the patients responded well to the procedure and were symptom free upon repeated

follow up. Thus surgical management remains the gold standard of treatment for this syndrome.

### Conclusion

Eagle Syndrome is a condition that is rare but often it is misdiagnosed owing to this vague and varied symptomology and that leads to delayed diagnosis and prompt treatment. It is a diagnosis of exclusion and should raise high index of suspicion in patients with nonspecific throat and neck pain not responding to any conservative treatment.

### References

1. Malik JN, Monga S, Sharma AP, Nabi N, Naseeruddin K. Stylalgia revisited: clinical profile and management. *Iran J Otorhinolaryngol.* 2018;30(6):335-40
2. Sharma P, Shekhar S, Bajpayi BB, Kumar S, Pal PNP. Eagle's syndrome - A rare entity but not so uncommon alleviating pain and symptomatology. *IOSR J Dental Med Sci.* 2017;16(5):31-2
3. Moon CS, Lee BS, Kwon YD, et al. Eagle's syndrome: a case report. *J Korean Assoc Oral Maxillofac Surg.* 2014; 40(1):43-7. doi:10.5125/jkaoms.2014.40.1.43
4. K. C. Prasad, M. P. Kamath et al. Elongated styloid process (Eagle's syndrome): A clinical study. *J Oral Maxillofac Surg.* 2002; 60(2):171-5
5. Slavin KV. Eagle syndrome: entrapment of glossopharyngeal nerve. *Journal of Neurosurgery* 2020; 97 (1) :216-8
6. Mishra A, Dabholkar J, Lodha J, Sharma A, Mhashal S. Stylalgia: A Missed Diagnosis. *Otolaryngol Pol.* 2015;69(2):34-37. doi:10.5604/00306657.1131148
7. Taheri A, Firouzi-Marani S, Khoshbin M. Nonsurgical treatment of stylohyoid (Eagle) syndrome: a case report. *J Korean Assoc Oral Maxillofac Surg.* 2014; 40:246-9
8. Han MK, Kim DW, Yang JY. Non Surgical Treatment of Eagle's Syndrome - A Case Report -. *Korean J Pain.* 2013; 26(2):169-172. doi:10.3344/kjp.2013.26.2.169
9. Naik SM, Naik SS. Tonsillo-Styloidectomy for Eagle's Syndrome: A Review of 15 Cases in KVG Medical College Sullia. *Oman Medical Journal* 2011; 26(2): 122-6.