

Diagnostic Accuracy of FNAC Diagnosed Benign Thyroid Lesions Compared with Post-Operative Histopathology Results

<https://doi.org/10.47210/bjohns.2020.v28i2.336>

Santosh UP,¹ Shreelakshmi V,¹ Sanjay VC¹

ABSTRACT

Introduction

Fine Needle Aspiration Cytology (FNAC) is one of the important diagnostic tools in diagnosing the thyroid diseases, however incidental thyroid malignancies among patients operated for a benign thyroid disease is not infrequent. The incidence ranges between 3 and 16%. The clinical significance of these tumours cannot be ignored once a correct staging has been carried out. The objectives of this study were to assess the diagnostic accuracy of FNAC of Thyroid gland and to know the incidence of incidental thyroid malignancy.

Materials and Methods

This was a prospective study conducted from August 2018 to December 2019, after taking institutional ethical clearance, with a study population of 72 patients with thyroid swelling of either sex between age group (18-72yrs). Pre operative FNAC was done and underwent thyroid surgery in our hospital. Post operative thyroid specimen were sent for histopathological examination. All reports were collected and analyzed statistically.

Results

Total 72 patients were included within age group of 18-72yrs among them, 8 were males and 64 were females having biologically normal thyroid function test. FNAC was showed 91% sensitivity and 68% specificity in diagnosing the colloid goiter and also 62% sensitivity and 75% specificity in diagnosing the nodular goitre. However, 8(11.1%) patients were showing incidental thyroid malignancy postoperatively.

Conclusion

FNAC is an effective tool in diagnosing the thyroid diseases; however incidental thyroid malignancy should also be considered and correlated with clinical diagnosis.

Keywords

FNAC; Thyroid Neoplasms; Sensitivity and Specificity; Data Accuracy

The burden of thyroid disease in the general population is enormous. Thyroid disorders are the most common among all the endocrine diseases in India. Thyroid nodules are most often be only benign or can be associated with malignancy or develop malignancy over a period of time. Most of the thyroid nodules are benign and fewer than 5% of them are actually malignant. Of all patients with grave's disease, approximately 30% presents with palpable or radiological nodules. Out of which malignant potential is present in 17% as compared to incidence of 5% usually found in the general population. Many cases treated as Hashimoto's thyroiditis may have an associated malignancy. FNAC

of the thyroid gland is safe, inexpensive, minimally invasive, and highly accurate in the diagnosis of nodular thyroid disease.

Though FNAC has revolutionized the management of thyroid nodule, the accuracy of cytological diagnosis is highly dependent on the person performing the aspiration and the person interpreting it. Analysis of

1 - Department of Otorhinolaryngology, JJM Medical College, Davangere

Corresponding author:

Dr Sanjay VC

email: sanjay.shetty.vijapur@gmail.com

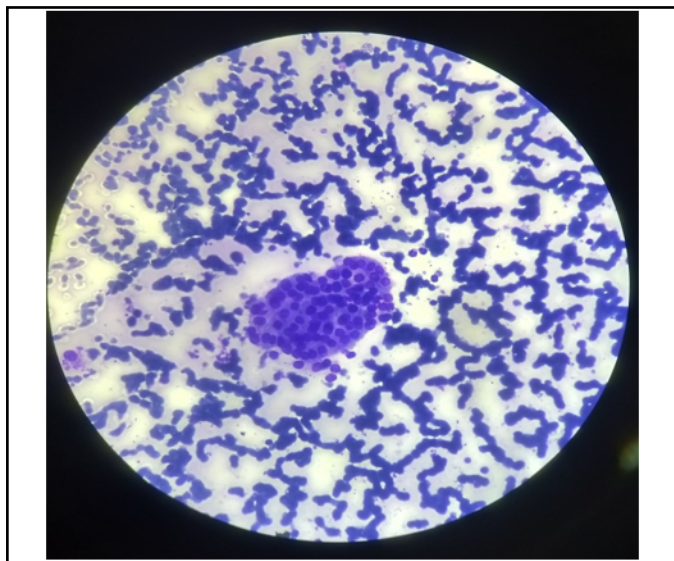


Fig.1. FNAC showing nodular goitre of a patient with thyroid swelling (H&E, 40x)

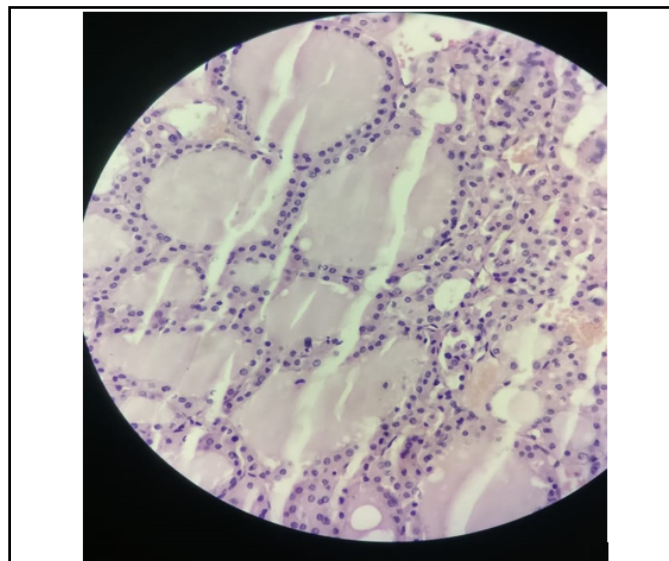


Fig.2. Postoperative histopathology showing nodular goitre of the Fig.1 (H&E, 40x)

recent data suggests a false-negative rate of 1-11%, a false-positive rate of 1-8%, a sensitivity of 65% to 98%, and a specificity of 72% to 100%.¹ Studies show that 2–15% of FNAC are insufficient to diagnose, 50–70% benign, 15–30% suspicious and 5–10% malignant.² Limitations of FNAC are related to the skills of the

aspirator, the experience of the cytologist, and the difficulty in distinguishing some benign cellular adenomas from their malignant counterparts. This is a study for assessing the diagnostic accuracy of fine needle aspiration cytology diagnosed benign thyroid lesions with post operative histopathology results and to

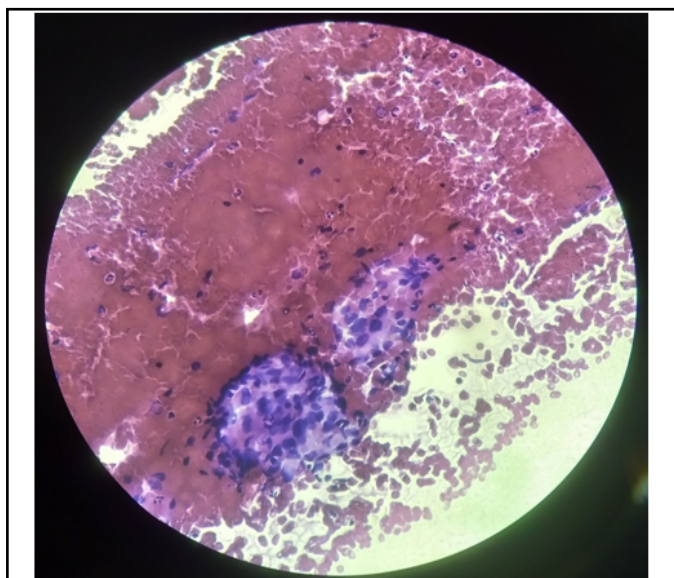


Fig. 3. FNAC showing colloid nodular goitre of a patient with thyroid swelling (H&E, 40x)

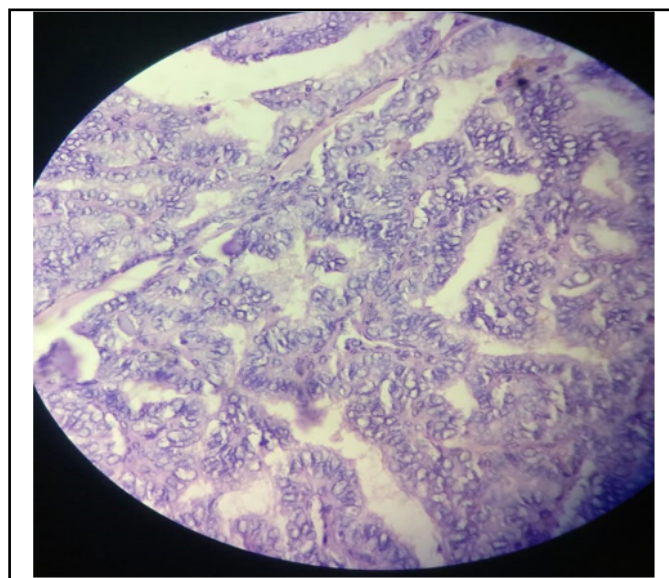


Fig.4. Postoperative Histopathology Showing Micro Papillary Carcinoma (H&E, 40x)

Table I: Diagnostic Accuracy of FNAC of Nodular Goitre compared with HPE

FNAC	HPE		TOTAL
	COLLOID GOITRE	OTHERS	
Colloid Goitre	20(91%)	16	36
Others	2	34(68%)	36
Total	22	50	72

identify the incidence of incidental thyroid malignancy post operatively in patients treated surgically for FNAC proved benign thyroid disease.

Materials and Methods

This prospective study was carried out on patients with thyroid swelling, of either sex between age group (18-72 years) who, considering the inclusion and exclusion criteria, agreed to participate in study were included. Inclusion criteria includes, all the patients with thyroid swelling undergoing thyroid surgery, where FNAC, prior to thyroid surgery, showed benign thyroid disease. Exclusion criteria excludes, all the patients undergoing thyroid surgery, where FNAC prior to surgery showed malignant thyroid disease. This study was done from August 2018 to December 2019 with a sample size of 72 and sampling method being convenience sampling. After detailed history and examination of the patients, pre-operative investigations and FNAC was done and consent for surgery was taken and underwent Thyroidectomy. All patients underwent intracapsular thyroidectomy. Specimen sent for Histopathological examination and reports were collected and statistical

analysis was done. Categorical data is represented in the form of percentages. Statistical tests applied are Correlation, Sensitivity, Specificity, Positive Predictive Value, Negative Predictive Value, Accuracy.

Results

Data analysis was done with the software IBM SPSS Version 22.0 for Windows.

In our study, 72 patients were included of which, 8 patients were male and 64 were female with age group between 18-72 years. The mean age of the study patients was 39.9 ± 12.3 years. All patients were having normal biochemical thyroid function tests. Fine needle aspiration cytology (FNAC) of thyroid was done in all patients; of 72 patients' specimens, 36(50%) were having colloid goitre, 30(42%) were having nodular goitre, 2(2.81%) were having Hashimoto's thyroiditis and 4(5.63%) patients were having Adenomatous nodule. After the final histopathology, of 72 patients' specimens, 22(30.5%) specimens showed Colloid goitre, 28(39%) specimens showed Nodular goitre, 4(5.63%) specimens showed Hashimoto's thyroiditis, 5 had lymphocytic thyroiditis, 3 specimens showed follicular adenoma, 2

Table II: Diagnostic Accuracy of Fnac of Nodular Goitre compared with HPE

FNAC	HPE		TOTAL
	NODULAR GOITRE	OTHERS	
Nodular Goitre	13(62%)	13	26
Others	8	38(75%)	46
Total	21	51	72

specimen showed adenomatous nodule and 8(11.1%) patients specimen showed malignancy features, 6 had papillary carcinoma and 1 each had follicular and medullary carcinoma. FNAC accuracy in diagnosing the nodular goitre and colloid goitre was calculated statistically. (Table I & II) Incidental thyroid malignancy was 11.1% which can be comparable with other studies.

Discussion

Though thyroid gland is a superficial organ easily identifiable in the neck, at times it will be difficult to differentiate a malignant gland from a benign thyroid gland. There is a possibility of malignancy associated with benign disorders.² Multinodular goitre, nodules in hypothyroid patient, cystic thyroid nodule may all possess a focus of papillary carcinoma and by cytology alone, it may not be possible to differentiate these nodules into benign and malignant. It becomes difficult for the surgeon to make a correct decision on treatment modality, thus making the role of surgery important in doubtful thyroid swellings. On the other hand, if patients not diagnosable by FNAC are treated medically, it is possible the tumour in them may progress leading to delay in the management of thyroid cancer. Current indications of total thyroidectomy are toxic and non-toxic multinodular goiter, Hashimoto's thyroiditis, Graves's disease and malignancies either with a less aggressive clinical course (e.g., papillary thyroid carcinoma) or a rapidly progressive course (e.g. anaplastic thyroid cancer).

FNAC was done for 247 patients by Harshwardhan et al.² Cytopathological analysis showed 132 cases of papillary thyroid cancer, 7 cases of Medullary thyroid carcinoma and 2 cases of Anaplastic thyroid carcinoma. Out of 106 FNAC proven benign cases, 90 cases had undergone total thyroidectomy, 51 cases were found malignant in final HPR. The incidence of malignancy was 48 % in overall benign thyroid lesions in which association of malignancy was highest for follicular neoplasm (71%) followed by adenomatous hyperplasia (57%).

In another study with FNAC proved 1054 (64.3%) benign cases, 128 (7.8%) malignant, 306 (18.66%) suspicious and 151 (9.2%) inadequate for diagnosis, of

the 192 cases, which underwent surgery, FNAC reports were compared with histopathologic results and statistical indices were calculated. The sensitivity, specificity, and accuracy were 91.6%, 100% and 97% respectively.³

Muthu and Saravanakumar (2019) examined 54 specimens of solitary thyroid nodules histopathologically. The incidence of malignancy in the present series is 18.51%.

In the series of Faisal et al., 211 patients underwent thyroidectomy. The female (n=179) to male (n=32) ratio was 5.6 : 1, and the age ranged from 18 to 75 years. The peak age incidence was in the fifth decade of life (60 patients). The incidental carcinoma was found in 22 (10.4%) patients. The frequency of papillary carcinoma was 8.5% of all thyroid diseases and 81.8% of the incidental thyroid malignancies (18/22). Moreover, the frequency of follicular carcinoma was 1.4% of all thyroid swellings (three cases) and 13.6% of incidental thyroid malignancies.⁵

Out of 72 patients in this series, 8(11.1%) patients were having incidental thyroid malignancy. Among 8 patients 6 patients were papillary malignancy (8.33% of all thyroid swellings and 75% of all incidental thyroid malignancies), 1 patient was diagnosed with medullary carcinoma (1.38% of all thyroid swellings and 12.5% of all incidental thyroid malignancies), 1 patient was diagnosed with follicular carcinoma (1.38% of all thyroid swellings and 12.5% of all incidental thyroid malignancies).

Conclusion

FNAC is an effective tool in diagnosing the thyroid diseases with specificity 68% and sensitivity of 91% in diagnosing colloid goitre and specificity of 75% and sensitivity of 62% in diagnosing nodular goitre, however incidental thyroid malignancy should also be considered and correlated with the clinical diagnosis.

References

1. V.Kopperundevi. Histopathological review of thyroid swellings a retrospective study. Volume 2; Issue 5. International Journal of Medical and Health Research 2016; 2(5):10-3
2. Harshwardhan D, Pokharkar, Neharika. Thyroid cancer

- in benign thyroid diseases: Incidence and role of total thyroidectomy. *International Journal of Applied Research* 2018; 4(7):1-5
3. Nygef A, Hassan AJ, Aljaoha RK. The role of FNAC in diagnosis of papillary carcinoma of thyroid. Volume 6, Issue 1. *IOSR Journal of Dental and Medical Sciences* 2013; 6(1):7-13
 4. S. Muthu, R.Saravanakumar. A prospective study of incidence of malignancy in solitary nodule of thyroid. *International Journal of Contemporary Medical Research* 2019; 6(5):E24-6
 5. Faisal M, Fathy H, Risk A, Atwa MM. V37 I3 P(361-367) Incidental thyroid carcinoma after thyroidectomy for benign thyroid disease in Suez Canal region. *The Egyptian Journal of Surgery* 2018; 37(3):361-7.