

# Endoscopic 3-S Technique Tympanoplasty : Taking the Convention a Step Ahead

Mridul Janweja,<sup>1</sup> Sayan Hazra,<sup>1</sup> Arindam Das,<sup>1</sup> Arya Brata Dubey<sup>1</sup>

## ABSTRACT

### Introduction

Endoscopic Surgery has immense potential for middle ear surgery and is currently favoured by many surgeons. The 3 (vascular) Strips/ 3 Flap Tympanoplasty with operating microscope is popular but Endoscopic 3-Flap Tympanoplasty remains less explored. Hence this study was conducted to compare advantages and disadvantages of Endoscopic and Microscopic 3-Flap Tympanoplasty.

### Materials and Methods

Forty two patients with large/subtotal perforation of tympanic membrane were divided into two equal groups (Group A & B). Endoscope was used in Group A, whereas, operating microscope in Group B. Temporalis fascia was the graft material in all patients. Patients were followed up for six months. Pre and post-operative audiograms, post-operative pain, graft uptake, time taken for surgery and intra-operative visualization convenience were compared.

### Results

Mean Air-Bone Gap closure at the end of six months was 9.23 dB (SD-0.88 dB) in the endoscope group and 8.95 dB (SD-0.66 dB) in microscope group whereas the graft uptake rate was 95.2% and 90.2% respectively. Post-operative pain, cosmesis, ease of doing surgery and time taken for surgery were better in 'Endoscope' as compared to 'Microscope' group.

### Conclusion

The three flaps produce adequate exposure in very large or subtotal perforations, very thin anterior rim or with anterior bony overhang. Results in terms of mean hearing gain and graft uptake were comparable. In terms of morbidity (post-op pain), recovery (return to routine activity), mean duration of surgery and cosmesis, endoscopic surgery produced better outcome.

### Keywords

Endoscopic, Microscope, Type 1 tympanoplasty, temporalis fascia

Tympanoplasty is one of the most common surgeries performed. Over many years, otologists have been trying to achieve the perfect surgical outcome. Conventionally, tympanoplasty has been done using an operating microscope. The basic optics and principles employed in the operating microscopes as well as their limitations have remained unchanged despite the continuous technical advancements.<sup>1,2</sup> The linear view offered by the microscope is disadvantageous for the visualization of deeper recesses of the middle ear such as facial recess, sinus tympani, hypotympanum, attic, anterior recess, deep anterior canal wall and anterior margin.<sup>3</sup> This is overcome by the use of various endoscopes-both angled and zero degree, which provide a wider field of view, magnification and the ability to visualize all quadrants and parts of middle ear simply by

moving and rotating the endoscope.

Endoscopic surgery has already been in vogue for the management of sino-nasal pathologies since many decades. The use of endoscopes in middle ear was first set forth by Mer et al in 1967, but their use was restricted for diagnostic and photographic purposes for the next 20-25 years. The concept was further advocated by Tarabichi, Presutti, Nogueira, Marchioni and others in the 1990s. The recent years have witnessed surgeons experimenting with the endoscope in ear surgeries. Middle ear surgeries

*1 - Department of ENT, Institute of Post-Graduate Medical Education & Research (IPGME&R), Kolkata*

### Corresponding author:

Dr Sayan Hazra

email: sayanhazra@yahoo.co.in

such as tympanoplasty, ossiculoplasty, myringotomy, grommet insertion etc. which were traditionally done using the microscope are now being done using the endoscope.

The 3-Strip Technique of tympanoplasty with operating microscope was first introduced by Dr. BK Roychaudhuri in 2004 for repair of large to subtotal perforations of tympanic membrane, and those with anterior bony overhang. A modified end-aural incision is used utilizing only the vertical limb of Lempert's incision. Three skin flaps were elevated in the bony external auditory canal from within outwards by taking three radial incisions on the tympanic membrane remnant at 11'o, 1'o and 6'o clock positions. This creates an anterior flap, a superior, and a posterior flap. The graft is placed lateral to handle of malleus and secured under the three flaps. No gel foam is given in the middle ear. This technique has shown good results with a graft uptake rate of 94.4% as well as good hearing outcome.<sup>4</sup> This study was conducted with an aim to determine the advantages and disadvantages of endoscope as compared to microscope in 3-Flap Tympanoplasty in terms of intra-operative ease of visualization and time taken for surgery and to compare the results of both groups in terms of hearing gain, graft uptake, cosmesis, post-op pain and morbidity, return to routine activity, intra-operative ease of visualization and time taken for surgery.

### Materials and methods

Patients presenting at the OPD during the period January 2018 to May 2018 (5 months) were taken for this study. Meticulous history was taken and otoscopic, oto-endoscopic and microscopic examination was done. Notably, many patients gave history of pond bathing and/or recurrent episodes of URTI in childhood. The size, site and nature of perforation was assessed. Twenty one (21) cases were taken for this study under each group by randomly assigning them either group (A & B) using a Random Numbers Table. Group A underwent endoscopic 3-Flap tympanoplasty by endomeatal technique and Group B underwent microscopic 3-Flap tympanoplasty by end-aural technique. Local anaesthesia was used to perform the surgeries and all the

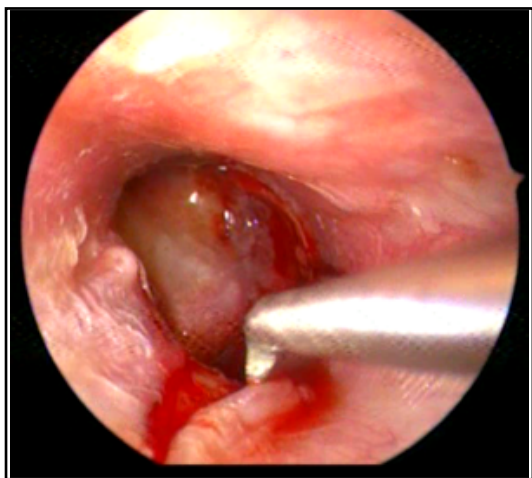
cases were done by a single surgeon. Temporalis fascia graft was used in all cases by a separate incision behind the hairline.

Patients with chronic otitis media (COM) inactive mucosal type with large or subtotal perforation, no history of ear discharge for last 4 weeks, aged between 18 and 60 years and pure conductive hearing loss were included in our study.

Patients with sensorineural or mixed hearing loss, ossicular discontinuity as appeared in otoscopic examinations or tympanometry or found intra-operatively, cholesteatoma and marginal perforations, actively discharging ear, active infection of nose, PNS, throat, URTI, history of previous ear surgery and otitis externa, otomycosis, uncontrolled diabetes mellitus were excluded.

Pure Tone Audiometry was performed in an acoustically treated room without ambient noise and following standard protocol. Patients were explained about the procedure before audiometry and adequate time was taken for testing. The technique followed was Carhart and Jerger's technique which is mostly used (technique of 5 up and 10 down method). An average of A-B Gap at 500, 1000 & 2000 Hz was taken to calculate the hearing loss.

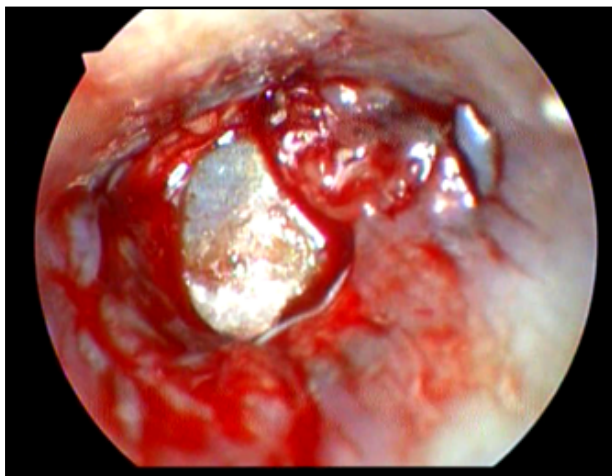
*Surgical Procedure:* All patients underwent surgery under local anaesthesia (2% lignocaine with 1:100000 adrenaline). Pre-medication was done using Pentazocine 30 mg injected im, Diazepam 10 mg injected im and 10 mg charged in iv fluid. In microscopic surgery cases, tragal and pre-auricular region and external auditory canal were infiltrated with 2% lignocaine with 1 in 1,00,000 adrenaline. For endoscopic surgery cases, only the external auditory canal four quadrant block was done. Separate infiltration was done at the graft donor site. For both the techniques, a small 1" skin incision was given underneath the hairline and temporalis fascia graft was harvested. The graft was then allowed to dry. For the microscopic approach, a modified Lempert's Endaural incision utilizing only the vertical limb was placed. Although there was no significant bleeding, even the scanty bleeding was controlled adequately by compression and cauterization. This incision gave a good exposure.



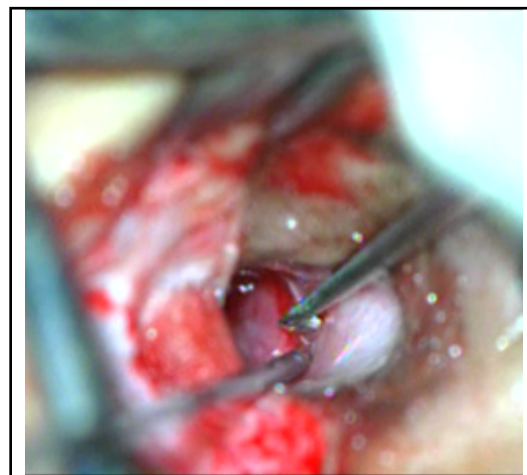
**Fig.1. Endoscopic Flap raising**

A 0° 4 mm Hopkin's Rod rigid endoscope was used for most of the duration of the surgery in endoscopic approach. A 30° 4 mm rigid endoscope was used for inspection of the middle ear cavity. The margins of the perforation were freshened by a sickle knife or angled pick. Three incisions were given on the tympanic membrane remnant at 11'o, 1'o and 6'o clock positions from within outwards and three strips viz. Anterior, Posterior and Superior were raised medial to lateral. (Figs. 1 & 2)

After inspecting the middle ear, attic, meso and hypotympanum, the dried graft was placed lateral to the handle of malleus and over the bony annulus.



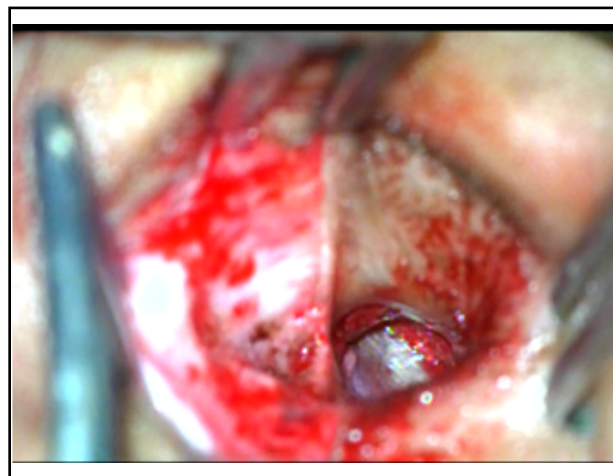
**Fig. 3. Graft after Endoscopic Surgery**



**Fig.2. Microscopic flap raising**

(Figs. 3 & 4) The strips with attached annulus were repositioned- superior first, then the anterior and posterior flaps. Incision lines were then apposed and no gap between graft and flaps was ensured. No gel-foam was given in the middle-ear. Air entry in the middle ear via the Eustachian tube ensured adequate inflation and prevention of graft medialization.

Patients of Group A were discharged the same day and those of Group B were discharged on second post-operative day. Antibiotics, analgesics, oral decongestants and nasal decongestants were given for seven days. Sutures were removed after one week. Patients were followed up for three months. Post-operatively, they



**Fig. 4. Graft after Microscopic surgery**

**Table I: Age demography**

AGE (IN YEARS)	GROUP A (ETP)	GROUP B (MTP)
18-25	2	4
26-35	8	9
35-45	8	6
>45	3	2

*There were 9 males (43%) and 12 (53%) females in Group A. In Group B, 11 (52%) were males and 10 (48%) were females.*

were called for follow up at 1 week, 2 weeks, 4 weeks, 6 weeks, 8 weeks and 12 weeks. The dressing and skin sutures were removed on 7th post-operative day. The wounds were found to be healing and healthy. The neotympanum could not be assessed at the first visit since the gel foam had not dissolved completely, but it could be assessed 4 weeks post-operatively. Post-op audiometry was done at the end of three months.

## Results

In both the groups, majority of the patients belonged to 26-45 years age group; 76.2% (16) in Group A and

71.4% (15) in Group B. (Table I)

In Group A, mean pre-op Air Conduction Threshold was 22.42 dB (SD±4.99 dB) with 38% (8) cases lying in the range 11-20 dB and 62% (13) of the cases lying in the range 21-30 dB. Post-operatively, mean Air Conduction Threshold was 13.19 dB (SD±4.72 dB), with 38% (8) of cases lying in the range 0-10 dB, 57% (12) cases in the range 11-20 dB and 4.7% (1) in the range 21-30 dB. So, the mean hearing gain in the endoscopic group was 9.23 dB (SD±0.88 dB). (Table II)

In Group B, mean pre-op Air Conduction Threshold was 23.42 dB (SD±5.19dB), with 38% (8) of the patients lying in the range 11-20 dB and 57% (12) of the

**Table II: Hearing gain in Group A**

HEARING (AC THRESHOLD-DB)	PRE-OP	POST-OP
0-10 dB	0	8
11-20 dB	8	12
21-30 dB	13	1
31-40 dB	0	0
MEAN (SD)	22.42 (4.99)	13.19 (4.72)
MEAN AB GAP CLOSURE (SD)	9.23 (0.88)	

Table III: Hearing gain in Group B

HEARING (AC THRESHOLD-DB)	PRE-OP	POST-OP
0-10 dB	0	6
11-20 dB	8	12
21-30 dB	12	3
31-40 dB	1	0
MEAN (SD)	23.42 (5.19)	14.47 (5.01)
MEAN AB GAP CLOSURE (SD)	8.95 (0.66)	

The p-value thereby obtained is 0.2503, which is not significant

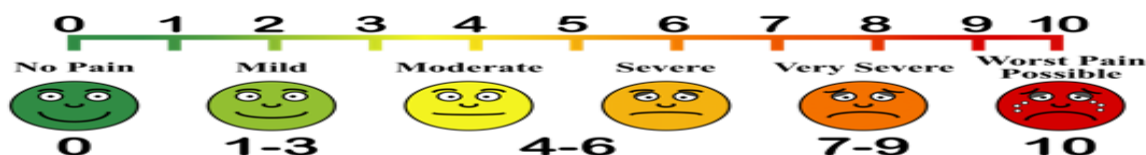patients lying in the range of 21-30 dB. Mean post-op Air Conduction Threshold was 14.47 dB (SD±5.01dB), with 28.6% (6) patients in the range 0-10 dB 57% (12) patients in the range of 11-20 dB and 14.2% (3) in 21-30 dB range. So, the mean hearing gain was 8.95 dB (SD-0.66 dB) in the microscopic group. (Table III)

In Group A, the graft was taken up in 95.2% (20) of the cases with 4.8% (1) cases having a residual CP at the end of six months. Whereas in Group B, the graft was taken up in 90.4% (19) of cases and 9.6% (2) had a residual CP at the end of six months.

In Group A, 90.4% (19) patients reported their

Table IV: Post-operative pain

VAS SCORE	GROUP A (ETP)	GROUP B (MTP)
0	0	0
1-3	18	7
4-6	3	13
7-9	0	1
10	0	0





cosmetic outcome as excellent, 9.6% (2) as satisfactory and no patient reported his/her cosmetic outcome as poor. the microscopic group, 71.4% (15) patients reported their cosmetic outcome as excellent, 23.8% (5) as satisfactory and 4.7% (1) as poor. Whereas in Group B, 71.4% (15) patients reported their cosmetic outcome as excellent, 23.8% (5) as satisfactory and 4.7% (1) as poor.

The average time taken for endoscopic tympanoplasty was 60 minutes with a range of 50-80 minutes. The time range for microscopic tympanoplasty was 60-110 minutes with an average of 78 minutes.

The patients were given a Visual Analogue Pain Scale and asked to rate their pain. A total of 85.7% of the patients of Group A rated their pain between 1-3, which is classified as mild pain. On the other hand, 33.3% patients of Group B rated their pain as mild pain and 66.7% patients rated the pain as moderate to moderately-severe (Table IV).

Patients of Group A returned to routine activity in 2.3 days and those of Group B took 6.1 days for the same on an average.

## Discussion

The objective of this study was to compare Type-I Endoscopic 3-Strip technique tympanoplasty with the conventional End-aural 3-Strip technique tympanoplasty.

The three vascular strips utilized for the procedure (superior, anterior and posterior) produce adequate exposure in all the cases such as very large or subtotal perforations, very thin anterior rim or with anterior bony overhang. The anterior flap can be elevated even in cases with bony overhangs. The annulus cut at the 6 o'clock position does not create any problem subsequently. This also overcomes the problem of lower flap being too bulky if two flap technique is employed.<sup>4</sup>

Almost similar outcomes were found as regards Hearing Gain (p value-0.2) and Graft Uptake which correlate with the study done by El-Guindy<sup>5</sup> and Raj & Meher<sup>6</sup> who also didn't find a significant difference between the Endoscopic and Microscopic group as regards hearing gain. But the endoscopic approach was

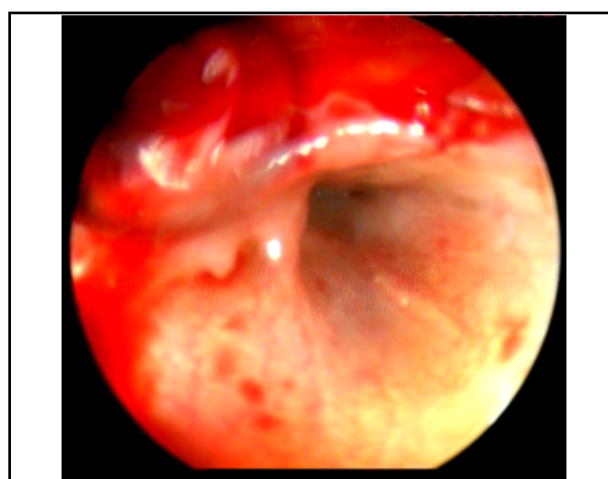
found better as regards cosmesis, time taken for surgery, post-op pain and return to routine activity.<sup>7</sup> Patil's study results also match with that of ours.<sup>8</sup>

The endoscopic technique carries multiple advantages like ease of visualization of the whole tympanic membrane and ear canal without the need to manipulate the patient's head or the microscope.<sup>6,9</sup> Also, the structures usually hidden under the microscope (round window niche, eustachian tube orifice, incudo-stapedial joint, anterior tympanic perforation, facial recess, and hypotympanum) can be seen easily with the help of an endoscope.<sup>3,10</sup> Various structures can be visualized from multiple angles as opposed to the microscope's single axis view along the ear canal.

The chorda tympani nerve can be directly visualized and accidental injury to it can be avoided while raising the posterior meatal flap. The Eustachian tube opening can also be closely visualized with an angled endoscope. (Fig.5) Also, the patency can be confirmed as a patent tube leads to repeated fogging of the Endoscope.

In cases of canal wall bulges, appropriate graft placement can be ensured by advancing the scope beyond the bulge.<sup>10</sup> There is no requirement of canalplasty.<sup>7</sup> Also, the image obtained via an endoscope is much sharper with higher resolution.<sup>6</sup>

The time taken for surgery as well as the average duration of hospitalization is reduced if the surgery is performed endoscopically.<sup>7</sup> Since there is no Endaural incision in the endoscopic approach, there is less



**Fig. 5. Visualizing the eustachian tube opening**

dissection of normal tissues,<sup>10</sup> which, in turn, results in less incidence of post-operative pain<sup>7</sup> and better cosmetic results.

The endoscopic equipment is portable. So, the surgeon can carry it to far off places easily. This is especially beneficial in our Indian setup to perform tympanoplasties in rural areas. It is much more cost effective to perform tympanoplasties through the help of endoscopes and can be widely used in various health camps.<sup>10</sup>

The endoscopic technique is also not without disadvantages such as one handed surgical technique<sup>3,6</sup> loss of depth perception<sup>3,6</sup> steep learning curve, arm fatigue due to increased weight of camera, cumbersome to control bleeding.<sup>10</sup> Endoscope holder, 3-D camera, regular practice of endoscopic otological procedures, adequate vasoconstriction during local anaesthetic infiltration and use of suction micro-instruments can overcome most of these problems.

### Conclusion

The endoscope gives panoramic, wide angle, and magnified view and also provides ease of negotiation through the EAC. In this way, it has overcome most of the disadvantages of microscope. In our study success rate was comparable between endoscopic and microscopic technique. In terms of morbidity, postoperative recovery and cosmesis, endoscope produced better results. Use of endoscope not only serves as a great teaching tool, but also helps to visualize the middle ear anatomy and

pathology intraoperatively with minimal soft tissue manipulation. Thus endoscope holds the greatest promise in ear surgery in coming days.

### References

1. Harugop AS, Mudhol RS, Godhi RA. A comparative study of endoscope assisted myringoplasty and microscope assisted myringoplasty. *Indian J Otolaryngol Head Neck Surg.* 2008; 60:298-302
2. Glasscock ME, Shambaugh GE. Tympanoplasty. In: Glasscock and Shambaugh, Eds. *Surgery of the Ear*, 5th ed. People's Medical Publishing House, Connecticut, p 350-70
3. Tarabichi M. Endoscopic middle ear surgery. *Ann Otol Rhinol Laryngol.* 1999; 108: p 39-46
4. Roychaudhuri BK. 3-Flap Tympanoplasty- A simple and sure success technique. *Indian J Otolaryngol Head Neck Surg.* 2004; 56(3):196-200
5. El-Guindy A. Endoscopic transcanal myringoplasty. *J Laryngol Otol.* 1992; 106:493-5
6. Raj A, Meher R. Endoscopic transcanal myringoplasty-a study. *Indian J Otolaryngol Head Neck Surg.* 2001; 53(1):47-9
7. Jyothi AC, Shrikrishna BH, Kulkarni NH, Kumar A. Endoscopic Myringoplasty Versus Microscopic Myringoplasty in Tubotympanic CSOM: A Comparative Study of 120 Cases. *Indian J Otolaryngol Head Neck Surg.* 2017; 69(3):357-62
8. Patil RN. Endoscopic tympanoplasty—definitely advantageous (preliminary reports). *Asian J Ear Nose Throat* 2003; 25:9-13
9. Mer SB, Derbyshire AJ, Brushenko A, Pontarelli DA. (1967) Fiberoptic endoscopes for examining the middle ear. *Arch Otolaryngol.* 1967; 85:387-93
10. Patel J, Aiyer RG, Gajjar Y, Gupta R, Raval J, Suthar PP. (2015) Endoscopic tympanoplasty vs microscopic tympanoplasty in tubotympanic CSOM: a comparative study of 44 cases. *Int J Res Med Sci.* 2015; 3(8):1953-7.