

Allergic Fungal Sinusitis with Bilateral Optic Neuropathy

<https://doi.org/10.47210/bjohns.2021.v29i3.537>

Priyanshi Gupta,¹ Digvijay Singh Rawat,² Yogesh Aseri,² PC Verma,² BK Singh²

ABSTRACT

Introduction

Allergic Fungal Rhinosinusitis (AFRS) is characterized by an inflammatory response to a non-invasive fungus which leads to sinus obstruction. Ophthalmic manifestations of AFRS are rare but can be of grave consequence.

Case Report

A 22-year-old female patient presented with a 5-day history of headache and decreased vision in both eyes (right- perception of light; left-6/18), along with a past history of nasal blockage and recurrent rhinorrhoea. She had thick viscid mucous secretion with polyposis in bilateral nasal cavities. Computed tomography showed pansinusitis with heterogenous opacification and polypoidal mucosal hypertrophy. Bony erosion was seen in bilateral orbital apices with oedematous optic nerves. MRI was suggestive of bilateral optic neuritis. Patient underwent emergency surgical debridement via endoscopic sinus surgery. Histopathological examination of the specimen showed cellular debris, eosinophilic prominence and numerous Charcot-Leyden crystals, with presence of branched septate fungal hyphae. Fungal culture grew *Aspergillus flavus*. Patient was treated with steroids (injectable followed by oral in gradually tapering doses). Over a period of 3 months vision returned to normal.

Conclusion

Vision loss is a rare complication of AFRS and constitutes an emergency. Prompt treatment with surgical debridement and corticosteroids is essential for reversal of visual complications.

Keywords

Allergic Fungal Rhinosinusitis; Optic Neuropathy

Allergic fungal sinusitis (AFS) is a non-invasive inflammatory process that occurs in immunocompetent patients as a chronic allergic response to an offending mold, typically dematiaceous fungi. Pathologic findings of AFS include fungal elements without invasion of sinus mucosa and a collection of “allergic mucin,” made of cellular debris, broken-down eosinophils and Charcot-Leyden crystals. Ophthalmic manifestations of AFS include proptosis, diplopia, blepharoptosis, epiphora, visual loss, ophthalmoplegia and orbital abscess formation. Visual loss due to AFS is a rare and dreaded clinical entity that requires urgent intervention. Here we present a case of a patient with clinical and neuroimaging evidence of an optic neuropathy secondary to pathologically proven AFS.

Case Report

A 22-year-old female patient presented to us with a 5-day history of headache and decreased vision in her right eye. There were preceding complaints of nasal blockage in the last 2 months (on and off) and rhinorrhea. The patient denied epistaxis, fever, chills, pain with eye movements or restriction of gaze in any direction, double vision, photophobia or a history of asthma. Past medical history was positive for seasonal allergies.

On rhinological examination, the patient was noted

1 - Department of ENT, Mahatma Gandhi Medical College and Hospital, Jaipur

2 - Department of ENT, JLN Medical College and Hospital, Ajmer

Corresponding author:

Dr Priyanshi Gupta

email: priyanshi728@gmail.com

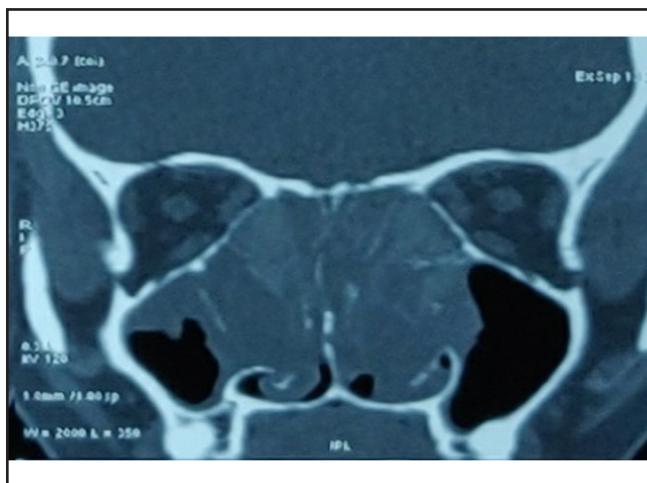


Fig. 1.a. Non-contrast CT PNS coronal section showing heterogeneous opacification in bilateral ethmoid sinuses.

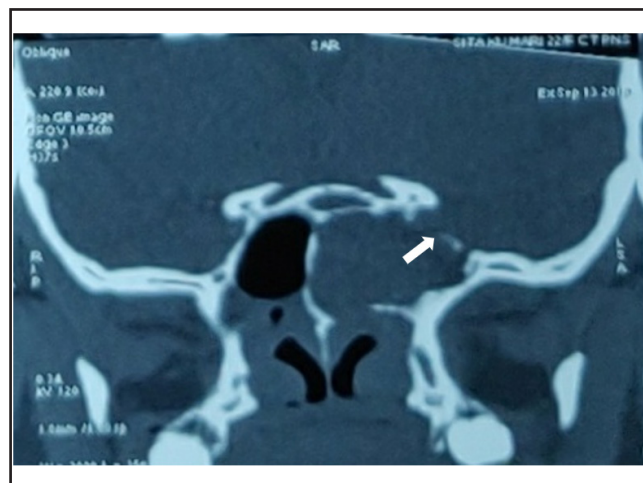


Fig. 1.b. Non contrast CT PNS Coronal section showing left sphenoid sinus heterogeneous opacification with lateral wall dehiscence (white arrow)

to have thick viscid mucous secretion collected in the floor along with polyps arising from ethmoid sinuses with osteo-meatal complex blockage seen bilaterally, with a mild septal deviation to the right side. Rest of the ENT examination was within normal limits. CT and MRI were advised.

On ocular examination, the patient was noted to have perception of light vision in her right eye and 6/18 vision in her left eye. Hertel's exophthalmometry showed no proptosis. Confrontation testing revealed a large central defect in the right visual field. The anterior segment examination and dilated fundus examination showed no evidence of papilledema in either eye and were otherwise within normal limits. By the next day vision in the left eye had deteriorated to perception of light. There was no limitation and pain on movement of eyeball in either direction.

Non-contrast computed tomography (CT) Scan of paranasal sinuses and brain (Fig-1A & 1B) showed pansinusitis with heterogeneous opacification and polypoidal mucosal hypertrophy. Ostia of bilateral maxillary sinuses were blocked by hypertrophied mucosa. Bony erosion was seen involving orbital apex bilaterally and adjacent lateral walls of sphenoid sinus. Mild nasal septum deviation was seen towards right side.

Magnetic Resonance Imaging (MRI) Brain with

orbits (Fig-2) showed subtle hyperintensity in both optic nerves in T1 images suggestive of bilateral optic neuritis. Paranasal sinuses showed similar changes as mentioned in CT above.

Patient underwent emergency surgical debridement via endoscopic sinus surgery under general anesthesia. All the polyps and thick mucinous secretions were removed and sent for histopathological and microbiological evaluation. (Fig-3) All the sinuses of both sides were

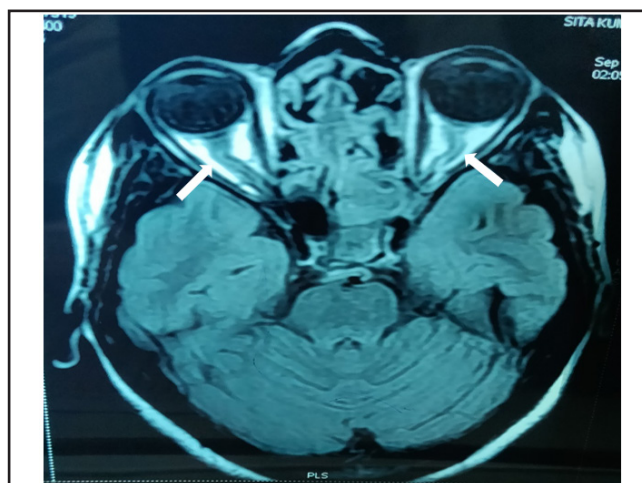


Fig. 2. MRI Brain T1W sequence transverse section showing hyperintensity in both optic nerves (white arrows). Bilateral sinopolyposis and pansinusitis is also seen.

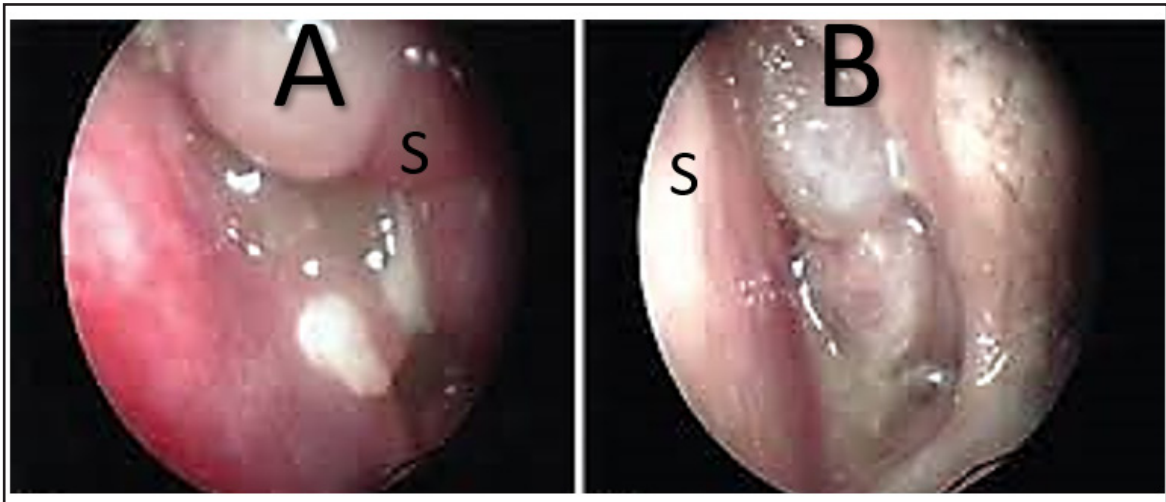


Fig. 3. showing pre-operative nasal endoscopy image. A- Right nasal cavity, B- Left nasal cavity. Abbreviation; S- Nasal Septum.

opened and cleared of disease. However, no gross bony erosion or dehiscence was found intraoperatively. Nasal packing was done with standard nasal pack. Peri-operative period was uneventful. Nasal packing was removed after 48hrs and saline nasal irrigation started thrice daily.

Histopathological examination of the specimen showed cellular debris, eosinophilic prominence and numerous Charcot-Leyden crystals. On Gomori methenamine silver (GMS) staining presence of branched septate fungal hyphae were seen which on

culture grew *Aspergillus flavus*.

Post-operatively patient was treated with injection ceftriaxone, amikacin and injection methylprednisolone 1gm/day intravenously for 3 days following which she was shifted to oral prednisolone in a gradually tapering dose of 40mg OD for 5 days then 20mg OD for 5 days and then 10mg OD for 5 days. Nasal endoscopy and suction clearance were done every alternate day.

Vision testing was done on 2nd post-operative day which showed vision improvement on Right side to 6/36 and on Left side to 6/18. Subsequently on 7th

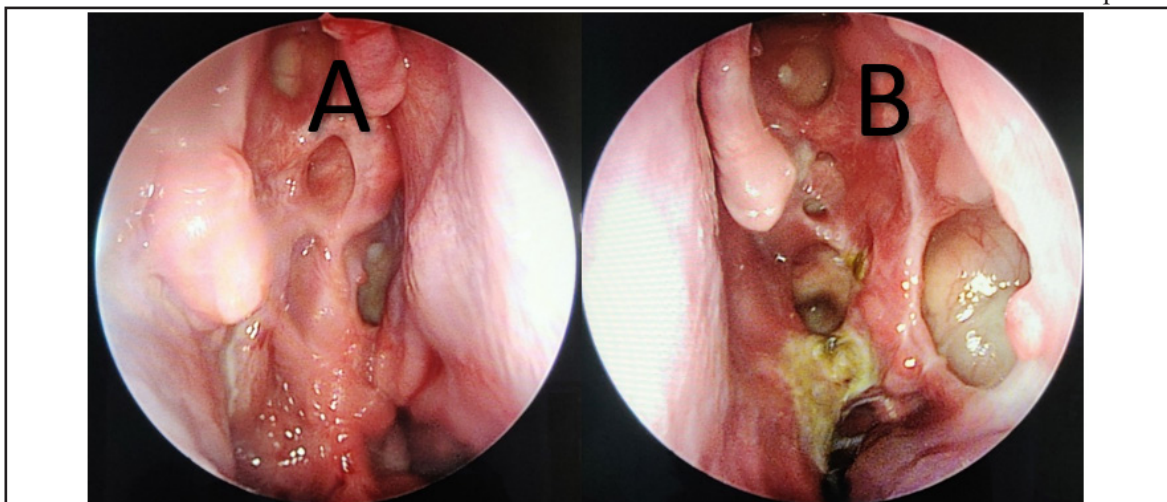


Fig. 4. Post-operative nasal endoscopy image. A- Right nasal cavity, B- left nasal cavity.

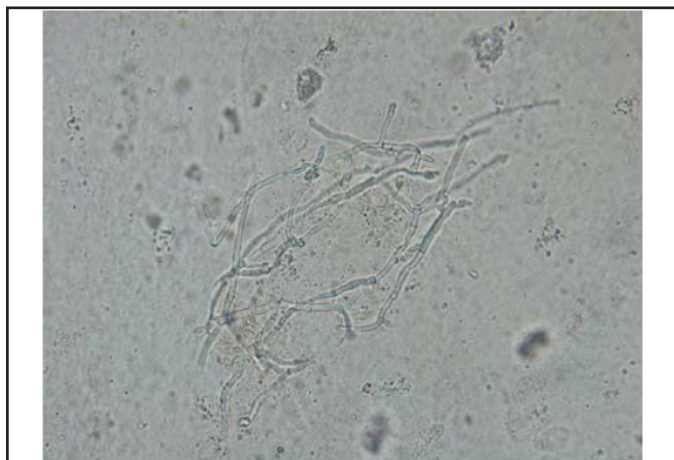

Fig. 5. KOH mount preparation showing thin hyaline branched septate hyphae of *Aspergillus flavus*.

post-operative day vision was 6/9 in both eyes along with Automated perimetry which showed resolution of visual field defects. Patient was then discharged on oral steroids, antibiotics, topical nasal saline irrigation.

Patient was then followed up weekly for 3 months at the end of which patient was asymptomatic with 6/6 vision in both eyes along with healthy nasal cavity with bilaterally open sinus ostia. (Fig-4)

Discussion

Fungal sinusitis can be of either invasive or non-invasive type. Included among invasive sinusitis are the acute necrotizing, chronic invasive and granulomatous invasive subtypes. Non-invasive sinusitis can be either a fungal ball or allergic fungal sinusitis.¹ Allergic fungal sinusitis (AFS) is a rare disorder characterized by chronic, intractable noninvasive sinusitis with polyposis and eosinophil-rich “allergic mucin”, occurring in an immunocompetent host. The intact immune system usually prevents serious fungal infections effectively. The human disease of fungal etiology tends to be opportunistic, the interaction between fungi and host immunity. Fungus of the same species can be invasive or non-invasive in different individuals. The diagnosis is made by the Bent and Kuhn criteria² Our patient satisfied all the 5 major criteria and 3 minor criteria. The characteristic findings on computed tomography are the presence of heterogenous signal density in the nasal

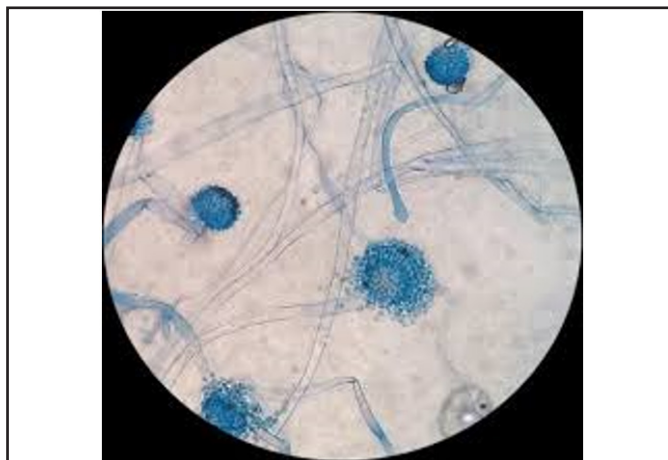

Fig. 6. Lactophenol cotton blue (LPCB) mount preparation of *Aspergillus flavus*.

cavity and paranasal sinuses (due to the allergic mucin) along with nasal and sinusoidal polyposis. AFRS has a chronicity of progression, usually of more than 12 weeks duration. The findings are usually unilateral and asymmetric and may be associated with bony thinning and erosion due to expansile mucin.³ Common fungi implicated in AFS are *Aspergillus*, *Bipolaris*, *Alternaria*, *Penicillium*.⁴ In our case we observed *Aspergillus flavus* as the causative organism (Fig 5 & 6).

The complications of AFS are ophthalmic, Sino-bronchial allergic mycosis syndrome, cavernous sinus thrombosis and complications due to bony erosions.⁵ Ophthalmic complications occur in 1.46% cases of AFS⁶ and include proptosis, diplopia and rarely, vision loss. We observed bilateral vision loss in our patient which is unusual as most cases previously described had ipsilateral vision loss only. Papilledema was not observed in our patient which is a deviation from the previous reports.^{3,6,7} Vision loss in AFS is postulated to be due to a combination of mechanical compression of the optic nerve and an allergic immune response to fungal antigens.⁶ In our case there was no evidence of bony invasion so the likely reason behind vision loss was orbital inflammation causing optic neuritis.

Pre-operative medical treatments are frequently used in the form of systemic corticosteroids for short duration. The mainstay of treatment of AFS is surgical debridement and corticosteroids. Use of antifungal drugs either oral or topical is not indicated.³ Our

patient underwent surgical debridement and received methylprednisolone followed by oral prednisolone in tapering dose. She reported significant improvement in vision after 7 days of treatment. Prognosis of AFS, including that of ophthalmic complications is usually excellent.⁵

To conclude, ophthalmic complications are rare features of AFS. Vision loss due to AFS constitutes an emergency. Prompt treatment with surgical debridement and corticosteroids lead to good visual outcome in most cases.

References

1. de Shazo RD, Chapin K, Swain RE. Fungal Sinusitis. *New England Journal of Medicine* 1997; 337(4):254-9
2. Bent JP, Kuhn FA. Diagnosis of Allergic Fungal Sinusitis. *Otolaryngol Head Neck Surg.* 1994; 111(5):580-8
3. Glass D, Amedee RG. Allergic fungal rhinosinusitis: a review. *Ochsner J.* 2011; 11(3):271-5
4. Al-Dousary SH. Allergic fungal sinusitis: radiological and microbiological features of 59 cases. *Ann Saudi Med.* 2008;28(1):17-21
5. Bozeman S, de Shazo R, Stringer S, Wright L. Complications of allergic fungal sinusitis. *Am J Med.* 2011;124(4):359-68
6. Gupta AK, Bansal S, Gupta A, Mathur N. Visual loss in the setting of allergic fungal sinusitis: pathophysiology and outcome. *J Laryngol Otol.* 2007; 121(11):1055-9
7. Brown P, Demaerel P, McNaught A, Revesz T, Graham E, Kendall BE, et al. Neuro-ophthalmological presentation of non-invasive *Aspergillus* sinus disease in the non-immunocompromised host. *Journal of Neurology, Neurosurgery & Psychiatry* 1994; 57(2):234-7.