



# Cholesterol Granuloma of Maxillary Sinus – An Unusual Case

<https://doi.org/10.47210/bjohns.2022.v30i2.688>

Satish Kumar,<sup>1</sup> Vinita Agrawal,<sup>1</sup> Kumaran Ramesh Colbert,<sup>1</sup> Kalaivani Manjula,<sup>2</sup> Ravindra V Bhat<sup>2</sup>

## ABSTRACT

### Introduction

Cholesterol granuloma is a type of foreign body granuloma found in tissues wherein the cholesterol crystals get accumulated. Quite unusual to be present in a maxillary sinus owing to its pathogenesis.

### Case Report

A 12-year old-male child diagnosed with antrochoanal polyp, underwent endoscopic sinus surgery and the microscopic analyses revealed maxillary sinus cholesterol granuloma.

### Conclusion

Cholesterol granuloma is an uncommon tissue reaction to cholesterol crystals in the maxillary sinus owing to its well-ventilated state and is frequently associated with chronic sinus disease or trauma. Since its signs and symptoms are non-specific, histopathological analysis is essential for correct diagnosis.

### Keywords

Cholesterol Granuloma; Maxillary Sinus

Cholesterol granuloma is a pathological condition associated with diseases of the middle ear, mastoid, and temporal bone. Unusual sites reported include jaws, kidneys, lymph nodes, and paranasal sinuses.<sup>1,2</sup> Since 1964, only 44 cases have been reported in the literature.<sup>3</sup> We report one such unusual case of cholesterol granuloma involving the maxillary sinus.

## Case Report

A 12-year old-male child presented with right-sided nasal obstruction for 1 month, insidious in onset and progressively increasing in nature. He also had right-sided facial pain, mucoid non-foul smelling nasal discharge,

snoring, and mouth breathing with nasal intonation of speech. There was no history of epistaxis, fever, trauma to the nose or face, loss of weight, or appetite.

On examination, the external appearance of the nose was normal. On anterior rhinoscopy, a pinkish multilobulated smooth grape-like mass was seen completely occluding the right nasal cavity, originating from the right middle meatus. It was insensitive to touch and did not bleed on touch, the probe could be passed all around. Posterior rhinoscopy demonstrated grade II adenoid hypertrophy.

On functional examination, there was no misting on the right side (cold spatula test) and anosmia on the right side. The right maxillary sinus the frontal and ethmoid sinuses were tender on palpation. Eye movements were normal bilaterally. The oral cavity, oropharynx, and ears were normal. No significant lymphadenopathy was noted in the neck.

Diagnostic nasal endoscopy demonstrated a pinkish

1 - Department of ENT, Indira Gandhi Medical College and Research Institute

2 - Department of Pathology, Indira Gandhi Medical College and Research Institute

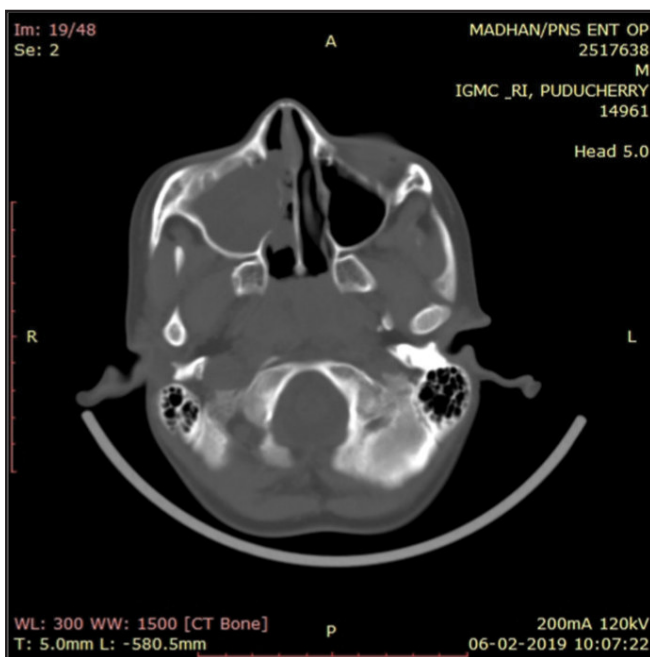
### Corresponding author:

Dr Satish Kumar

email: docsatkumar@gmail.com

multilobulated mass filling the right nasal cavity and extending towards the nasopharynx, originating from the right middle meatus through a slender stalk extending into the right maxillary sinus.

Further, on CT PNS extensive mucosal thickening was seen within the right maxillary sinus, showing patchy hyperdense areas adjacent to the meatus along with bone thinning and extension into the right nasal cavity as polypoidal mass (Fig. 1). The frontal and sphenoid sinus



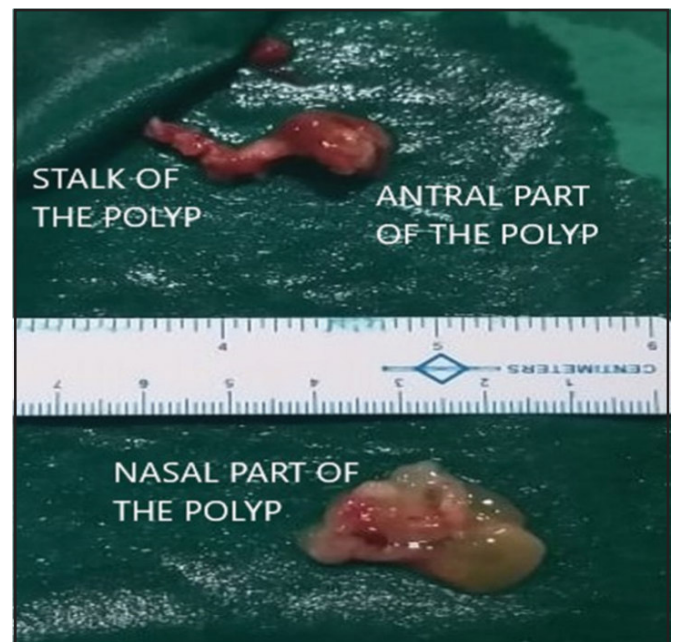
**Fig. 1. CT PNS showing extensive mucosal thickening within the right maxillary sinus with patchy hyperdense areas adjacent to the middle meatus with bone thinning and polyp mass extending into the right nasal cavity**

appeared unremarkable. Based on these findings a provisional clinical diagnosis of a right antrochoanal polyp was made.

The patient underwent wide middle meatal antrostomy with limited anterior ethmoidectomy and the mass was excised in toto. Intraoperatively there was a multilobulated polypoidal mass completely obliterating the right nasal cavity, originating from the right middle meatus, with its

stalk extending into the right maxillary antrum through an accessory ostium. The antral part of the polypoid mass was attached anteroinferior (Fig. 2).

Grossly, the polypoidal mass from the middle meatus appeared pink-grey white, fleshy soft tissue measuring 3x2.5x0.7 cm with the external and cut surface being soft to firm and glistening.

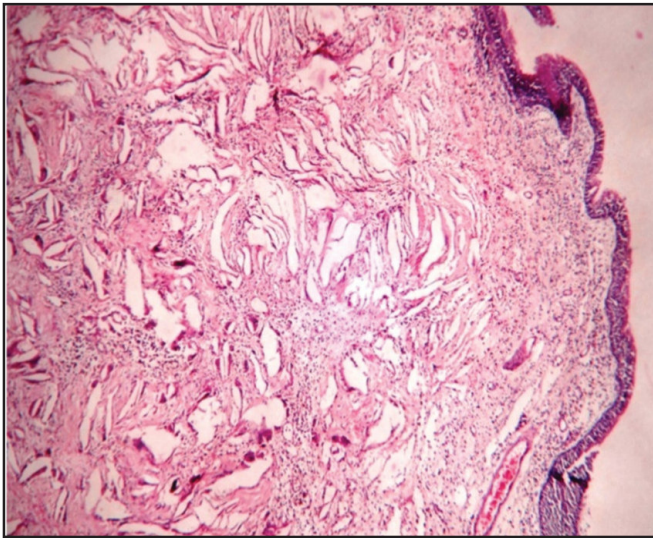


**Fig. 2. The excised mass had a multilobulated nasal part, a thin stalk, and a firm, fleshy and granular antral part**

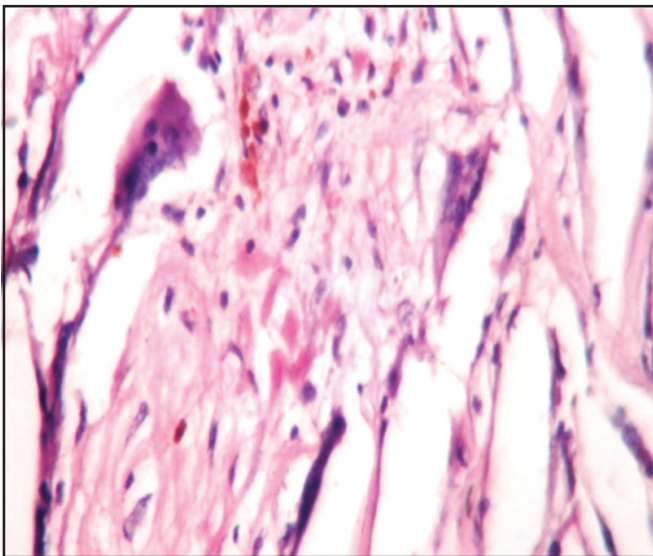
The firm mass from the maxillary sinus appeared stalk-like, with a dark brown soft tissue fragment measuring 2.5 x 1.5 x 1 cm with the cut surface being pinkish grey white.

On histopathological examination, the polypoid mass was lined by pseudostratified ciliated columnar epithelium with edematous subepithelial stroma consisting of mixed inflammatory cells. A large area of stroma was occupied with cholesterol granulomas consisting of cholesterol clefts, foreign body giant cells, lymphocytes, plasma cells, histiocytes, and hemosiderin-laden macrophages (Fig 2,3). Mass from the maxillary sinus also showed a similar picture.

With these findings, a final diagnosis of cholesterol granuloma maxillary sinus was made.



**Fig. 3. Histopathology section from the mass of maxillary sinus showing lining by pseudostratified ciliated columnar epithelium with sub-epithelium showing dense inflammation, edema, and numerous cholesterol clefts appearing as needle-like long structures (H&E stain, 4x magnification)**



**Fig. 4. High power of histopathology section showing empty appearing needle-shaped cholesterol clefts surrounded by foreign body multinucleate giant cells and dense inflammation with edema suggesting cholesterol granuloma (H&E stain, 40x magnification)**

## Discussion

Cholesterol granuloma (CG) is a foreign body reaction to cholesterol crystals with granuloma formation along with the component of granulation tissue formed during the inflammatory process in the tissues.

Histopathologically the lesion comprised a large number of needle-shaped clefts often filled with cholesterol crystal and sometimes empty due to the dissolution of cholesterol during tissue processing. These clefts are surrounded by foreign body giant cells, foam cells, and hemosiderin-laden macrophages in a fibrous background.<sup>4,5</sup>

Cholesterol granulomas are commonly associated with diseases of the middle ear, mastoids, and other air cells of the temporal bone. It has also been reported in the skull base, orbit, jaws, testes, kidney, lymph nodes, breast papilloma, and rarely in paranasal sinuses.<sup>1,2,6</sup>

This uncommon and benign sinus lesion was first described by Graham and Michael in 1978<sup>4</sup>. From the year of 2005 to 2016, 12 cases of cholesterol granuloma in the maxillary sinus have been reported. They are mostly seen in middle-aged men, with a male-to-female ratio of 3:1. Its rare occurrence in paranasal sinuses may be attributed to its pathogenesis.<sup>1</sup>

The pathogenesis of Cholesterol Granuloma in the temporal bone is explained by two popular theories,

1. The obstruction-vacuum theory: wherein the dysfunction of the Eustachian tube is thought to be leading to mucosal edema and repeated episodes of bleeding within the temporal bone, and
2. The exposed marrow theory: is thought to be due to exposure of the highly vascular marrow spaces secondary to mucosal erosion of the underlying bone and the resultant bleeding.<sup>7-10</sup>

The pathogenesis of cholesterol granuloma in the maxillary sinus is very similar. As described by Nager,<sup>11</sup> it is dependent on three factors: hemorrhage, obstruction of drainage, and impairment of ventilation. Increased intrasinus pressure resulting from blockage of drainage and ventilation with, superadded infection results in intrasinus bleeding. The source of cholesterol is the cell membrane of erythrocytes destroyed during bleeding,

which precipitates into crystals due to inadequate drainage. Connective tissue degeneration due to reduction of ventilation and inflammatory process also contributes to cholesterol crystal formation.

Infection, trauma, inflammation, and obstruction to drainage coupled with lack of ventilation lead to stasis of erythrocytes and other tissue elements that break down to deposit cholesterol and other lipids. These irritants stimulate foreign body reactions. This has been supported by the experimental work done by Niho<sup>12</sup> and Main.<sup>13</sup>

There are incidences reported wherein, the occurrence of cholesterol granuloma of the maxillary sinus was associated with endodontically treated maxillary posterior teeth.<sup>14</sup> A meta-analysis by Arias-Irimia et al<sup>15</sup> concludes that 47.68 % of maxillary sinusitis is secondary to odontogenic etiology and that the occurrence of CG in these is a common phenomenon. It could be attributed to the hemorrhage and inflammatory processes in the maxillary sinus following instrumentation or endodontic obturation.

The usual presentation of sinonasal cholesterol granuloma is that of any other sinus disease, that is the history of rhinitis, facial pain, headache, nasal obstruction, and nasal discharge.<sup>5</sup>

Radiologically, CT and MRI have a significant role in the diagnosis and treatment of CG. It appears as a cyst-like well-defined lesion (isodense) within the sinus cavity often associated with an expansion of the bony walls of the sinus which may or may not be accompanied by bone erosion, and no contrast enhancement.<sup>5</sup> On MRI these lesions exhibit high signal intensity in both T1 and T2 weighted images, a feature characteristic of chronic hemorrhage, often interspersed with septations or foci of low intensity.<sup>16</sup>

Differentials may vary from allergic and inflammatory sinusoidal diseases, mucocoeles, pyomucocoele, sinusoidal odontogenic and non-odontogenic cysts, and malignancy. A histopathological analysis is essential for the final diagnosis of maxillary sinus cholesterol granuloma, as its clinical and radiographic characteristics are non-specific, but are important to complement diagnosis and treatment

planning. Each sinonasal disease requires a specific approach toward treatment.

The most appropriate treatment of cholesterol granuloma of the maxillary sinus is surgery. The classical approach is the Caldwell-Luc operation, the other being Endoscopic Sinus Surgery.<sup>17,18</sup> Of late, the endoscopic approach has superseded the classical approach owing to lesser postoperative morbidity and better visualization.

Occurrence of cholesterol granuloma in the paranasal sinuses is rare unless there is a complete blockage of ventilation, and blockage of drainage with superadded infection. All these factors were present in our case which could have resulted in the formation of cholesterol granuloma of the right maxillary sinus.

Overall, the prognosis is good and recurrences are rare with effective treatment.

## Conclusion

CG is an uncommon tissue reaction to cholesterol crystals in the maxillary sinus owing to its well-ventilated state and is frequently associated with chronic sinus disease or trauma. Since its signs and symptoms are non-specific, histopathological analysis is essential for correct diagnosis and cholesterol granuloma should also be considered as a differential in sinonasal diseases.

## References

1. Lee JH, Lee DH. Endoscopic view of cholesterol granuloma of the maxillary sinus. *Ear, Nose & Throat Journal*. 2019 Dec;98(10):634-5
2. Marina MB, Gendeh BS. Bilateral maxillary sinus cholesterol granuloma: a rare entity. *Medical Journal of Malaysia*. 2006 Jun 1;61(2):226
3. Leon ME, Chavez C, Fyfe B, Nagorsky MJ, Garcia FU. Cholesterol granuloma of the maxillary sinus. *Archives of pathology & laboratory medicine*. 2002Feb;126(2):217-9.
4. Graham J, Michaels L. Cholesterol granuloma of the maxillary antrum. *Clinical Otolaryngology and Allied Sciences*. 1978 May 1;3(2):155-60
5. Rath-Wolfson L, Talmi YP, Halpern M, Levit I, Zohar Y, Gal R. Cholesterol granulomas of the maxillary sinus presenting

- with nasal obstruction. *Otolaryngology-Head and Neck Surgery*. 1993 Nov;109(5):956-8
6. Campos A, Armengot M, Zapater E, Hostalet F, Basterra J. Cholesterol granuloma of the middle ear: report of 5 cases. *Acta oto-rhino-laryngologica belgica*. 1996 Jan 1;50(2):125-9
  7. Isaacson B, Nogueira JF. Endoscopic management of middle ear and temporal bone lesions. *Otolaryngologic Clinics of North America*. 2016 Oct 1;49(5):1205-14
  8. Iannella G, Stasolla A, Pasquariello B, Re M, Magliulo G. Tympanomastoid cholesterol granuloma: radiological and intraoperative findings of a blood source connection. *European Archives of Oto-Rhino-Laryngology*. 2016 Sep;273(9):2395-401
  9. Sweeney AD, Osetinsky LM, Hunter JB, Haynes DS, Carlson ML. Cholesterol granuloma development following temporal bone surgery. *Otolaryngology-Head and Neck Surgery*. 2016 Jun;154(6):1115-20
  10. Nager GT. *Pathology of the ear and temporal bone*. Williams & Wilkins; 1993
  11. Jackler RK, Cho M. A new theory to explain the genesis of petrous apex cholesterol granuloma. *Otology & neurotology*. 2003 Jan 1;24(1):96-106
  12. Niho M. Cholesterol crystals in the temporal bone and the paranasal sinuses. *International journal of pediatric otorhinolaryngology*. 1986 Feb 1;11(1):79-95
  13. Main TS, Shimada T, Lim DJ. Experimental cholesterol granuloma. *Archives of Otolaryngology*. 1970 Apr 1;91(4):356-9
  14. Astarci HM, Sungu N, Samim EE, Ustun H. Presence of cholesterol granuloma in the maxillary and ethmoid sinuses. *Oral and Maxillofacial Surgery*. 2008 Jul;12(2):101-3
  15. Irimia ÓA, Dorado CB, Marino JS, Rodríguez NM, González JM. Meta-analysis of the etiology of odontogenic maxillary sinusitis. *Medicina oral, patología oral y cirugía bucal*. Ed. inglesa. 2010;15(1):16
  16. Milton CM, Bickerton RC. A review of maxillary sinus cholesterol granuloma. *British Journal of Oral and Maxillofacial Surgery*. 1986 Aug 1;24(4):293-9
  17. Chao TK. Cholesterol granuloma of the maxillary sinus. *European Archives of Oto-Rhino-Laryngology and Head & Neck*. 2006 Jun;263(6):592-7
  18. Alkan A, Etoz O, Candirli C, Ulu M, Dayisoğlu EH. Cholesterol granuloma of the jaws: report of two cases. *Journal of the Pakistan Medical Association*. 2014 Jan 1;64(1):86-8.