

Large Neurilemmoma of Buccal Mucosa in a Child – A Rare Entity

Sirshak Dutta,¹ Neeraj Aggarwal,¹ Avijit Choudhury,¹ Ramanuj Sinha¹

ABSTRACT

Introduction

Neurilemmoma or Schwannomas are benign tumour arising from the nerve sheath of myelinated nerve. Head neck neurilemmomas are not uncommon but intraoral region is very uncommon for this type of tumour.

Case report

A very rare case of buccal neurilemmoma in an eleven year old child, but much larger than other reported case is reported in the present article with review of literature.

Discussion

Among the intraoral subsites, very few cases of neurilemmoma are reported to be situated in the buccal mucosa. Diagnostic dilemmas due to Fine needle aspiration cytology with features often resembling that of pleomorphic salivary adenomas are reported. The size of the tumour was larger than the cases reported in literature till date. The age of the patient was also much younger than the other reported cases, which made the present case unique.

Keywords

Neurilemmoma; Cheek; Magnetic Resonance Imaging; Histopathology.

Neurilemmomas are benign tumors arising from the Schwann cells of peripheral, cranial and sympathetic nerves. The terms Neurilemmoma and Schwannoma are often used interchangeably.¹ One-fourth of Extracranial neurilemmomas occur in cervicofacial region but intraoral neurilemmomas are extremely rare with only 1% incidence.² Tongue is the most common intraoral subsite,³ but neurilemmoma in buccal mucosa are seldom reported. Due to scarcity of the reported cases, no specific clinical features are described in texts, and the final diagnosis can only be arrived after histopathological examination or sometimes immunohistochemistry. One such extremely rare case in an 11 year old boy is reported in the present article along with literature review.

Case Report

An eleven year old male patient presented in outpatient department with a swelling in left cheek for the last one year. There was no history of trauma or surgery. The swelling was painless, gradually progressing in size, and not associated with any signs of inflammation.

On inspection, a single large swelling of about 6x2 cm was present in the left cheek pushing the angle of mouth inferiorly. The skin over the swelling was normal. Intraoral examination revealed that the swelling was submucosal at the inner aspect of upper lip and extended up to the buccal mucosa opposite to the left second molar tooth.(Fig.1)

The gingivolabial and the gingivobuccal sulcus were not involved. Oro-dental hygiene was well maintained and dental status was appropriate for the age.

On palpation, there was a single, non-tender swelling of 6x2 cm size. It was firm, bosselated, mobile and not fixed to the buccal mucosa or the overlying skin. The cervical lymph nodes were not palpable.

The patient was subjected to fine needle aspiration cytology (FNAC) shows epithelial cells and myoepithelial cells arranged in a background of fibromyxoid stroma giving a likely impression of pleomorphic minor salivary

1 - Department of ENT, Medical College, Kolkata

Corresponding author:

Dr Neeraj Aggarwal
email: drneeraj5887@gmail.com

gland tumour.

Magnetic resonance imaging was then advised to assess the extent and other soft tissue involvement

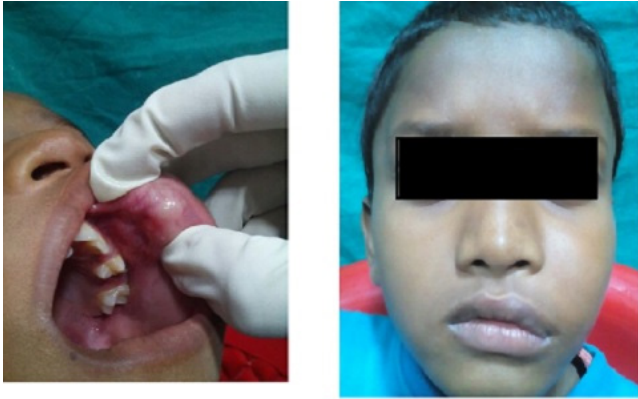

Fig. 1 Clinical photograph of the patient

which showed a lobulated hyperintensed soft tissue lesion involving anterior portion of left cheek without much perilesional oedema.(Fig. 2)

Complete excision of the mass under general anaesthesia was planned. Wide excision of the tumour

along with rim of normal tissue was done via intra-oral route. Macroscopically, it was a rubbery, tan-white, lobulated mass with size of 7x3 cm.(Fig. 3)

Microscopically, there were hypercellular areas (Antoni A) composed of monomorphic spindle shaped schwann cells forming verocay bodies in focal spaces interspersed with hypocellular (Antoni B) areas. Some thick hyaline walled blood vessels were also seen.(Fig. 4)

Based upon the presentation, clinical, radiological and histopathological findings the diagnosis of Neurilemmoma of the buccal mucosa was made. At 15 days post-operative follow-up, surgical wound was healed completely and the swelling was resolved. (Fig. 5) The patient was followed up for 12 months further without any recurrence.

Discussion

The term 'Schwannoma' had been attributed in the past either for neurofibroma or neurilemmoma. But the present concept is that, the first one originates from perineural cells and the latter one from Schwann cells and the term schwannoma can be interchangeably used

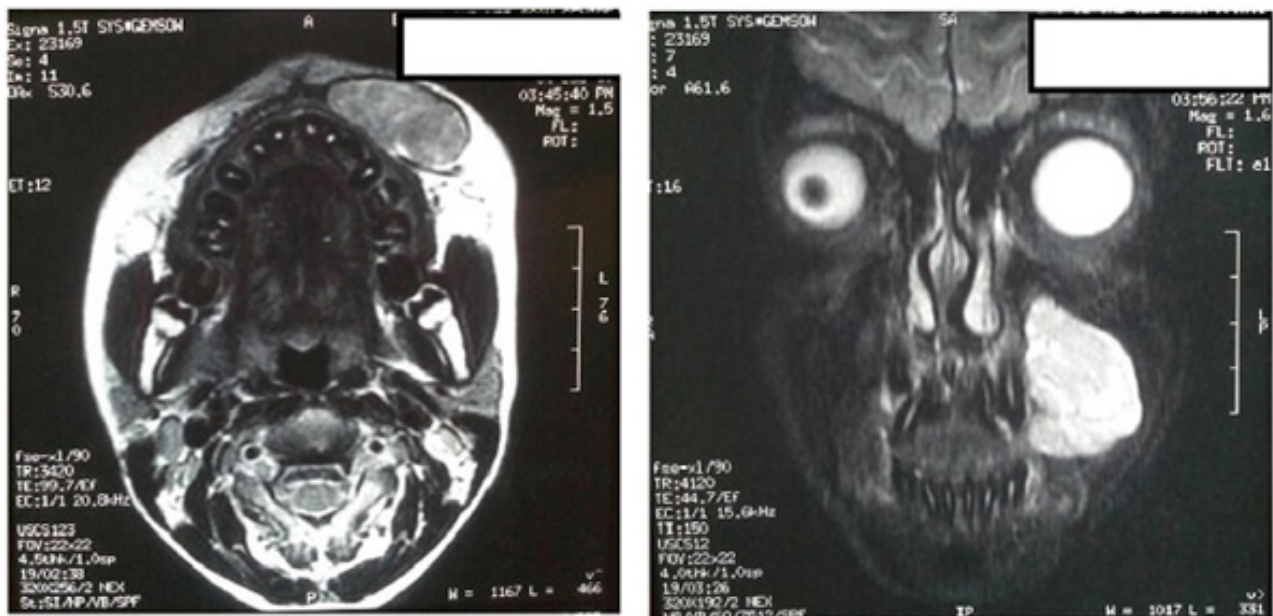


Fig. 2 Magnetic resonance imaging (axial and coronal views)

with neurilemmoma.

Verocay in 1910 first described a group of neurogenic tumours, termed as 'neurinomas'.⁴ In 1935, Stout proposed that these tumours arose from nerve sheath

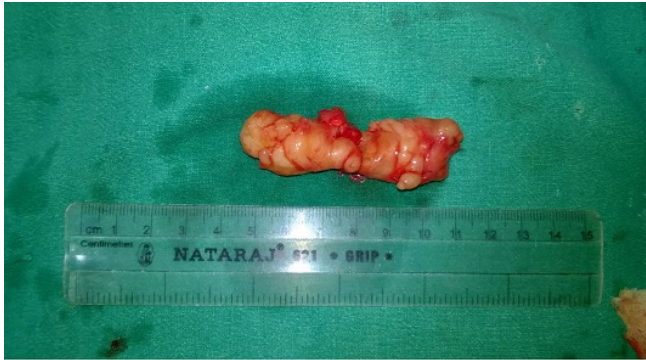

Fig. 3 Macroscopic view of the tumor

elements and they were termed 'neurilemmomas'.⁵ So any myelinated nerve fibre, which have Schwann cell can give rise to schwannoma (neurilemmoma). There is a predilection for the head, neck, and flexor surfaces of the upper and lower extremities.⁶ 25% of the extracranial neurilemmomas are reported in head and neck region but only 1% in intra-oral region.² Clinically, intraoral

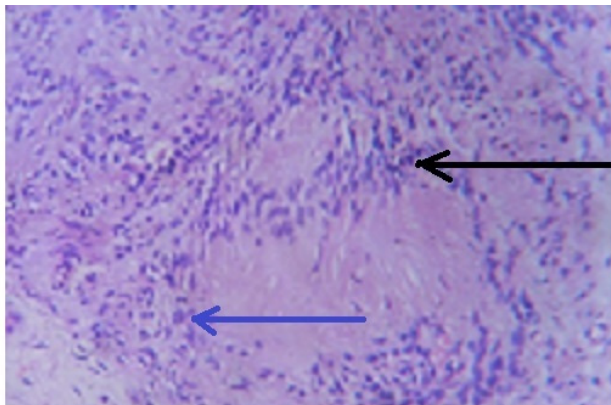


Fig. 4 Histopathology showing Antoni A (Black arrow) and Antoni B (Blue arrow) areas

schwannoma can be of two types—an encapsulated or non-capsulated lesion. But histologically, there are five varieties—common, plexiform, cellular, epithelioid, and ancient schwannomas.^{7,8} Among the

intra oral sites affected by neurilemmomas, tongue is the most common.^{3,9} Cheek is much rare site of this type of tumour. Gallo et al. analyzed 157 cases found in literature, where 45.2% of the cases involved the

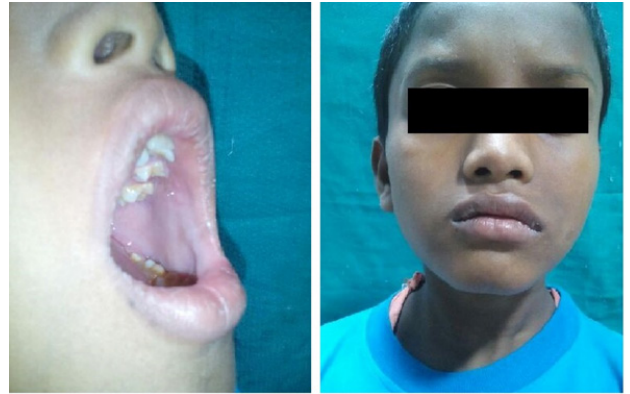

Fig. 5. Clinical Photograph of the patient after 15 days

tongue and only 13.3% involved the cheek.¹⁰ Due to rarity of the cases of intraoral neurilemmoma, there is no epidemiological data regarding it. Sanchis et al. described 12 cases of intraoral neurilemmoma, where the mean age was 29.5 ± 12.1 years and minimum age was 16 years with equal gender distribution.¹¹

The present case is much younger than most of the reported cases. Most of the cases were presented with only painless swelling^{3,11,12} as the present case. Nakayama et al. reported a maximum diameter of lesion to be 55 mm in a female patient,¹³ Dayan et al. reported ancient schwannoma with a maximum diameter of 31 mm.¹⁴ Sanchis et al. in their series reported 12 cases with maximum size of 4 cm.¹¹ The present case was much larger than most of the reported cases of intraoral neurilemmoma.

There are no specific symptoms or signs suggestive of this type of neoplasm. Fine needle aspiration cytology (FNAC) often inconclusive.^{11,15} Dey et al. in their study concluded that, though FNAC is a very useful diagnostic tool in cases of neck masses but in cases of tumors of neurogenic origin it is often have a low accuracy.¹⁶ FNAC often missed the diagnosis of intra oral neurilemmoma and mostly reported as pleomorphic adenoma.¹³ The same had occurred in the present case.

The present reported case is unique in some aspects. It

a case of intra oral neurilemmomas in a patient of much younger age than other reported cases whereas the size is much bigger than other reported cases in English literature till date. A diagnostic dilemma was there due to FNAC report as pleomorphic adenoma but the histopathological pattern with presence of Antoni A and B areas and Verocay body confirmed the diagnosis. The patient was successfully treated with surgical excision without any recurrence after one year of follow up.

References

1. Adhikary B K, Dutta S, Das Biswas K, Das S, Ghosh S K. "Neurilemmoma of Sinonasal Region with Intracranial Extension: An Extremely Rare Entity". *Journal of Evolution of Medical and Dental Sciences* 2015; 4(16):2817-22, doi: 10.14260/jemds/2015/408
2. Jadwani S, Bansod S, Mishra B. Intraoral Schwannoma in Retromolar Region. *Journal of Maxillofacial & Oral Surgery* 2012;11(4):491-4. doi:10.1007/s12663-010-0100-1.
3. Rahpeyma A, Jafarian AH, Khajeh Ahmadi S, Sarabadani J. A Schwannoma of the Soft Palate in a Child: Histological and Immunohistochemical Features and Surgical Method. *Iranian Journal of Otorhinolaryngology* 2012;24(67):95-9.
4. Khanna, S.C.Gupta and P.A. Singh. Schwannoma of Maxillary Sinus. *Indian Journal of Otolaryngology and Head and Neck Surgery* 2003; 55(2): 132-5.
5. Stout AP. The peripheral manifestations of the specific nerve sheath tumour (neurilemmoma). *Am J Cancer* 1935; 24: 751-79. Cited in Prakash S. B, Nishan, Geetha. Sinonasal Schwannoma: a rare cause of nasal obstruction: A case report. *Journal of Evolution of Medical and Dental Sciences* 2014; 3(14): 3048-52.
6. HS Fung, PWY Lam, TK Tsang, WK Wong, CW Siu, CM Chan, KW Tang and YL Cheung. Nasal Neurilemmoma in a Patient with Neurofibromatosis. *Journal of Hong Kong College of Radiologists* 2008; 11: 122-5.
7. C.-Y. Chen, W.-C. Wang, C.-H. Chen, Y.-K. Chen, and L.-M. Lin. Ancient schwannoma of the mouth floor—a case report and review. *Oral Oncology Extra* 2006; 42(8): 281–5.
8. K. Subhashraj, S. Balanand, and S. Pajaniammalle. Ancient schwannoma arising from mental nerve. A case report and review. *Medicina Oral, Patologia Oral y Cirugia Bucal*. 2009; 14(1): E12-E14. Article ID 1111111750
9. Jornet PL, Fenoll AB. Neurilemmoma of the tongue. *Oral Oncol Extra*. 2005; 41:154–157. doi: 10.1016/j.ooe.2005.03.007.
10. Gallo WJ, Moss M, Shapiro DN, Gaul JV. Neurilemmoma: review of the literature and report of five cases. *J Oral Surg*. 1977;35(5):235–6
11. Sanchis J M, Navarro C M, Bagán J V, Onofre M A, Murillo J, De-Andrade C R, Díaz J M and Pereira-Filho V A. Intraoral Schwannomas: Presentation of a series of 12 cases. *J Clin Exp Dent*. 2013 Oct; 5(4): e192–e196.
12. Lambade PN, Palve D, Lambade D. Schwannoma of the cheek: clinical case and literature review. *J Maxillofac Oral Surg*. 2015; 14(2):327-31. doi: 10.1007/s12663-013-0488-5.
13. H. Nakayama, R. Gobara, F. Shimamoto, and H. Kajihara. Ancient schwannoma of the oral floor and ventricular portion of the tongue: a case report and review of the literature. *Japanese Journal of Clinical Oncology*. 1996; 26(3)185–8 Cited in kuppusamy S K, Ramkumar S, Narasimhan M and Sargunam E A D. Intraoral Neurinoma of the Lingual Nerve: An Uncommon Tumor in Floor of the Mouth. *Case Reports in Dentistry*. Volume 2014, Article ID 385068,4 pages <http://dx.doi.org/10.1155/2014/385068>
14. Dayan D, Buchner A, Hirschberg A. Ancient neurilemmoma (schwannoma) of the oral cavity. *Journal of Cranio Maxillo-Facial Surgery* 1989; 17(6):280–2.
15. Sharma D K, Singh Sohal B, Parmar T L and Arora H. Schwannomas of Head and Neck and Review of Literature. *Indian J Otolaryngol Head Neck Surg*. 2012; 64(2):177–80.
16. Dey P, Mallik MK, Gupta SK, Yasishta RK. Role of fine needle aspiration cytology in the diagnosis of soft tissue tumours and tumour-like lesions. *Cytopathology* 2004; 15(1):32–7(s). doi: 10.1046/j.0956-5507.2003.00102.x