



# Post Covid-19 Mandibular Mucormycosis: A Rare and Deviant site of Presentation

<https://doi.org/10.47210/bjohns.2022.v30i3.814>

Ravishankar C,<sup>1</sup> Hemalatha B R,<sup>2</sup> Pruthvi Raj S,<sup>3</sup> Architha Menon P,<sup>3</sup> Garima Singh<sup>1</sup>

## ABSTRACT

### Introduction

Mandibular involvement in mucormycosis is rare, and only a few cases of post covid-19 mandibular mucormycosis have been reported to date.

### Materials and Methods

This is a retrospective descriptive case series study conducted at a tertiary care centre. We report the clinico-epidemiological profile and management of 5 cases of post covid mandibular mucormycosis. All patients received intravenous antifungals at the earliest and underwent surgical debridement of the infected bone.

### Results

4 patients were managed satisfactorily. 1 patient succumbed to the disease. Extent of debridement was based on the clinical, radiological and intraoperative assessment of the mandible.

### Conclusion

Mandibular mucormycosis is rare and early recognition of symptoms and treatment is imperative in reducing the spread of disease, decreasing the extent of resection and postoperative reconstruction.

### Keywords

Covid-19 Mucormycosis; Mandibular Mucormycosis; Mucormycosis

Mucormycosis (zygomycosis/phycomycosis) is a life-threatening infection commonly seen in patients with immunocompromised states like uncontrolled diabetes, hematological malignancies, and long term steroid therapy, neutropenia. It has diverse presentations, including rhino-orbit-cerebral, central nervous system, pulmonary, gastrointestinal tract, cutaneous, and vascular manifestations.<sup>1</sup> In a covid-19 patient interaction of several factors like immune dysregulation, steroid therapy, exacerbation of pre-existing diabetes may allow the mucoralean fungi to cause this disease.<sup>2</sup> As of the second week of July 2021, 40,845 cases of mucormycosis had been reported in India, and 31,344 (76.7%) of these were rhino cerebral.<sup>3</sup> Mucormycosis of the mandible is unusual and very few cases of post covid-19 mandibular mucor has been reported. We report 5 cases of covid-19 associated mucormycosis, their clinico-epidemiological profile and

management which would add to the literature of cases.

## Materials and methods

This is a retrospective descriptive case series. 5 cases of post-covid-19 mandibular mucormycosis were managed at a tertiary centre from May 2021 – September 2022.

1 - Department of Otorhinolaryngology, Bangalore Medical College and Research Institute, Bangalore

2 - Department of oral and maxillofacial surgery, Shri Atal Bihari Vajpayee Medical College & Research Institute, Bangalore

3 - Department of Otorhinolaryngology, Shri Atal Bihari Vajpayee Medical College & Research Institute, Bangalore

### Corresponding author:

Dr Architha Menon P

email: drarchithamenon@gmail.com

**Table I : Clinico-epidemiological profile and management of mandibular mucormycosis**

<b>CASES*</b>	<b>AGE / GENDER</b>	<b>CO-MORBIDITIES</b>	<b>CLINICAL FEATURES</b>	<b>SURGICAL PROCEDURE</b>	<b>OUTCOME (AFTER 6 MONTHS FOLLOW-UP)</b>	<b>RECURRENT</b>
<b>Case 1</b>	<b>44y / male</b>	<b>DM</b>	Toothache, loosening of teeth, swelling of gums	ESS + Alveolectomy (Intraoral approach)	<b>Recovery satisfactory</b>	<b>No</b>
<b>Case 2</b>	<b>38y / male</b>	<b>DM</b>	Toothache, loosening of teeth	ESS + Alveolectomy (Intraoral approach)	<b>Recovery satisfactory</b>	<b>No</b>
<b>Case 3</b>	<b>46y / male</b>	<b>DM, HTN</b>	Facial pain, headache, nasal discharge toothache, loosening of teeth, swelling of gums	ESS + partial maxillectomy +Total Mandibulectomy (Transcervical approach)	<b>Recovery satisfactory</b>	<b>No</b>
<b>Case 4</b>	<b>52y / male</b>	<b>DM</b>	Headache, nasal discharge, toothache, loosening of teeth, swelling of gums	ESS + Alveolectomy (Intraoral approach)	<b>Recovery satisfactory</b>	<b>Yes (After 8 months after primary surgery)</b>
<b>Case 5</b>	<b>62y / male</b>	<b>DM, HTN</b>	Toothache, loosening of teeth, swelling of gums	ESS +Total Mandibulectomy (Transcervical approach)	<b>Death</b>	<b>No</b>

\*All patients had history of covid-19 infection  
(DM – Diabetes Mellitus; HTN – Hypertension; ESS – Endoscopic Sinus Surgery)

Patients underwent complete ENT and dental examination along with blood investigations for surgery. The radiological investigation of choice was CEMRI (contrast

enhanced magnetic resonance imaging) of paranasal sinuses and CBCT (cone beam computerised tomography) & orthopantomogram (OPG) of mandible

which showed osteomyelitic changes. All the patients underwent extraction of affected tooth and the adjacent necrotic bone was sent for calcofluor potassium hydroxide mount (KOH) mount, which was positive for mucormycosis. The clinico-epidemiological profile and management of the patients is mentioned in Table 1. Management included early initiation of intravenous antifungals (liposomal amphotericin/posaconazole based on availability) and surgical debridement. All patients underwent endoscopic surgical debridement of the involved paranasal sinuses. Extent of debridement of mandible was based on the clinical, radiological extension of the disease and intraoperative assessment.

The affected bone was resected until healthy bone was encountered, as evidenced by bleeding edges. All patients received intravenous antifungals for 2 weeks in the postoperative period and oral posaconazole for 4-6 weeks.

## Results

Case 1, 2, 4 underwent alveolectomy (Fig.1). Case 3 and 5 underwent total mandibulectomy (Fig. 2 & 3) sparing the condyles on both sides and reconstruction with titanium plates and screws which were pre-bent to the contour of mandible. Case 3 also had involvement of maxilla and underwent partial maxillectomy. Patients were followed up postoperatively with diagnostic nasal endoscopy and routine dental examination for 6 months. Case 4 had recurrence of the disease of mandible after 8 months of primary surgery. He presented with swelling of gums,

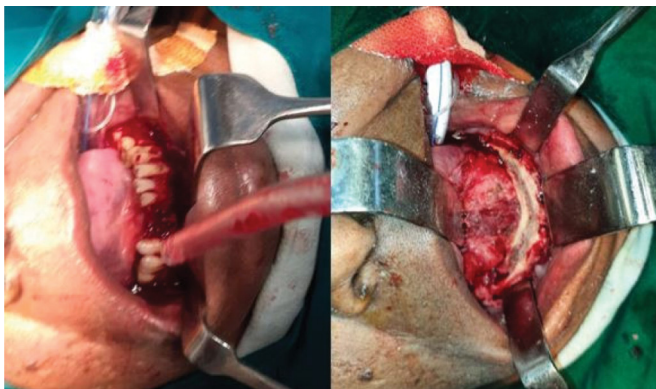


Fig. 1. Mandibular alveolectomy

discharging sinus and swelling of skin over mandible region and underwent hemimandibulectomy. Case 5 came back with frontal osteomyelitis after 5 months of primary surgery. He underwent bicoronal flap elevation and surgical debridement of frontal osteomyelitis. Patient expired 2 weeks after the surgery due to cardiac arrest.

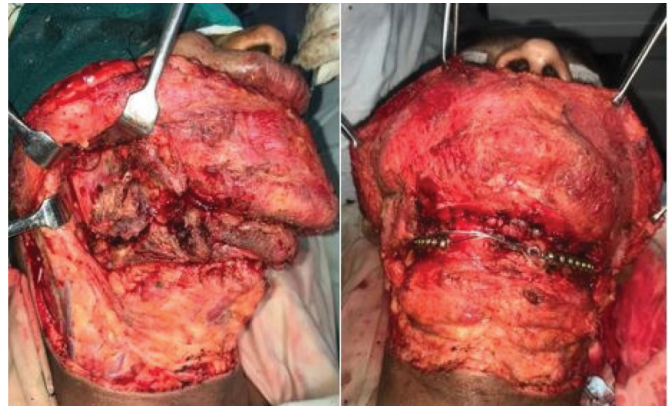

Fig. 2. Mandibulectomy and reconstruction with plates

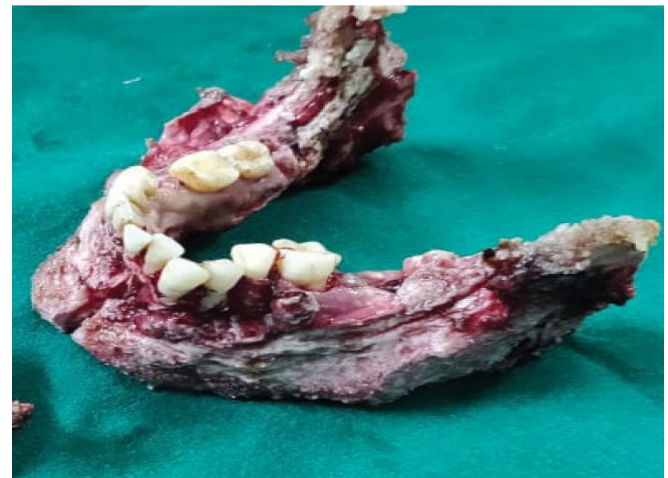

Fig. 3. Specimen of mandibulectomy

## Discussion

Mucormycosis is rare but lethal infection which mainly affects the immunocompromised individuals. In 2019 (pre-covid era), the prevalence of mucormycosis in India was estimated to be 140 cases per million population (which is about 80 times higher than in developed countries).<sup>4</sup> In a retrospective multicenter study conducted in India

between September to December 2020, it was found that prevalence of covid-19 associated mucormycosis (CAM) in hospitalised patients was 0.27% (2.1 fold rise in cases).<sup>5</sup>

Rhino-orbito-cerebral mucormycosis is the commonest form of mucormycosis. Uncontrolled diabetes mellitus is the most common risk factor for the development of mucormycosis. Involvement of mandible bone either as an isolated infection or along with paranasal sinuses is very rare and only few cases of post-covid mandibular mucor has been reported in the literature. We report 5 cases which had history covid-19 infection and presented to us with mandibular mucor along with paranasal sinuses involvement.

Management of mandibular mucormycosis included early initiation of antifungals therapy surgical debridement based on the extent of the disease. Reconstruction of bony defect after resection poses a challenge for the surgeon. 2 patients in our series underwent reconstruction with titanium plates and screws which were precontoured according to the contour of resected bone. 1 patient had recurrence of the disease after 8 months of primary surgery.

Saubhik Dasukil et al., reported 3 cases of post-covid mandibular mucormycosis. All cases underwent surgical debridement and extent of bone resection was based on radiological investigation and intraoperative assessment. 2 patients underwent reconstruction of resected bone with titanium plates and screws. They concluded a mountain of clinical disease may hide behind a mole hill of radiological evidence.<sup>6</sup>

Ambereen A et al., reported a case of covid associated mandibular mucormycosis wherein 39 year old male patient was diagnosed with osteomyelitis of face by radiological investigations. Patient underwent debridement and curettage. Mucormycosis involving mandible was diagnosed based on postoperative biopsy and special staining and he was further managed with complete course of appropriate antifungal therapy. Two months follow-up showed good wound healing and no signs of recurrence of infection.<sup>7</sup>

Radical surgical debridement of the affected bone along with systemic antifungals forms the mainstay of

treatment. Extent of resections may vary depending on the involvement on radiological scans. Intraoperative assessment and debridement till fresh bleeding is seen from healthy bony edges is necessary for the complete removal of the diseased bone. Involvement of patient in planning the surgery and reconstruction is of paramount importance as post surgery patient can have facial disfigurement, nutritional debility. Management by a multidisciplinary team is necessary in planning the treatment.

### Conclusion

Covid-19 associated mucormycosis is a locally aggressive angioinvasive infection. Early detection and management is important to improve the prognosis and reduce the morbidity. Mandibular mucormycosis is rare and early recognition of symptoms and treatment is imperative in reducing the spread of disease, decreasing the extent of resection and postoperative reconstruction.

### References

1. Eisenberg L, Wood T, Boles R. Mucormycosis. *Laryngoscope*. 1977 Mar;87(3):347-56. doi: 10.1288/00005537-197703000-00007. PMID: 839930
2. Moorthy A, Gaikwad R, Krishna S, Hegde R, Tripathi KK, Kale PG, Rao PS, Haldipur D, Bonanthaya K. SARS-CoV-2, Uncontrolled Diabetes and Corticosteroids-An Unholy Trinity in Invasive Fungal Infections of the Maxillofacial Region? A Retrospective, Multi-centric Analysis. *J Maxillofac Oral Surg*. 2021 Sep;20(3):418-425. doi: 10.1007/s12663-021-01532-1. Epub 2021 Mar 6. PMID: 33716414; PMCID: PMC7936599
3. Sharma NC. India reports 40,854 cases of black fungus so far [Internet]. *mint*. 2021 [cited 2022Dec3]. Available from: <https://www.livemint.com/news/india-records-over-40k-cases-of-mucormycosis-11624875874985.html>
4. Banerjee M, Pal R, Bhadada SK. Intercepting the deadly trinity of mucormycosis, diabetes and COVID-19 in India. *Postgrad Med J*. 2021 Jun 8;postgradmedj-2021-140537. doi: 10.1136/postgradmedj-2021-140537. Epub ahead of print. PMID: 34103372
5. Patel A, Agarwal R, Rudramurthy SM, Shevkani M, Xess I, Sharma R, et al. Multicenter Epidemiologic Study of Coronavirus Disease–Associated Mucormycosis, India. *Emerg Infect Dis*. 2021;27(9):2349-2359. <https://doi.org/10.3201/eid2709.210934>

6. Dasukil, S., Boyina, K.K., Sarkar, S. *et al.* Management of Covid Associated Mucormycosis of Mandible: A Mountain Beneath a Molehill—A Lesson Learnt. *Indian J Otolaryngol Head Neck Surg* 74 (Suppl 2), 3481–3484 (2022). <https://doi.org/10.1007/s12070-021-02925-x>
7. Ambereen A, Rahman SA, Rehman S, Zaidi K, Arif SH. Mandibular mucormycosis following SARS-CoV-2 infection - A case report and review of literature. *Clin Infect Pract.* 2021 Nov;12:100099. doi: 10.1016/j.clinpr.2021.100099. Epub 2021 Sep 20. PMID: 34568807; PMCID: PMC8450209.