

Cross Sectional Study on Thyroid Arteries with Clinical Correlations

<https://doi.org/10.47210/bjohns.2022.v30i3.875>

Ankita Saha,¹ Shantanu Nandy²

ABSTRACT

Introduction

Thyroid gland is a highly vascular endocrine gland. The aim of our study is to explore thyroid arteries to escape eventual iatrogenic complications.

Materials and Methods

Both sides of neck of total 60 adult embalmed cadavers were dissected in West Bengal (2020-2021).

Results

We found Superior Thyroid Arteries in 100% cases originating from External Carotid Artery in 77.5% cases, Carotid Bifurcation in 11.67% cases, Common Carotid Artery in 7.5% cases, as well as a common trunk with Lingual artery in 1.67% cases, Lingual and Facial arteries in 1.67% cases. Source of origin of Superior Thyroid Artery when compared with level of origin and between male and female cadavers, the result was found statistically significant ($p < 0.05$). Inferior Thyroid Artery was present in 90% cases and absent in 10% cases. Inferior Thyroid Artery originated from Thyrocervical Trunk in 92.5% cases, Common Carotid Artery in 1.67% cases, Subclavian Artery in 0.83% cases. Thyroidea Ima Artery was found in 3.33% cases arising from Arch of Aorta and Brachiocephalic Trunk.

Conclusion

Knowledge of thyroid arterial variations will help to prevent loss of patient life due to hemorrhage during surgery.

Keywords

Superior Thyroid Artery; Thyrocervical Trunk; Thyroidea Ima Artery

Thyroid surgeries are the most commonly performed neck surgeries and proper knowledge of blood supply of thyroid gland is important to prevent post-operative hematoma and preservation of laryngeal nerves. Arteries are the potential source of bleeding in thyroid related surgeries like total bilateral lobectomy, partial or subtotal lobectomy. The vascularity of thyroid gland can be as high as 5 ml/gm/min under conditions of extreme stimulation, equivalent to that of kidney as well as suprarenal gland.¹

The arterial supply of human thyroid gland consists of paired Superior and Inferior Thyroid Arteries as compared to the lower mammals and reptiles that have solitary Superior and Inferior Thyroid Arteries.² Sometimes the thyroid gland is also supplied by Thyroidea Ima Artery.

Superior Thyroid Artery (STA) is the first branch of External Carotid Artery (ECA) and arises from the anterior

surface of ECA just below the level of greater cornu of hyoid bone.³ It reaches the superior pole of thyroid gland. Inferior Thyroid Artery (ITA) originates from Thyrocervical Trunk (branch from 1st part of Subclavian artery).³ ITA loops upward and then turns medially just below the transverse process of C6 and descends to the lower pole of thyroid gland.

The thyroid vessels lie between the fibrous capsule and the loose fascial sheath.⁴ The Superior and Inferior

1 - Department of Anatomy, Sarat Chandra Chattopadhyay Government Medical College and Hospital, West Bengal
2 - Department of Anatomy, Bankura Sammilani Medical College, West Bengal

Corresponding author:

Dr Ankita Saha
email: ankitasaha91@gmail.com

Thyroid arteries pierce the pretracheal layer of deep cervical fascia and divide into glandular branches. STA supplies the antero-superior aspect of the thyroid gland and ITA supplies the postero-inferior aspect of the gland.

In 1772 Johann E. Neubauer first described Thyroidea Ima artery and since then it has been referred to as the thyroid artery of Neubauer.⁵ This artery, in some cases, referred as a fifth or an additional branch of supply to the thyroid gland; in others it is found to take the place of one or more of the ordinary thyroid arteries.⁶

Thyroidea Ima Artery (TIA) is a small, unpaired midline vessel, present in approximately 10% of population. It usually arises from the Brachiocephalic Trunk but it may arise from the Arch of Aorta or from the right Common Carotid, Subclavian or Internal Thoracic Arteries. This small vessel ascends on the anterior surface of trachea and supplies the isthmus of the thyroid gland.⁴

The aim of the present study is to explore the vascular anatomy of thyroid gland with respect to the variations in the origin, course of thyroid arteries and presence of any aberrant vessels. There are not so many studies on the West Bengal population regarding this particular subject. The data of this study will provide a guideline for otolaryngologist, interventional radiologists and neck surgeons in decreasing the liability of complication to a minimum in the patients during and after the surgery so that they can lead a better quality of life after the operation.

Materials and Methods

The present study is a cross-sectional study conducted on 60 adult embalmed cadavers (38 Male, 22 Female) from West Bengal population in the year 2020- 2021. The cadavers were embalmed through femoral arterial perfusion. Each cadaver was placed supine on the dissection table with neck extended. Skin incisions were given vertically from chin to sternum in the midline and transversely from chin to angle of mandible with the incision line extending posteriorly to mastoid process. Using blunt forceps Superior Thyroid Artery was traced from its origin to the upper pole of the lateral lobe of the thyroid gland. Inferior Thyroid Artery supplying the lower pole

of thyroid gland was identified and its origin was traced backward. Presence of any other vessel like Thyroidea Ima Artery was also noted. The data obtained was tabulated item wise by using appropriate charts and analyzed using appropriate statistical methods.

Results

On dissection of both sides of neck of each embalmed cadaver we found presence of 100% Superior Thyroid Arteries, 90% Inferior Thyroid Arteries and 3.33% Thyroidea Ima Arteries among 60 cadavers. Total number of vessels supplying thyroid gland ranged from 3 to 5. In majority of cadavers (86.67%) four vessels supplied the gland, followed by presence of three vessels in 10% cases and five vessels were found in only 3.33% cases under study.

The site of origin of STA was evaluated as it arose from External Carotid Artery in 77.5% cases, from Carotid Bifurcation in 11.67% cases, Common Carotid Artery in 7.5% cases, as well as a common trunk with Lingual artery in 1.67% cases and common trunk with Lingual and Facial arteries in 1.67% cases. Origin of STA as common trunk is shown in Figure 1.

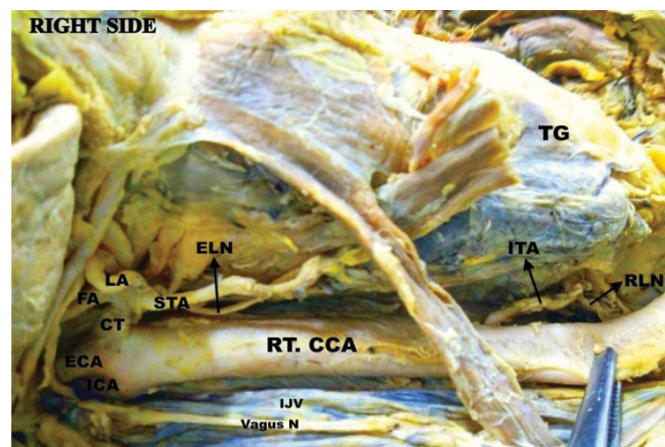


Fig. 1. Right side of neck showing Superior Thyroid Artery arising as common trunk with Lingual and Facial arteries from External Carotid Artery. (TG- Thyroid gland, CT- Common Trunk, FA- Facial Artery, LA- Lingual Artery, ELN- External Laryngeal Nerve)

Similarly the site of origin of ITA was found mainly from Thyrocervical Trunk (TCT) in 92.5% cases, from Common Carotid Artery (CCA) in 1.67% cases and also from Subclavian Artery directly in 0.83% cases. Absence of ITA was noted in 6 cases (3.33% on right side and 6.67% on left side). Direct origin of ITA from Subclavian artery is shown in Figure 2.

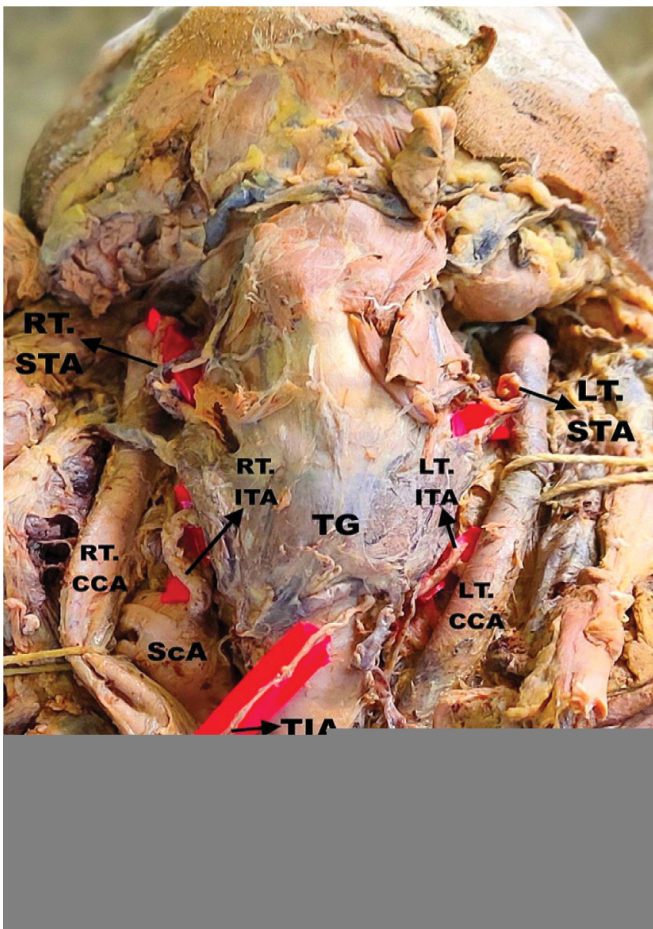


Fig. 2. Front of neck showing bilateral arterial variations. Rt. STA originated from ECA, Lt. STA from Lt. CCA. Rt. ITA arose directly from Subclavian artery (ScA) and Lt. ITA from Thyrocervical Trunk. Thyroidea Ima Artery found to be arising from Brachiocephalic trunk (BCT).

Total number of glandular branches arising from STA was two in 85% cases, three in 15% cases and arising from ITA was one in 7.5% cases, two in 92.5% cases.

The level of origin of STA was compared among

cadavers in relation to upper border of thyroid cartilage (UBTC). On right side we found STA originating most commonly from UBTC in 85% cases, followed by above the UBTC in 8.33% cases and in 6.67% cases below the level of UBTC. On left side level of origin of STA was found most commonly at the level of UBTC in 70% cases, followed by above the level of UBTC in 21.67% cases and below the level in only 8.33% cases.

Level of origin of STA was compared to its source of origin. Superior Thyroid Arteries originating from ECA was found most commonly at the level of UBTC in 65.83% cases, above UBTC in 11.67% cases and none was found below the level of UBTC. STAs originating from Common Carotid Artery (CCA) were found mostly below the level of thyroid cartilage upper order in 5.83% cases and at the level of UBTC in 1.67% cases. STAs originating from CCA Bifurcation were found at the level of UBTC in 10% cases and below UBTC in 1.67% cases. STA arising as a common trunk with Lingual artery as well as with both Lingual and Facial arteries were found above the level of UBTC in 3.33% cases.

Level of origin of STA was also compared between male and female genders. Among both sexes STA originated most commonly at UBTC. Origin of STA above UBTC was found more commonly among male cadavers (11.67%) than female cadavers (3.33%). Origin of STA below the level of UBTC was slightly more among female cadavers (5.83%) than male cadavers (1.67%).

In both cases when source of origin of STA was compared with level of origin and also between genders, the result was found statistically significant ($p < 0.05$).

Presence of Thyroidea Ima Artery was detected in only two cases. Both were found in male cadavers arising from Arch of Aorta in 1.67% cases and from Brachiocephalic Trunk (Figure 2) in 1.67% cases.

Discussion

The vascular architecture of thyroid gland is a complex and challenging area. Proper knowledge of thyroid arteries will help in their identification and ligation during surgery to have a bloodless field. SETA (Selective Embolization of Thyroid Arteries) is now the new method of treatment

of thyroid diseases and anaplastic thyroid carcinoma for which surgeons must be aware of normal and possible variations in thyroid vessels.⁷

Bergman et al.⁸ reported that Superior Thyroid Artery is generally considered to be present in 100% of cases. In our study also we found presence of STA to be 100%.

Absence of STA has been reported in the studies of Rimpi Gupta et al.⁹ and Morigyl et al.¹⁰

Sophia Anagnostopoulou et al.¹¹ studied variations in origin of STA in 68 formalin-embalmed adult cadavers and classified it into types A, B, C.

Type A: The STA originates from the CCA.

Type B: The STA arises (alone or as a common trunk) from the ECA.

- Subtype B1: The STA arises as a distinct ECA branch.
- Subtype B2: The STA arises from the ECA as a common trunk with lingual artery.
- Subtype B3: The STA arises from the ECA as a common trunk with facial and lingual arteries.

Type C: The STA arises from the CCA Bifurcation.

Based on the classification of Sophia Anagnostopoulou et al.¹¹, in our study we found Type A in 7.5% cases, Type B1 in 77.5% cases, Type B2 in 1.67% cases, Type B3 in 1.67% cases and Type C in 11.67% cases.

Vazquez et al.¹² also classified origin of STA from carotid arterial tree into four types:-

Type I – STA arising at the level of Carotid Bifurcation.

Type II- STA arising from Common Carotid Artery.

Type III- STA arising from External Carotid Artery.

Type IV- When STA arose as a common trunk with one of the other branches of the carotid arterial tree. It is subdivided into following types:

- Subtype IV a- STA arose with lingual artery to form common thyrolingual trunk (TLT)
- Subtype IV b- STA arose in common with the lingual and facial arteries, forming a common thyrolingual facial trunk (TLFT)

Vazquez et al.¹² found in his study Type I in 49%, Type II in 27%, Type III in 23%, Type IV a in 0.6% and Type IV b in 0.4% cases.

Based on the above classification, in the present study we found 11.67 % belonged to Type I, 7.5% belong to Type II, 77.5% belong to Type III, 1.67 % belonged to Type IV a and 1.67 % belonged to Type IV b.

Rajamadhava et al.¹³ is the only author who found STA arising from External Carotid Artery in 100% cases. Findings of various authors regarding origin of STA are compared in Table I.

In our study the level of the origin of the STA was also evaluated. STA arose most commonly at the level of upper border of thyroid cartilage (UBTC) in 77.5% cases (right 85%, left 70%), followed by above the level of UBTC in 15 % cases (right 8.33%, left 21.67%) and in few cadavers below the level of UBTC in 7.5% cases (right 6.67%, left 8.33%). Our finding was compared with other author studies in Table II.

The findings of present study regarding the level of origin of STA don't match with any other author. Previous studies reported origin of STA most commonly above the level of UBTC. But in our study we found STA arising most commonly at the level of UBTC.

In our study comparison was made between male and female cadavers based on level of origin of STA and the result was found statistically significant ($p < 0.05$). On both sides of necks of cadavers the origin level was almost similar. In both male and female cadavers STA originated predominantly at the level of UBTC.

Origin of STA above the level of UBTC was found more common in male cadavers, whereas in female cadavers STA originated more commonly from below the level of UBTC. This does not tally with the studies of Dessie et al.²¹, Ozgur et al.²² as they found no statistically significant relation between the origin of STA and the sex and side of cadavers. Level of origin of STA was also compared to source of origin and the result was found statistically significant ($p < 0.05$).

Table I : Comparative study based on origin of STA

AUTHOR	YEAR	ECA (%)	CCA (%)	CCA BIFURCATION (%)	OTHER ORIGIN (%)
Adachi B ¹⁴	1928	61	13	27	
Hayashi et al. ¹⁵	2005	70	30	–	
Teresa Va'zquez et al. ¹²	2009	23	26.6	49	0.6 (TLT), 0.4 (TLFT)
Kanta Ray et al. ¹⁶	2009	76.5	8.8	14.7	
Anita T et al. ¹⁷	2011	59	21	19	1 (TLFT)
Kevin W.Ontegi. ¹⁸	2012	80.4	10.9	2.2	6.5 (TLFT)
Magoma G. et al. ¹⁹	2012	74.4	25.6	–	
Gupta et al. ²⁰	2014	72	4	20	4 (ICA)
Dessie et al. ²¹	2018	44.2	26.7	27.9	1.2 (TLT)
Present study	2020-21	77.5	7.5	11.67	1.67 (TLFT), 1.67 (TLT)

Table II : Comparison based on level of origin of STA in relation to Upper Border of Thyroid Cartilage (UBTC)

AUTHOR	YEAR	ABOVE UBTC (%)	AT UBTC (%)	BELOW UBTC(%)
Ozgur et al. ²²	2009	60	17.5	22.5
Anitha T et al. ¹⁷	2011	16	23	61
Abhijeet Joshi et al. ²³	2014	86.36	13.64	–
Pushpalatha et al. ²⁴	2015	48	36	6
Veena Vidya et al. ²⁵	2017	73.75	16.25	10
Dessie et al. ²¹	2018	51.2	44.7	4.1
Sreedharan et al. ²⁶	2018	96.66	1.66	1.66
Amanuel T. et al. ²⁷	2019	68.75	–	31.25
Present Study	2020-21	15	77.5	7.5

Study of Vazquez et al.¹² showed STA arose from Common Carotid Artery with a higher frequency in the left side ($p < 0.05$). But in our study we found STA arising from CCA most commonly on right side and CCA bifurcation most commonly on left side.

Regarding Inferior Thyroid Artery (ITA), there are more studies on its relation to Recurrent Laryngeal Nerve than its source of origin and branching pattern.

In our study we have focused on source of origin of

ITA and its glandular branches to thyroid gland. We found ITA arising most commonly from Thyrocervical Trunk (TCT) in 92.5%, followed by Common Carotid Artery in 1.67% cases, in only one case it was found to arise directly from Subclavian Artery (0.83%) and ITA was found to be absent in 5% cases. Our findings are compared with other authors in Table III.

The oldest study on source of origin of ITA was done on 1844 by Quain R.⁶ He reported in his study that ITA

Table III : Comparison based on origin of Inferior Thyroid Artery

AUTHOR	YEAR	POPULATION	ORIGIN OF ITA			
			TCT	CCA		
Adachi et al. ¹⁴	1928	Japanese	94.5%	–	4.7%	0.7%
Rohlich et al. ²⁸	1940	Polish	92.5%	–	7%	0.5%
Daseler and Anson ²⁹	1959	Polish	81.2%	0.5%	17.7%	0.6%
Toni et al. ³⁰	2005	Italians	94.8%	–	5.2%	–
Magoma G et al. ¹⁹	2012	Kenyans	87.5%	–	12.5%	–
Roshan S et al. ³¹	2015	Indians	98%	–	2%	–
Present Study	2020-21	Indians	92.5%	1.67%	0.83%	–

originates from Thyroid axis. The Thyroid axis mentioned in his study is presently known as Thyrocervical Trunk. He found ITA arising as an independent branch in twenty-nine cases, out of which in one case it arose from the Common Carotid Artery, in another case from the vertebral artery and in rest of the cases it was derived from the Thyroid axis arising from Subclavian artery.

Daseler EH et al.²⁹ found ITA arising most commonly from TCT and also reported anomalous origin of the ITA from the vertebral artery and directly from the Subclavian artery. He also noted ITA to be absent in 6% of the cases in his study. Our study findings are quite similar to his study except that we found ITA arising from CCA in two cases and none arose from vertebral artery.

Kanta Ray Rimi et al.¹⁶ found ITA arising most commonly from Thyrocervical Trunk, on right 87% and left 90.2%, followed by Subclavian artery, right 13% and left 9.80%. In our study we found ITA arising most commonly from TCT on both sides of neck (right 95% and left 90%), from CCA on left side (3.33%) and Subclavian artery on right side (1.67%).

In our study we also found unilateral absence of ITA in two cases on right side (3.33%) and four cases on left side (6.67%). Absence of ITA has also been reported by Chandrakala et al.³² (3.75% on right, 6.25% on left) and Gandhi O.P.³³ (2% on right, 8% on left).

Hollinshead W H.³⁴ in his book of Anatomy for Surgeons mentioned that incidence of absence of ITA ranges from 0.2% to 5.9%. In the absence of ITA, it is usually replaced by a branch from the Superior Thyroid Artery of same side or Inferior Thyroid Artery of opposite side; less frequently its place is taken by Thyroid Ima Artery. Rarely doubling of ITA may also occur.

Nikha Bhardwaj et al.³⁵ reported bilateral absence of ITA in 0.01% cases and in this variation, thyroid gland was supplied by anastomosing branches of Superior Thyroid Artery. Morigyl et al.¹⁰, Yilmaz E et al.³⁶ reported bilateral absence of ITA and replacement by Thyroidea Ima Artery. In all previous studies absence of ITA was replaced by any other vessels supplying thyroid gland. But in our study in only one case Thyroidea Ima Artery replaced the Left ITA and in rest cases of absence of ITA it remained un-replaced.

Sinmons J et al.³⁷ reported that variant origins of ITA are usually accompanied by other anomalies of Subclavian artery, warranting care during dissection of neck. In our study in one male cadaver we found right ITA arising directly from Subclavian artery instead of its Thyrocervical trunk. On exploration of Subclavian artery we found other variations also like presence of Transverse Cervical Artery.

There are limited researches on the prevalence and

clinical impacts of Thyroidea Ima Artery (TIA). It is a very rare vessel and its presence can't be predicted. There is high chance of injury of TIA during thyroid surgeries, surgical procedures involving the suprasternal fossa particularly the tracheostomy, mediastinography or mediastinoscopy etc. due to its location anterior to trachea. Emergency and surgical considerations of TIA are critical in hemostasis and preventing hemorrhage into the mediastinal cavity.

In our study we also found presence of Thyroidea Ima Artery (TIA) in 3.33% cases. It was a midline vessel originating from Arch of Aorta in one case (1.67%) and Brachiocephalic Trunk in another case (1.67%).

Kanta Ray et al.¹⁶ found presence of TIA in 10.52% cases, arising most commonly from Brachiocephalic trunk, followed by Arch of Aorta and right Common Carotid Artery. Chin J et al.³⁸ found TIA in 1.06 % cases arising from left Common Carotid Artery.

It is interesting to note that many authors have tried to explore the anatomy and vascular supply of thyroid gland and very few have reported similar results and percentages. This may be due to differences in races, sample size or geographical distribution.

Conclusion

Our study shows that there is wide possibility of variations in the arterial supply of thyroid gland. The life threatening complication of Thyroid surgery is hemorrhage and hematoma. Proper knowledge of thyroid arteries can help to prevent their iatrogenic injury, preservation of laryngeal nerves and most importantly save the life of a patient while performing various neck surgeries, thyroidectomy, carotid angiographies, emergency cricothyroidotomy, tracheostomy, catheterization, reconstruction of aneurysm etc. Pre-operative ultrasound examination is helpful to detect arterial variations. Our study also revealed significant relation ($p < 0.05$) of level of origin of Superior Thyroid Artery when compared between male and female cadavers and when compared with source of origin. This information will be beneficial to surgeons while operating as ligation of vessels is not always sufficient to stop bleeding.

Abbreviations :

STA- Superior Thyroid Artery
 ITA- Inferior Thyroid Artery
 TIA- Thyroidea Ima Artery
 TCT- Thyrocervical Trunk
 UBTC- Upper Border of Thyroid Cartilage
 ECA- External Carotid Artery
 ICA- Internal Carotid Artery
 TLFT- Thyrolingual Facial Trunk

References

1. Vijay Laxmi, Kulbir Kaur, Palak Chhabra. Superior Thyroid Artery: its Origin, Length, Relations and Branches. *International Annals of Medicine*. 2017; 1(4)
2. Livini F. Studio morfologico dell'arterie tiroidee. *Sperimentale* 1900; 54:42-129
3. Standring S. *Gray's Anatomy. The Anatomical Basis of Clinical Practice*. 41st Ed., 2016, Elsevier Limited; p 453- 461
4. Moore KL, Dalley AF. *Clinical oriented Anatomy*. 6th ed, Lippincott Williams –Wilkins 2010; Neck, p1018-1020
5. Neubauer J. De arteria thyroidea ima rariare arteriae innominate ramo. 1786:291-96
6. Quain R. *Anatomy of the arteries of the human bodies, with its applications to pathology and operative surgery*. London, 1844, P-171
7. Tazbir J, Dedecjus M, Kaurzel Z, et al. Selective embolization of thyroid arteries (SETA) as a palliative treatment of inoperable anaplastic thyroid carcinoma (ATC). *Neuro Endocrinol Lett*. 2005; 26:401–6
8. Bergman RA, Thomson SA, Afifi AK, Saadeh FA. *Compendium of human anatomic variation. Cardiovascular System*. Baltimore: Urban and Schwarzenberg, 1988:64
9. Rimpi Gupta and Rajan Kumar Singla, Multiple Anomalies in Thyroid Gland. *Journal of Clinical and Diagnostic Research*. 2011 December, Vol-5(8): 1634-1636
10. Morrighyl B, Sturm W, Absence of three regular thyroid arteries replaced by an unusual lowest thyroid artery: A case report. *Surg Radiol Anat* 1996; 18:147-150
11. Anagnostopoulou S, Mavridis I. Emerging patterns of the human superior thyroid artery and review of its clinical anatomy. *Surg Radiol Anat* 2014; 36:33-8
12. Teresa Va'zquez, Rosana Cobiella, Eva Maranillo, Francisco Jose, Valderrama, Stephen McHanwell, Ian Parkin, Jose Ramon

- Sanudo, Anatomical Variations Of The Superior Thyroid and Superior Laryngeal Arteries. *Head Neck* 2009 Aug; 31(8):1078-85
13. Rajamadhava R, Kafeel Hussain A, Swayam Jothi S, Hemanth Kommuru, Sujatha N. Variations In The Course Of The Superior and Inferior Thyroid Arteries In Relation To the External and Recurrent Laryngeal Nerves. *IOSR Journal of Dental and Medical Sciences* 2015
 14. Adachi B (1928) *DAS Arteriensystem der JAPANER*, vol. 1 Kenkyusha, Kyoto, pp 58-62
 15. Hayashi N, Hori E, Ohtani Y, Ohtani O, Kuwayama N, Endo S (2005) Surgical anatomy of the cervical carotid artery for carotid endarterectomy. *Neurol Med Chir* 45(1):25-29
 16. Kanta Ray Rimi, Shami Ara, MotaharHassain, KMshefyetullah, Humaria Naushaba, BK Bose; Postmortern study of thyroid arteries in Bangladeshi people. *Bangladesh Journal of Anatomy* 2009, 7, 26-33
 17. Anitha T, Dombé D, Asha K, Kalbande S. Clinically relevant variations of the superior thyroid artery: An anatomic guide for neck surgeries. *Int J Pharm Biomed Sci.* 2011, 2(2); p 51-54
 18. Ongeti KW, Ogeng'o JA. Variant origin of the superior thyroid artery in a Kenyan population. *Clin Anat.* 2012; 25:198-202
 19. Magoma G, H. Saidi, Kaisha WO. Origin of thyroid arteries in a Kenyan population. *The ANNALS of AFRICAN SURGERY.* January 2012 • Volume 9; pp-50-54
 20. Gupta P, Bhalla AS, Thulkar S, Kumar A, Mohanti BK, Thakar A, Sharma A. Variations in superior thyroid artery: a selective angiographic study. *Indian J Radiol Imaging.* 2014;24:66-71
 21. Dessie MA (2018) Variations of the origin of superior thyroid artery and its relationship with the external branch of superior laryngeal nerve. *PLOS ONE* 13(5): e0197075
 22. Ozgur Z, Govsa F, Celik S, Ozgur T. Clinically relevant variation of the superior thyroid artery : an anatomic guide for surgical neck dissection. *Surg Radio Anat* 2009, 31,151-159
 23. Abhijeet Joshi, Sumit Gupta, V H Vaniya Anatomical variation in the origin of superior thyroid artery and its relation with external laryngeal nerve. *National journal of medical research.* 2014; 4(2):138- 41
 24. Pushpalatha M, Vidhya K. S. Study on variations in origin of superior thyroid artery. *J Evid Based Med Healthc.* 2015; 2(59):8968 – 8970
 25. Veena Vidya Shankar, Komala N, Shailaja Shetty. A Cross-Sectional Study of Superior Thyroid Artery In Human Cadavers. *Int J Anat Res* 2017; 5(4.3):4751- 4755
 26. Sreedharan R, Krishna L, Shetty A. Origin of superior thyroid artery: under the surgeon's knife. *J. vasc. bras.* vol.17 no.4 Porto Alegre Oct. /Dec. 2018
 27. Amanuel T. Tsegay, Tesfamichael Berhe, Fasika Amdeslase, Hintsanesh Hayelom. Variations on Arterial supply of Thyroid gland and its clinical significance in selected universities of North Ethiopia. *Int J Anat Res* 2019; 7(3.2):6830-6834
 28. Rohlich K, *Uber den Trunkus thyroecervicalis des Menschen*, *Anat Anz*, 1940; 10(12): 129 – 148
 29. Daseler E, Anson B: Surgical anatomy of the subclavian artery and its branches. *Surg Gynecol Obstet.* 1959; 108: 149-174
 30. Toni R, Casaa D, Castorina S, Roti E, Cedad G, Valenti G. A Meta-Analysis Of Inferior Thyroid artery Variations In Different Human Ethnic Groups And Their Clinical Implications. *Ann Anat* 2005; 187: 371-385
 31. Roshan S, Nivedita Pandey, Varsha Bhivate, Rahul P Kharate. Morphometric study of Inferior Thyroid Artery in cadavers. *Int J Anat Res* 2015; 3(4):1726-1731
 32. Chandrakala SP, Mamatha Y., Thejaswini K.O. Variation in the origin of inferior thyroid artery and relation of the artery with recurrent laryngeal nerve. *National Journal of clinical anatomy*, 2013. Vol-2, (1), page 11-15
 33. Gandhi OP. Inferior thyroid artery-its origin, course, relations, branches. *J Anat Soc India* 1971; 20:83
 34. Hollinshead WH. *Anatomy for Surgeons: The Head and Neck.* 1st ed. Vol. 1. Philadelphia, PA: Lippincott Williams and Wilkins; 1982
 35. Bhardwaj N, Joshi A. Bilateral absence of inferior thyroid artery: A rare variation. *Int J Med Sci Public Health* 2019; 8(5):401-403
 36. Yilmaz E, Celik HH, Durgun B, Atasever A and Ilgi S. Arteria thyroidea ima arising from the brachiocephalic trunk with bilateral absence of inferior thyroid arteries: a case report. *Surg Radiol Anat* (1993) ;15:197-199
 37. Simmons J, Doppman J, Norton J. Inferior thyroid artery arising from Common carotid artery with aberrant right Subclavian artery. *Cardiovascular Intervent Radiol*, 1987; 10: 150 – 152
 38. Chin J, Zhou Y, Wan PJ, Lomiguen CM. The prevalence of thyroid ima artery and its clinical significance. *Int J Otorhinolaryngol Head Neck Surg* 2019; 5: 845-9.